

Cataract Surgery in the Glaucoma Patient

Sandra Johnson
Editor

Cataract Surgery in the Glaucoma Patient

Editor
Sandra Johnson
University of Virginia School
of Medicine
Charlottesville, VA 22908
USA

ISBN 978-0-387-09407-6 e-ISBN 978-0-387-09408-3
DOI 10.1007/978-0-387-09408-3
Springer Dordrecht Heidelberg London New York

Library of Congress Control Number: 2009931581

© Springer Science+Business Media, LLC 2009

All rights reserved. This work may not be translated or copied in whole or in part without the written permission of the publisher (Springer Science+Business Media, LLC, 233 Spring Street, New York, NY 10013, USA), except for brief excerpts in connection with reviews or scholarly analysis. Use in connection with any form of information storage and retrieval, electronic adaptation, computer software, or by similar or dissimilar methodology now known or hereafter developed is forbidden.

The use in this publication of trade names, trademarks, service marks, and similar terms, even if they are not identified as such, is not to be taken as an expression of opinion as to whether or not they are subject to proprietary rights.

While the advice and information in this book are believed to be true and accurate at the date of going to press, neither the authors nor the editors nor the publisher can accept any legal responsibility for any errors or omissions that may be made. The publisher makes no warranty, express or implied, with respect to the material contained herein.

Cover illustration: Original cover photo courtesy of Pat Saine

Printed on acid-free paper

Springer is part of Springer Science+Business Media (www.springer.com)

Preface

Cataract surgery is one of the most frequently performed procedures in the United States, and cataracts are a leading cause of visual impairment in the world. Glaucoma is also a very common eye disease with an expected 3.3 million Americans afflicted with primary open angle glaucoma by 2020. It is also a leading cause of irreversible blindness worldwide. The coexistence of these two diseases is not uncommon, and how a cataract is approached can have an impact on the glaucoma status of a patient. After all, cataracts are rarely associated with permanent blindness as is glaucoma. Managing cataracts to the best advantage of the glaucoma should result in the best long-term visual outcomes for our patients with both diseases.

While detailed instruction on cataract surgery is reviewed in other texts, this book serves to focus on the management of cataract in the setting of glaucoma, using an evidence-based medicine approach. It is hoped to serve as a wonderful resource for ophthalmologists, residents, and glaucoma fellows.

Charlottesville, VA

Sandra M. Johnson, MD

Acknowledgments

I would like to acknowledge all the contributors of this book without whom it would not be published. The experience of our mentors and the contributors to our references, cited and uncited, helped provide us with our current insights. In addition, I thank the photographers who assisted the authors including those from Dartmouth Hitchcock Medical Center (Tom Monego and Pat Saine), Medical College of Georgia (Mike Stanley), and University of Virginia (Alan Lyon, Jared Watson, and Lloyd Situkali).

Sandra M. Johnson

Contents

Part I	Cataract Surgery	1
1	Approach to Cataract Surgery in Glaucoma Patients	3
	Graham A. Lee and Ivan Goldberg	
2	Anesthesia	17
	Marlene R. Moster and Augusto Azuara-Blanco	
3	Management of the Small Pupil	23
	Cynthia Mattox	
4	Small Incision Cataract Surgery and Glaucoma	35
	Brooks J. Poley, Richard L. Lindstrom, Thomas W. Samuelson, and Richard R. Schulze Jr.	
5	Elevated Intraocular Pressure After Cataract Surgery	51
	Parag A. Gokhale and Emory Patterson	
Part II	Combined Surgery	57
6	Combined Cataract and Trabeculectomy Surgery	59
	Sandra M. Johnson	
7	Managing Cataract and Glaucoma in the Developing World – Manual Small Incision Cataract Surgery (MSICS) Combined with Trabeculectomy	73
	Rengaraj Venkatesh, Rengappa Ramakrishnan, Ramasamy Krishnadas, Parthasarathy Sathyan, and Alan L. Robin	
8	Antimetabolite-Augmented Trabeculectomy Combined with Cataract Extraction for the Treatment of Cataract and Glaucoma	83
	Sumit Dhingra and Peng Tee Khaw	
9	Early Postoperative Bleb Maintenance	91
	Robert T. Chang and Donald L. Budenz	
10	Laser Suture Lysis and Releasable Sutures	105
	Anastasios Costarides and Prathima Neerukonda	
11	Cataract Surgery Combined with Glaucoma Drainage Devices	109
	Ramesh S. Ayyala and Brian J. Mikulla	
12	Choroidal Detachment Following Glaucoma Surgery	119
	Diego G. Espinosa-Heidmann	

13	Cataract Extraction Combined with Endoscopic Cyclophotocoagulation	129
	Steven D. Vold	
14	Approach to Cataract Extraction Combined with New Glaucoma Devices . .	135
	Diamond Y. Tam and Iqbal Ike K. Ahmed	
Part III	Glaucoma Conditions	159
15	Cataract Surgery in Patients with Exfoliation Syndrome	161
	Anastasios G.P. Konstas, Nikolaos G. Ziakas, Miguel A. Teus, Dimitrios G. Mikropoulos, and Vassilios P. Kozobolis	
16	Cataract Surgery in the Presence of a Functioning Trabeculectomy Bleb . .	177
	Hylton R. Mayer and James C. Tsai	
17	Cataract Extraction in Eyes with Prior GDD Implantation	187
	Ramesh Ayyala and Brian Mikulla	
18	Cataract Surgery in the Primary Angle-Closure Patient	189
	Jimmy S.M. Lai	
19	Nanophthalmos	197
	Carlos Gustavo Vasconcelos de Moraes and Remo Susanna Jr.	
20	Cataract Induced Glaucoma: Phacolytic/Phacomorphic	207
	Sandra M. Johnson	
21	Glaucoma Related to Pseudophakia	213
	Junping Li and Jason Much	
22	Cataract and Glaucoma in Retinopathy of Prematurity	221
	Anthony J. Anfusio and M. Edward Wilson	
23	Cataract Surgery in the Hypotonous Eye	227
	Devon Ghodasra and Sandra M. Johnson	
	Appendix: Index of Major Figures and Tables	233
	Index	239

Contributors

Iqbal Ike K. Ahmed, MD, FRCSC Department of Ophthalmology, University of Toronto, Toronto, ONT, Canada, ikeahmed@mac.com

Anthony J. Anfuso, MD University of West Virginia, Morgantown, WV, USA, tony.anfuso@gmail.com

Ramesh S. Ayyala, MD, FRCS, FRCOphth Department of Ophthalmology, Tulane University School of Medicine, New Orleans, LA, USA, rayyala@tulane.edu

Augusto Azuara-Blanco, MD, PhD, FRCS(Ed) Department of Ophthalmology, The Eye Clinic, University of Aberdeen, Foresterhill, Aberdeen, Scotland, aazblanco@aol.com

Donald L. Budenz, MD, MPH Department of Ophthalmology, Bascom Palmer Eye Institute, Miller School of Medicine, University of Miami, Miami, FL, USA, dbudenz@med.miami.edu

Robert T. Chang, MD Department of Ophthalmology, Bascom Palmer Eye Institute, Miller School of Medicine, University of Miami, Miami, FL, USA, viroptic@yahoo.com

Anastasios Costarides, MD, PhD Emory University School of Medicine, Emory Eye Center, Atlanta, GA, USA, acostar@emory.edu

Carlos Gustavo Vasconcelos de Moraes, M.D. Department of Ophthalmology, Glaucoma Associates of New York, New York Eye and Ear Infirmary, New York, NY, USA, gustavousp@gmail.com

Sumit Dhingra, MBBCh, MA, MRCOphth Department of Ocular Repair and Regeneration BiologyNIHR Biomedical Research Centre, UCL Institute of Ophthalmology and Moorfields Eye Hospital, London, UK, drsumitdhingra@gmail.com

Diego G. Espinosa-Heidmann, MD Duke University Eye Center, Durham, NC, USA, diego.espinosa-heidmann@duke.edu

Devon Ghodasra, BS Medical College of Georgia, School of Medicine, Augusta, GA, USA, devonghodasra@gmail.com

Parag A. Gokhale, MD Department of Ophthalmology, Virginia Mason Medical Center, Seattle, WA, USA, ophpag@vmmc.org

Ivan Goldberg, MBBS, FRANZCO, FRACS Department of Ophthalmology, Sydney Eye Hospital, University of Sydney, Sydney, NSW, Australia, eyegoldberg@gmail.com

Sandra M. Johnson Department of Ophthalmology, Glaucoma Service, University of Virginia School of Medicine, Charlottesville, VA, USA, catglaubk@gmail.com

Peng Tee Khaw, PhD, FRCP, FRCS, FRCOphth, FIBiol, FRCPath, FmedSci Department of Ocular Repair and Regeneration BiologyNIHR Biomedical Research Centre, UCL Institute of Ophthalmology and Moorfields Eye Hospital, London, UK, p.khaw@ucl.ac.uk

Anastasios G.P. Konstas, MD, PhD 1st University Department of Ophthalmology, Head of the Glaucoma Unit, AHEPA Hospital, Thessaloniki, Greece, konstas@med.auth.gr

Vassilios P. Kozobolis, MD, PhD Department of Ophthalmology, University Hospital of Alexandroupolis, Medical School, Dragana, Alexandroupolis, Alexandroupoli, Greece, vkozobolis@yahoo.gr

Ramasamy Krishnadas, DO, DNB Aravind Eye Hospital and Postgraduate Institute of Ophthalmology, Madurai, TN, India, krishnadas@aravind.org

Jimmy S.M. Lai, FRCSOphth, FRCSEd, M.Med (Ophthalmology), M.D., L.L.B. Queen Mary Hospital, Eye Institute and Research Center for Heart Brain and Healthy Ageing, The University of Hong Kong, Cyberport, Hong Kong, China, laism@hku.hk

Graham A. Lee, MD, MBBS, FRANZCO Department of Ophthalmology, Royal Brisbane Hospital, Brisbane, QLD, Australia, eye@cityeye.com.au

Junping Li, MD, PhD Clinical Ophthalmology, University of Virginia, Chief of Ophthalmology, Salem Veterans Affairs Medical Center, Salem, VA, USA, junping.li2@va.gov

Richard L. Lindstrom, MD Department of Ophthalmology, University of Minnesota, Minnesota Eye Consultants, PA, Bloomington, MN, USA, rlindstrom@mneye.com

Cynthia Mattox, MD Department of Ophthalmology, New England Eye Center, Tufts University School of Medicine, Boston, MA, USA, cmattox@tuftsmedicalcenter.org

Hylton R. Mayer, MD Department of Ophthalmology, Yale University School of Medicine, New Haven, CT, USA, hylton.mayer@yale.edu

Dimitrios G. Mikropoulos, MD AHEPA Hospital, Thessaloniki, Greece, mikropou@med.auth.gr

Brian J. Mikulla, BS, MBA Department of Ophthalmology, Tulane University School of Medicine, New Orleans, LA, USA, bmikulla@tulane.edu

Marlene R. Moster, MD Department of Ophthalmology, Thomas Jefferson University Hospital, Philadelphia, PA, USA, marlenemoster@aol.com

Jason Much, MD Department of Ophthalmology, University of Virginia, Charlottesville, VA, USA, jwm7e@virginia.edu

Prathima Neerukonda, MD Department of Ophthalmology, Emory University, Atlanta, GA, USA, prathima77@gmail.com

Emory Patterson, MD Department of Ophthalmology, Medical College of Georgia, Augusta, GA, USA, epatterson@mcg.edu

Brooks J. Poley, MD Department of Ophthalmology, Volunteers in Medicine Clinic, Hilton Head Island, SC, USA, scbrooks@hargray.com

Rengappa Ramakrishnan, MD Department of Glaucoma, Aravind Eye Hospital, Tirunelveli, TN, India, drrk@tv1.aravind.org

Alan L. Robin, MD University of Maryland, Baltimore, MD, USA; Johns Hopkins University, Baltimore, MD, USA; Bloomberg School of Public Health, Johns Hopkins University, Baltimore, MD, USA, arobin@glaucomaexpert.com

Thomas W. Samuelson, MD Department of Ophthalmology, University of Minnesota, Phillips Eye Institute, Minneapolis, MN, USA, twsamuelson@mneye.com

Parthasarathy Sathyan, Dip.N.B. Department of Glaucoma, Aravind Eye Hospital, Peelamedu, Coimbatore, TN, India, dr.sathyan.p@gamil.com

Richard R. Schulze Jr., M. Phil. (Oxon), MD Schulze Eye Center, Savannah, GA, USA, richardschulze@comcast.net

Remo Susanna Jr., MD Department of Ophthalmology, University of São Paulo, São Paulo, Brazil, rsussana@terra.com.br

Diamond Y. Tam, MD Department of Ophthalmology, University of Toronto, Toronto, ONT, Canada, diamondtam@gmail.com

Miguel A. Teus, MD, PhD Department of Ophthalmology, Hospital Universitario “Príncipe de Asturias”, Universidad de Alcalá, Madrid, Spain, mteus@teleline.es

James C. Tsai, MD, FACS Department of Ophthalmology & Visual Science, Department of Ophthalmology, Yale-New Haven Hospital, Yale University School of Medicine, New Haven, CT, USA, james.tsai@yale.edu

Rengaraj Venkatesh, MD Department of Glaucoma, Aravind Eye Hospital, Thavalakuppam, Pondicherry, India, venkatesh@ponddy.aravind.org

Steven D. Vold, MD Boozman-Hof Regional Eye Clinic, P.A., Rogers, AR, USA, svold@cox.net

M. Edward Wilson Jr., MD Department of Ophthalmology, Storm Eye Institute, Medical University of South Carolina, Charleston, SC, USA, wilsonme@musc.edu

Nikolaos G. Ziakas, MD, PhD 1st University Department of Ophthalmology, AHEPA Hospital, Thessaloniki, Greece, nikolasziakas@yahoo.gr

Part I

Cataract Surgery

Chapter 1

Approach to Cataract Surgery in Glaucoma Patients

Graham A. Lee and Ivan Goldberg

Introduction

As both glaucoma and cataract are increasingly frequent with increasing age, glaucoma patients undergoing cataract surgery are common. These patients require a carefully planned approach to achieve not only a successful cataract extraction outcome but, more importantly, long-term control of their glaucoma.

Clinical History

Is cataract surgery necessary? Determine the degree of visual disability from the cataract versus that from the glaucoma; for the patient, it is the summed visual disability that affects him or her. To have realistic expectations of the potential visual benefits from surgery, patients need to understand the difference. Unless visual loss from glaucoma in the two eyes overlaps, the irreversible glaucoma damage may not be obvious to the patient. Cataract-induced visual loss presents as progressive reduction in visual acuity and in loss of fine detail and contrast (especially in low light), and glare; if allowed to progress, this may threaten a patient's ability to drive and his or her ambulatory vision. In patients with both glaucomatous and cataractous loss, this distinction may not be clear: Glaucoma can manifest as paracentral scotomas, while cortical cataract can present as peripheral loss.

Preoperative Assessment

Glaucoma patients require the same careful preoperative examination as all cataract patients. Secondary

glaucomas present specific challenges during cataract surgery; preoperative surgical planning minimizes risks of complications.

Cornea

In well-controlled glaucoma, the cornea in most patients is normal for their age. Epithelial and stromal edema (e.g., with high intraocular pressure [IOP], bullous keratopathy, and the iridocorneal endothelial [ICE] syndrome) interferes with visualization of intraocular structures (Figs. 1.1 and 1.2). Keratic precipitates may indicate previous uveitis (Fig. 1.3). Moderate endothelial loss of around 7% has been observed following trabeculectomy compared with a loss of 2.6% following deep sclerectomy.¹ More endothelial loss occurs with two-site phacotrabeculectomy compared with one-site.² This may influence choice of procedure in already

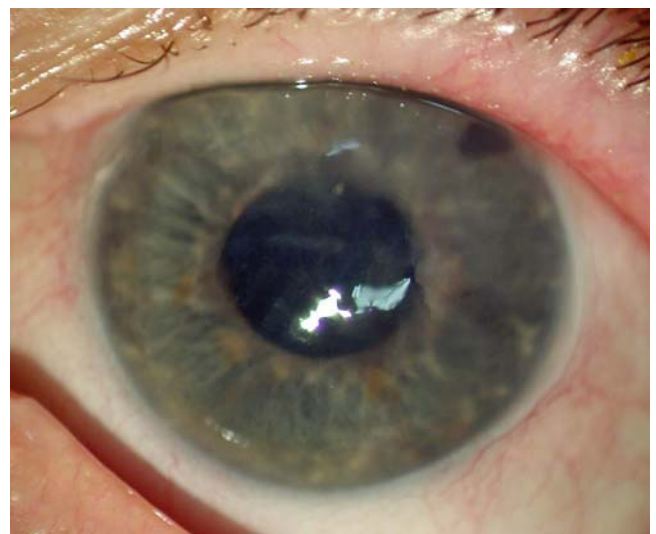


Fig. 1.1 Bullous keratopathy showing irregular ocular surface and stromal edema

G.A. Lee (✉)
Department of Ophthalmology, Royal Brisbane Hospital, Brisbane,
QLD 4029, Australia
e-mail: eye@cityeye.com.au

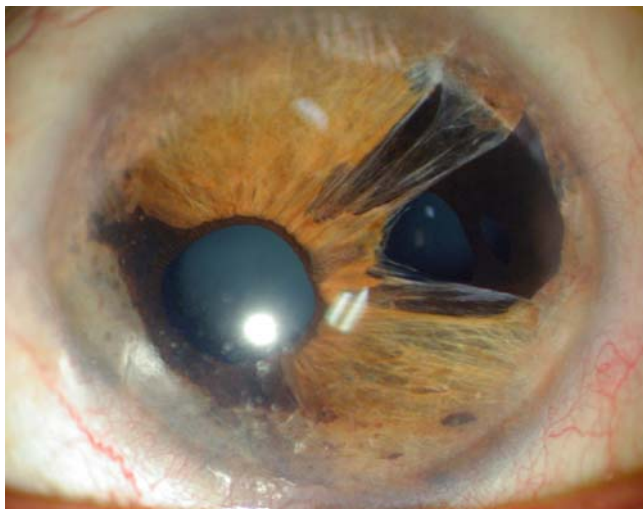


Fig. 1.2 Iridocorneal (ICE) Syndrome showing polycoria, corectopia, ectropian uveae, iris nodules, and iris stromal atrophy

compromised corneas, but the degree of IOP lowering needed for a particular patient is more critical.

Gonioscopy

Vital in all patients, gonioscopic assessment of the angle is especially important in those with glaucoma. If less than 2.4 mm, anterior chamber depth is a significant risk factor for angle closure.³ Occludable and partially closed angles often reopen following cataract removal (Fig. 1.4a, b); however, there may be persistent peripheral anterior synechial closure (Fig. 1.5). Intermittent iridotrabecular contact might explain

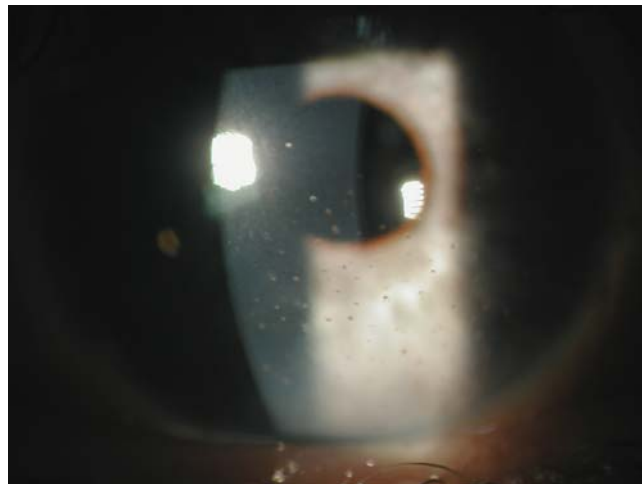


Fig. 1.3 Keratic precipitates in uveitic glaucoma

outflow damage despite an apparently open angle.⁴ Trabecular meshwork pigment with radial transillumination defects indicates pigment dispersion (Fig. 1.6a, b). Pseudoexfoliative (PXF) material on the anterior lens capsule, iris, and meshwork indicates an increased risk of zonular and capsular weakness, and of lens dislocation (Fig. 1.7; see also Chapter 15).

Optic Nerve

The neuroretinal rim is the key to diagnose glaucoma and to stage damage. Visual field loss should correspond to optic

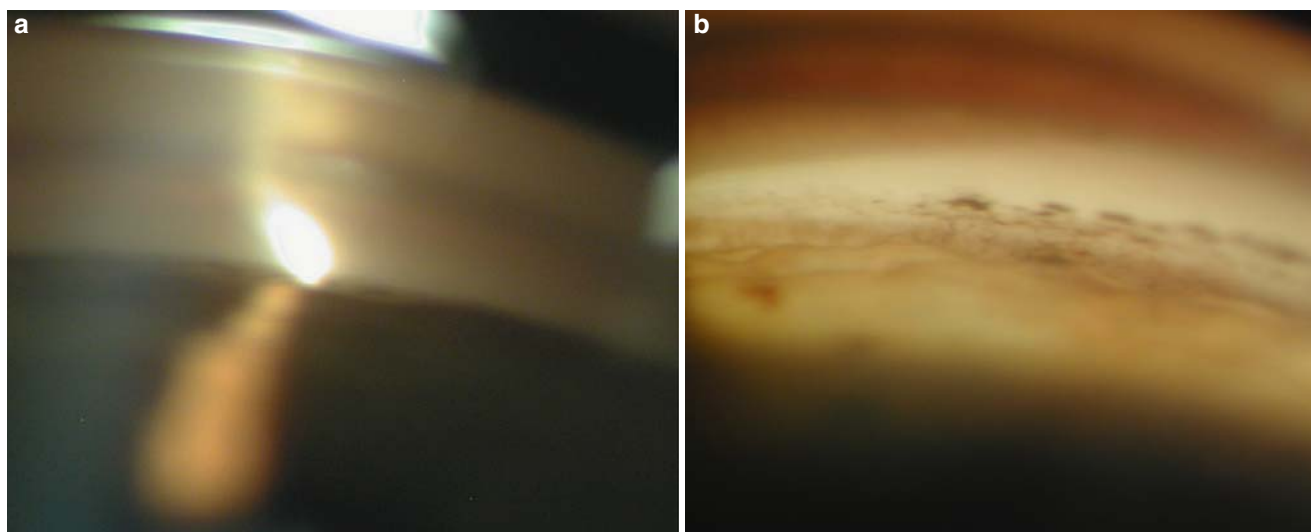


Fig. 1.4 (a) Gonioscopic view of superior angle pre-cataract extraction in angle-closure glaucoma. (b) Gonioscopic view of superior angle post-cataract extraction in angle-closure glaucoma




Fig. 1.5 Gonioscopic view showing peripheral anterior synechiae following cataract extraction

nerve rim thinning and nerve fiber layer defects. Without such correlation, suspect non-glaucomatous causes. Dense cataract can make disc assessment difficult or impossible. While advanced damage suggests a poorer visual prognosis following cataract surgery, removal of a dense cataract might improve both vision and IOP control (see Chapter 3). Look for shunt vessels (previous branch or central retinal vein occlusions) (Fig. 1.8), disc hemorrhages (increased risk of glaucoma progression) (Fig. 1.9), neovascularization, and disc drusen.

Silicone Oil

Silicone oil retinal tamponade following complicated vitreoretinal surgery may precipitate posterior subcapsular lens

opacities and/or secondary glaucoma. Biometry in the presence of silicone oil is altered; Murray et al.⁵ reported a mean ratio of true axial length to measured axial length of 0.71 (Fig. 1.10). Calculated intraocular lens (IOL) power depends on whether the oil is to be retained or removed at the time of cataract surgery. Preserving the integrity of the posterior capsule is important to keep oil from entering the anterior segment; this reduces the probability of silicone oil-induced IOP increases and potential silicone oil keratopathy (Fig. 1.11).

Investigations

Field Analysis

Mean deviation (MD) levels in standard automated perimetry indicate severity of visual loss from both glaucoma and cataract. Pattern standard deviation (PSD) or its equivalent reduces the effect of overall field depression from a uniform cataract (Fig. 1.12a, b). Visual field changes after cataract extraction in patients with advanced field loss⁶ showed mean values for MD and PSD of -13.2 and 6.4 dB before and -11.9 and 6.8 dB after cataract surgery ($P \leq 0.001$ for all comparisons). Mean (\pm SD) number of abnormal points on pattern deviation plot was 26.7 ± 9.4 and 27.5 ± 9.0 before and after cataract surgery, respectively ($P = 0.02$). Scotoma depth index did not change after cataract extraction (-19.3 versus -19.2 dB, $P = 0.90$). Cataract extraction generally improved the visual field; this was most marked in eyes with less advanced glaucomatous damage. Enlargement of scotomas was statistically significant, but was not clinically

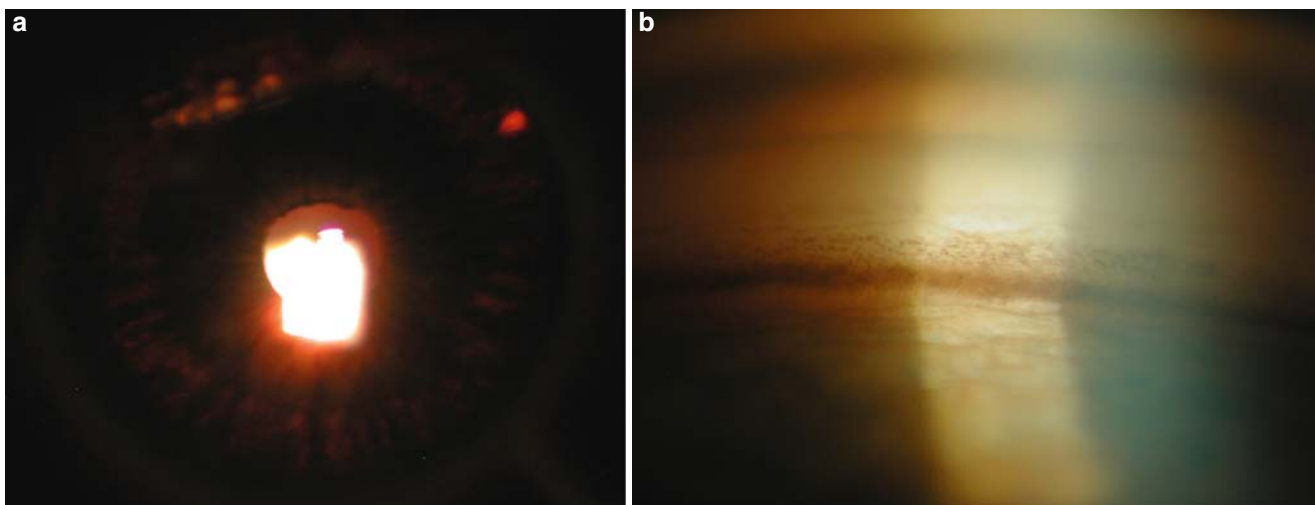


Fig. 1.6 (a) Retroillumination of the iris demonstrating transillumination defects in pigment dispersion syndrome. (b) Gonioscopic view of increased pigmentation of the posterior trabecular meshwork in pigment dispersion syndrome

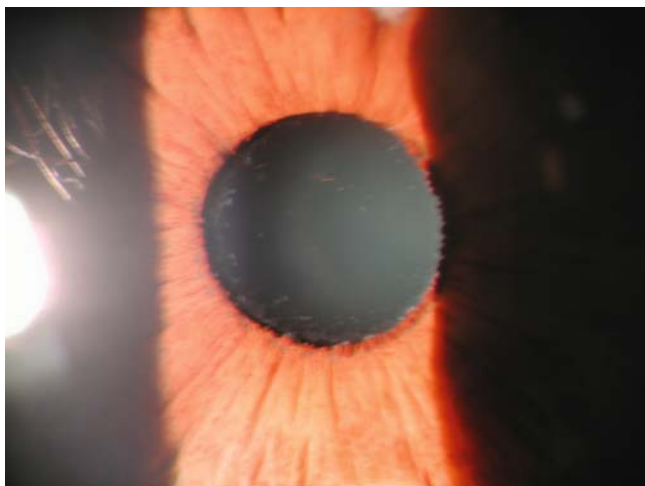


Fig. 1.7 Pseudoexfoliation (PXF) syndrome with material deposited on anterior lens capsule and pupil margin

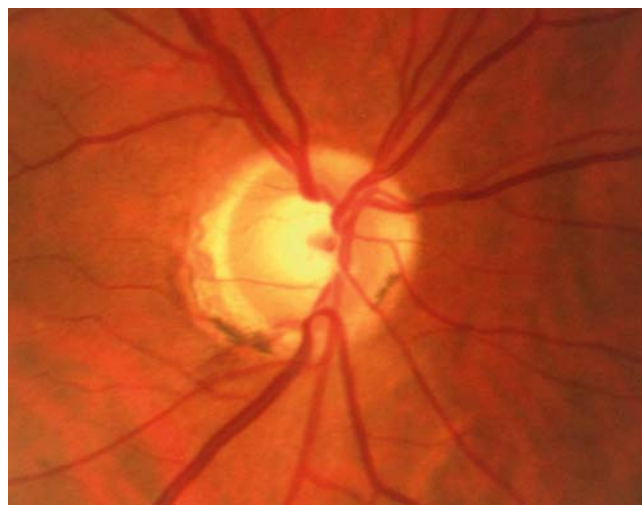


Fig. 1.9 Disc hemorrhage at 7 o'clock at the disc rim

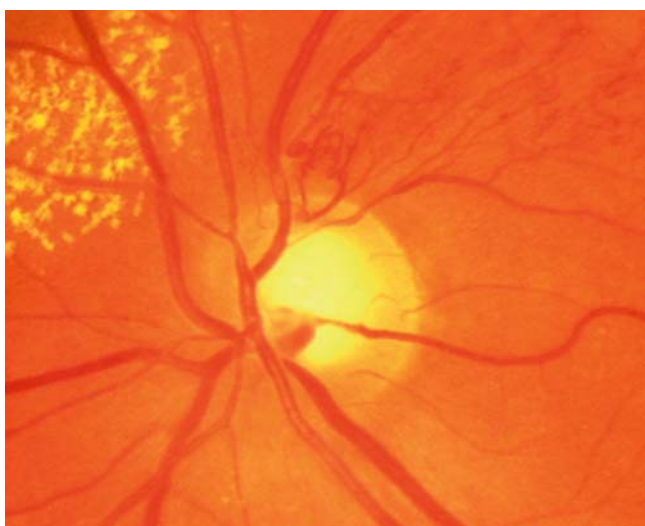

Fig. 1.8 Shunt vessels at the disc following branch retinal vein occlusion

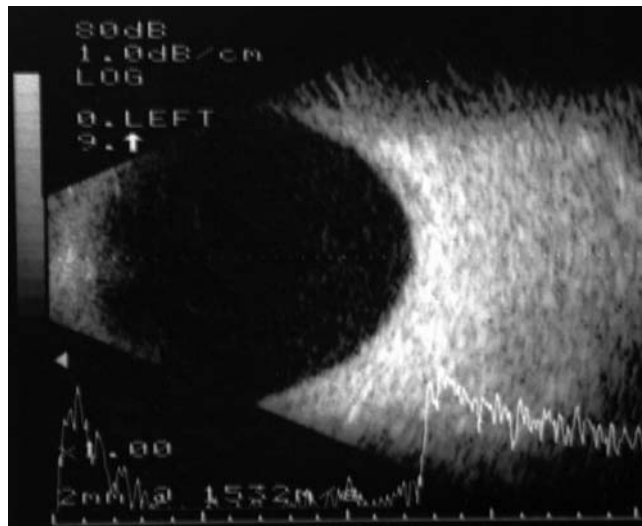


Fig. 1.10 Ultrasound of eye filled with silicone oil. The silicone oil artifactually "elongates" the axial length of the globe

meaningful. No improvement of sensitivity was observed in the deepest part of the scotomas. In a subset of the Collaborative Initial Glaucoma Treatment Trial, visual field testing before and after cataract extraction showed an improved MD but a worse PSD.⁷ Other studies have found improvement of the MD with no change in mean PSD on SITA perimetry.⁸ Cai et al. showed the amplitude of the AccuMap (objective multifocal visual evoked potential perimetry) was increased after cataract surgery ($382.6 \text{ nV} \pm 146.7 \text{ nV}$ versus $308.0 \text{ nV} \pm 96.6 \text{ nV}$; $P < 0.01$). The AccuMap severity index (ASI) was decreased following lens removal (48.6 ± 42.4 versus 90.0 ± 54.8 , $P < 0.001$; $P < 0.001$).⁹

Focal lens opacities or cortical changes may simulate glaucomatous patterns of field loss, making it more difficult

to separate the effects of the two pathologies. Advanced age-related cataracts may cause apparent false-positive responses with screening frequency doubling perimetry; even mild posterior subcapsular opacities may yield false-positive errors.¹⁰

Ultrasonic Biometry

A-scan biometry measures anterior chamber depth and axial lengths. In angle closure, by removing a cataractous lens with a thickness of more than 4.5 mm and replacing it with a 1-mm-thick intraocular lens (IOL), cataract surgery

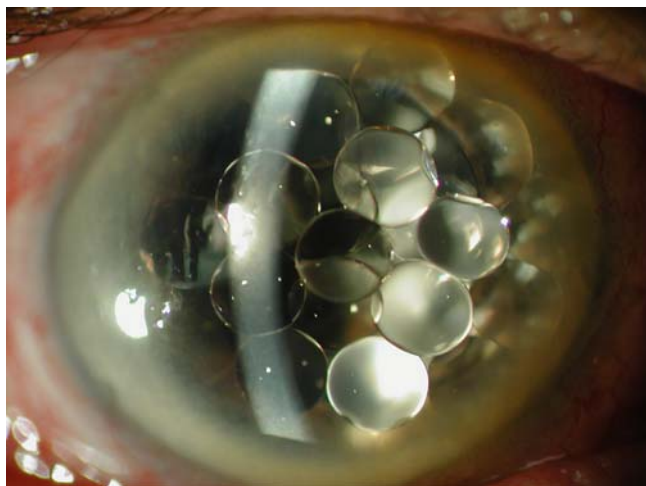


Fig. 1.11 Silicone oil droplets in anterior chamber of aphakic eye

deepens the anterior chamber and opens the angle (Fig. 1.13a, b). In eyes with shallow anterior chambers, the IOL position is usually more posterior than was the crystalline lens; an increase of 0.5 diopters to the calculated IOL power will be closer to emmetropia. A shallow anterior chamber presents an intraoperative challenge by increasing the risk of trauma to the corneal endothelium and iris. Myopi-

cally shifted prediction of refractive error is significantly more frequent following posterior chamber intraocular lens implantation with phacotrabeculectomy compared with phacoemulsification, even when surgery was uncomplicated and performed by the same surgeon.¹¹ Another study comparing refractive outcome from cataract surgery after successful trabeculectomy to cataract surgery only found no significant difference from the predicted refraction.¹² Combined cataract surgery and trabeculectomy with mitomycin C tends to shorten the axial length and induces a corneal astigmatism and increased mean keratometry.¹³ Despite this alteration of the axial length and corneal curvature, the refractive outcome after a combined operation did not differ significantly from the predicted refraction. At present there is insufficient evidence to make firm recommendations as to the use of multifocal lenses in patients with glaucoma.¹⁴

Specular Microscopy/Pachymetry

Look for corneal endothelial compromise; expect it in the ICE syndrome or after penetrating keratoplasty. If the cell count is less than 500 viable cells/square millimeter and/or

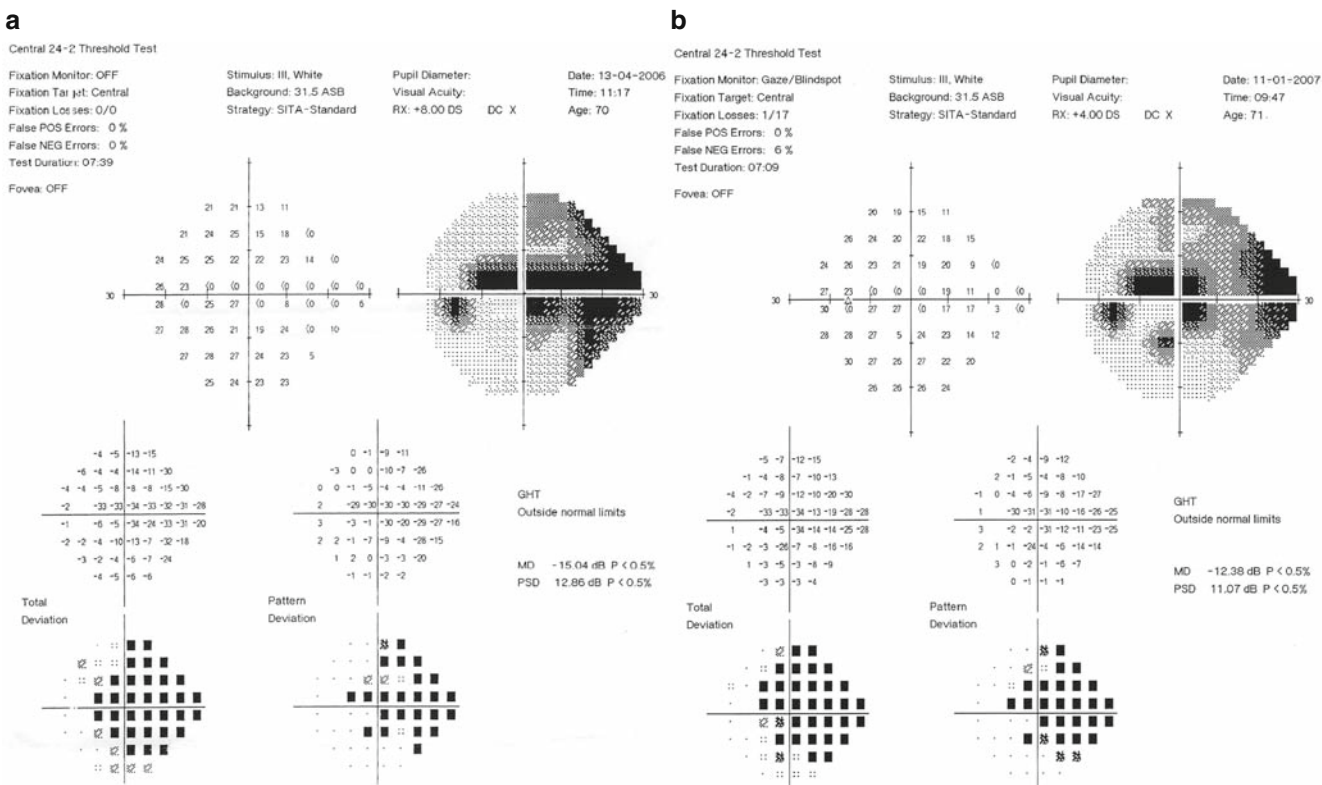


Fig. 1.12 (a) Humphrey field analysis (Central 24-2) demonstrating glaucomatous field loss in the presence of dense nuclear sclerosis. (b) Humphrey field analysis (Central 24-2) demonstrating improvement in MD and to a lesser extent the PSD following cataract surgery

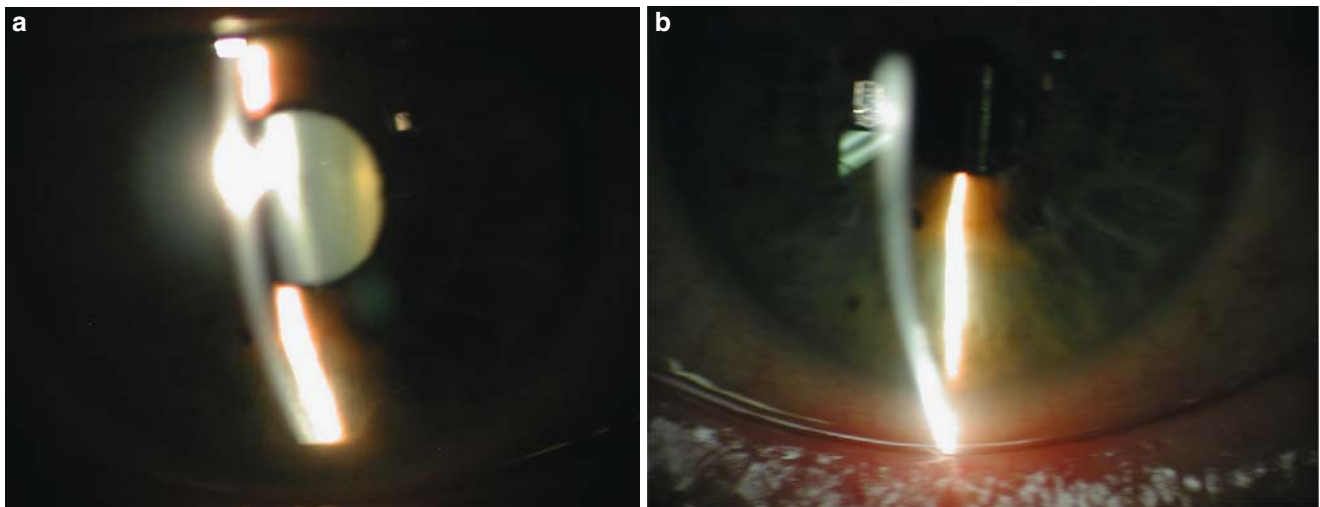


Fig. 1.13 (a) Narrowing of the anterior chamber pre-cataract surgery. (b) Widening of the anterior chamber post-cataract surgery

the central corneal thickness is greater than 640 μm , there is a significant risk of corneal decompensation post cataract surgery.¹⁵ Combined corneal grafting and cataract removal is an option.

Imaging of the Nerve Fiber Layer

The thickness of the nerve fiber layer is a measure of optic nerve structural integrity. While it complements the clinical assessment of the neuroretinal rim, it may be useful in anomalous discs and when cup:disc ratio is not assessable (Fig. 1.14a, b). If imaging demonstrates good preservation of the nerve fiber layer, then visual improvement following cataract surgery is more likely. Dense media opacities interfere with scan quality and thus measurement reliability. Savini et al. reported that cataract density influenced retinal nerve fiber layer (RNFL) thickness, as measured by optical coherence tomography (OCT) (Carl Zeiss Meditec, Dublin, CA). Postoperative measurements were higher than preoperative measurements in all quadrants (temporal $P = 0.011$; superior $P = 0.0098$; nasal $P < 0.0001$; inferior $P = 0.0081$) and in 360° averages ($P < 0.0001$). More advanced lens opacities correlated with a higher apparent decrease in RNFL thickness ($r = 0.4071$, $P = 0.0434$). While pupil size only marginally affected RNFL measurements performed by Stratus OCT, the presence and degree of cataract seemed to be significant. Consider this when using OCT to help diagnose glaucoma and other neuro-ophthalmologic disorders affecting the RNFL in the presence of a cataract.¹⁶

Visante/Pentacam/Orb Scan

Various technologies image the anterior segment in detail. These are particularly useful in patients with crowded anterior segments (Figs. 1.15a, b and 1.16a, b). When planning anterior segment surgery in complex eyes, such technology can provide guidance. Dawczynski et al. studied the effect of phacoemulsification on the anterior chamber depth (ACD) and angle (ACA) in primary open angle glaucoma (POAG) and angle-closure glaucoma (ACG) compared with normals.¹⁷ After cataract extraction, ACD and ACA increased significantly in the ACG group (3.1 ± 0.4 mm versus 1.8 ± 0.2 mm, $P < 0.005$; and $32.3^\circ \pm 7.7^\circ$ versus $16.0^\circ \pm 4.7^\circ$, $P < 0.005$). In the POAG and control groups, ACD and ACA also increased postoperatively, but not as much as in the ACG group

Consent

Patients undergoing cataract surgery expect a good visual outcome. Glaucoma patients with vision compromised by optic nerve damage that will not be improved by cataract removal need to be realistic in their expectations: their surgery is NOT necessarily the same as that performed for their friends and relatives. The consent process needs to address this carefully and unambiguously so that the doctor and the patient have aligned hopes and expectations.

“Snuff-out” syndrome is the loss of the remaining central visual field during or following any intraocular surgery. It is usually irreversible. Retro- or peribulbar anesthetic injection

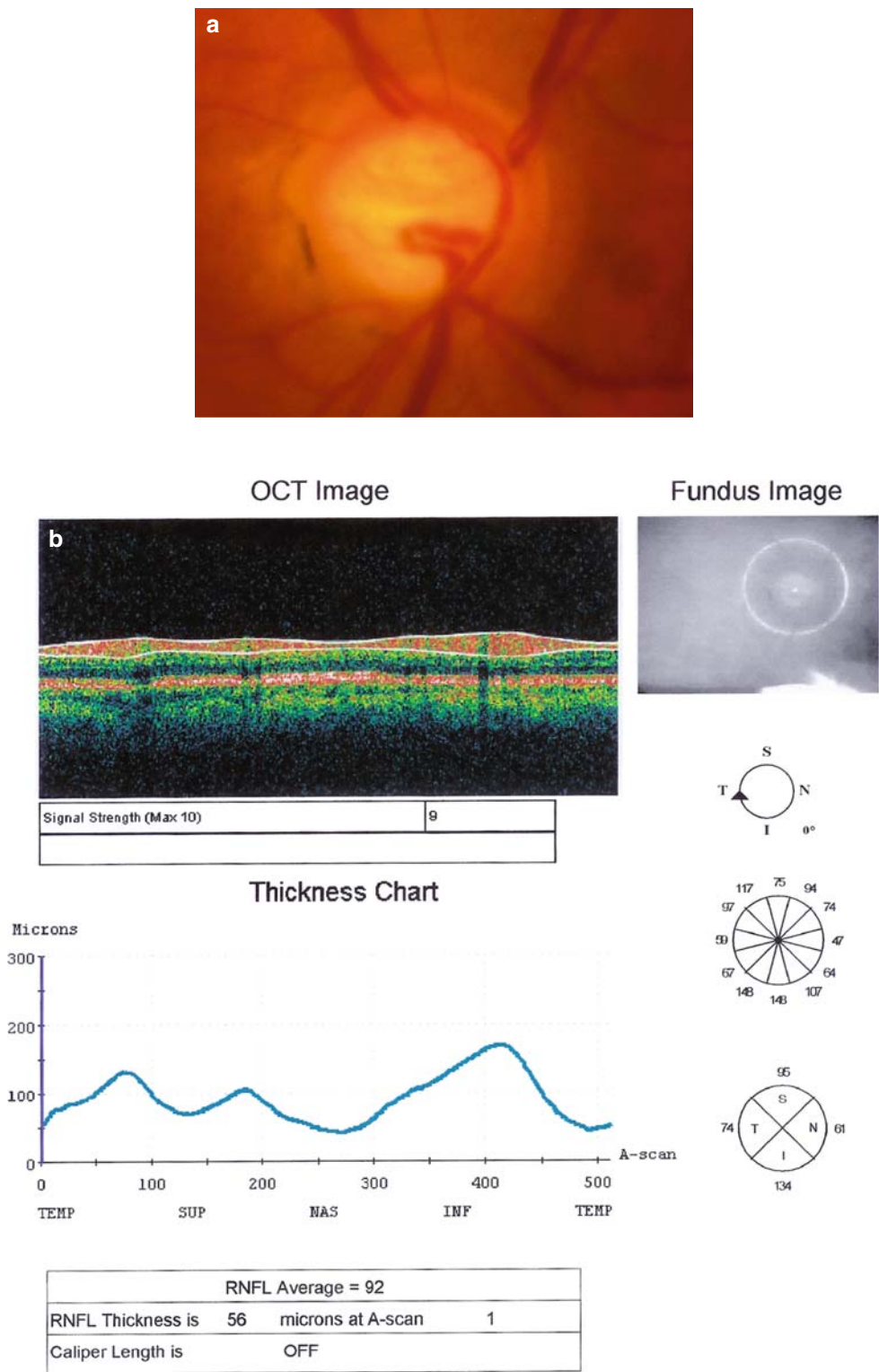


Fig. 1.14 (a) Anomalous cupping at the disc in a healthy patient. (b) OCT scan confirming normal nerve fiber layer

with a Honan's balloon or a similar device can raise IOP to over 50 mmHg.¹⁸ Topical anesthesia may be the preferred technique to try to avoid excess pressure on the globe (see

Chapter 2). Eyes with absolute splitting of fixation (<0 sensitivity, 1° from fixation on perimetric testing) are more at risk.¹⁹

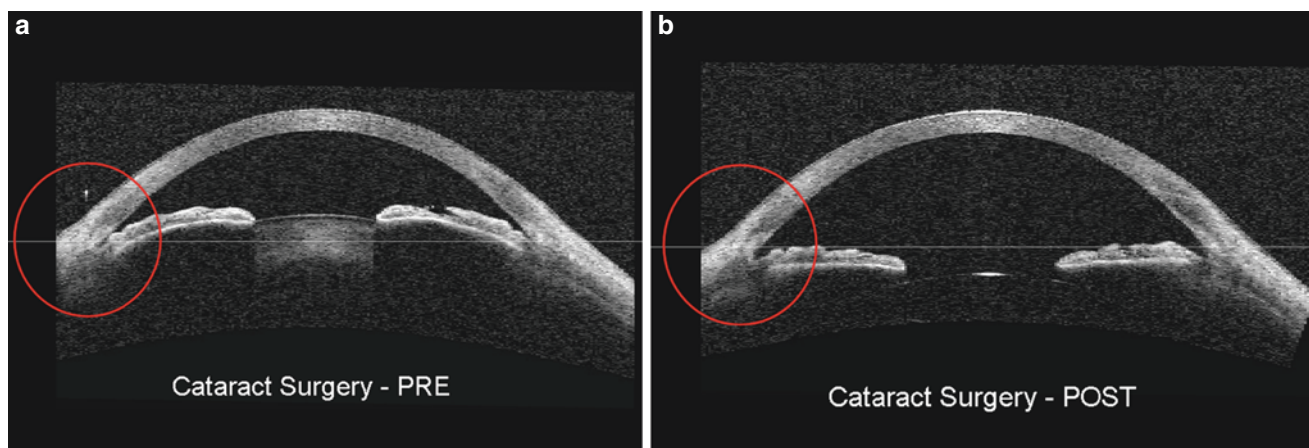


Fig. 1.15 (a) Visante anterior segment image of angle-closure glaucoma demonstrating closing of angle and shallow anterior chamber. (b) Visante anterior segment image of angle-closure glaucoma demon-

strating angle opening following cataract removal (Horizontal line in Fig. 1.15 represents the interscleral spur line) (Figures courtesy of Dr. Lance Liu)

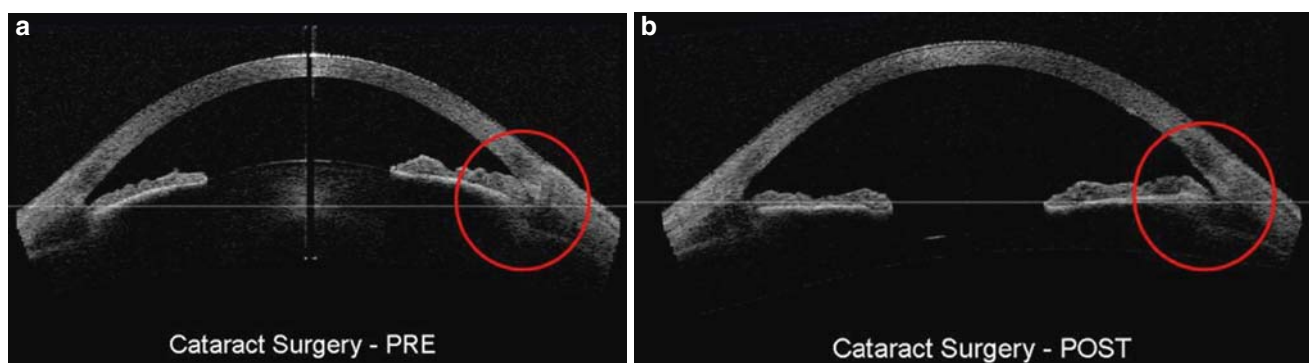


Fig. 1.16 (a) Visante anterior segment image of plateau iris syndrome demonstrating crowding of the angle. (b) Visante anterior segment image of plateau iris syndrome demon-

strating limited angle opening following cataract removal (Horizontal line in Fig. 1.16 represents the interscleral spur line) (Figures courtesy of Dr. Lance Liu)

The aims of surgery need to be clearly stated. In angle-closure patients where cataract removal aims to reopen the angle, the corrected vision may still be good, with minimal lens opacities. Vision is less likely to be improved but the aim is to improve IOP control, and to protect the angle structures from further damage (see Chapter 18). Often these patients are hyperopic, with the surgery able to correct the refractive error. Cataract removal and IOL insertion in the other eye might be needed to correct anisometropia.

Preoperative Preparation for Cataract Surgery in the Glaucoma Patient

Most glaucoma patients instill one or more medications prior to cataract surgery. Commonest are the prostaglandin analogues (latanoprost, travoprost, or bimatoprost). This medication class, prior to and in the early postoperative phase,

has been associated with cystoid macular edema.^{20–22} The literature offers conflicting advice whether to withdraw a drug of this type. In advanced glaucomatous optic nerve atrophy where IOP fluctuation could result in visually significant compromise, glaucoma medications should be continued. In earlier stages of glaucoma when the IOP control is less critical, ceasing the glaucoma medications postoperatively provides an opportunity to assess the degree of IOP lowering from the cataract surgery alone, with the potential to reduce the number of medications and to avoid the increased risk of cystoid macula edema (see Chapter 4). A reverse therapeutic trial postoperatively may permit controlled cessation of one medication at a time. Chronic use of pilocarpine results in a small pupil that poorly dilates; previous cessation may make no difference. Pupil stretching or expanders are often required and should be anticipated (see Chapter 3).

Especially in advanced glaucoma, IOP fluctuations might critically destroy surviving nerve fibers. Anticipate and

manage them: a history of high IOP is a strong risk factor.²³ For example, it has been shown that IOP spikes greater than 30 mmHg in the first 24 h might be prevented by timolol maleate 0.5% at the end of the cataract procedure.²⁴

Preoperative Peripheral Iridotomy

Angle-closure patients are at risk of pupil block if dilated. Peripheral iridotomy might be indicated to allow safe fundal examination preoperatively and if there is a delay in performing the surgery.

Anticoagulants

Patients on anticoagulants (including aspirin, non-steroidal anti-inflammatory drugs, warfarin, and clopidogrel) are at increased risk of hemorrhage. In some patients these medications can be ceased safely 10 days pre-surgery (4 days for warfarin) and restarted afterward. When it is critical for the patient to remain on the anticoagulant, consult with other doctors caring for the patient, and consider switching to heparin (e.g., subcutaneous enoxaparin) until the day of surgery. If anticoagulants cannot be ceased, a topical approach is preferable to avoid the bleeding risks of injection. Patients who are unsuitable for topical surgery may need a general anesthetic. Systemic anticoagulation has also been associated with the risk of suprachoroidal hemorrhage.²⁵

Steroids

Topical and even oral steroids used preoperatively might help patients at risk of heightened inflammation. In uveitic glaucoma patients, quiet the eye as much and for as long as possible prior to surgery. With adequate inflammation suppression, phacotrabeculectomy with mitomycin C can be an effective and safe therapeutic option for secondary cataract and glaucoma in uveitic eyes. Lower surgical success rates might follow later resurgence of inflammation.²⁶ A combined cataract surgery with glaucoma drainage device is an alternative to phacotrabeculectomy. See Chapter 11.

Approach to Surgery

Glaucoma patients can present with visual loss from cataract and cataract patients can present with glaucoma.²⁷ The aims of surgery in each situation need to be defined clearly,

with the doctor and patient reaching a common understanding. For most patients the perceived goal is often improved vision. This may not be achievable. It is for the doctor to communicate realistic aims, which include the following:

1. Improvement of vision if cataract is a significant cause of loss—the greater the loss from glaucoma, the less certain is such improvement.
2. Maintenance of vision if further loss from glaucoma is threatened.
3. Control of IOP if the cataract is involved in the mechanisms raising IOP or if a filtration operation is being performed to improve IOP control, or to allow cessation of medications with the concurrent existence of cataract to be managed.

Cataract Only

If visual field loss has been stabilized by adequate IOP control, perform cataract surgery when reduction in visual function interferes with daily living. Consider cataract surgery alone if glaucoma damage is relatively mild, when there are no other relevant ocular pathologies and visual improvement is likely. Provided IOP control is maintained postoperatively, no further procedure should be necessary.

In other patients with mild-to-moderate elevation of IOP, cataract extraction alone may lower IOP adequately. Mathalone et al. evaluated long-term IOP control after sutureless clear corneal phacoemulsification in eyes with medically controlled glaucoma. At 12 months, mean IOP decrease was $1.5 \text{ mmHg} \pm 4.4 \text{ (SD)}$, and $1.9 \pm 4.9 \text{ mmHg}$ at 24 months. The mean decrease in the number of medications was 0.53 ± 0.86 ($P = 0.4$) at 12 months and 0.38 ± 0.9 ($P = 0.4$) at 24 months.²⁸ Phacoemulsification in non-glaucomatous pseudoexfoliation syndrome patients significantly reduced IOP by about 3.5 mmHg at 1 year.²⁹ Pseudoexfoliative glaucoma patients demonstrated more IOP reduction than did normals and primary open angle glaucoma patients undergoing phacoemulsification.³⁰ In patients with primary angle-closure, both IOP and the need for glaucoma drugs could be reduced by phacoemulsification alone.³¹ IOP fell from a mean preoperative level of $19.7 \pm 6.1 \text{ mmHg}$ (range 11–40 mmHg) to $15.5 \pm 3.9 \text{ mmHg}$ (range 9–26 mmHg) at final follow-up ($P = 0.022$) (paired t-test), while the number of glaucoma agents fell from a mean 1.91 ± 0.77 (range 1–3) to 0.52 ± 0.87 (range 0–3) at final follow-up ($P < 0.001$; paired t-test). Early phacoemulsification appeared to be more effective to prevent an IOP rise than laser peripheral iridoplasty in patients who had had an aborted episode of acute primary angle closure.³² Phacoemulsification reduced

the mean number of medications and consistently increased Shaffer gonioscopy grading. The effect of peripheral laser iridotomy compared with cataract surgery on the angle showed residual angle closure after iridotomy in 27 (38.6%) of 70 eyes; this was confirmed functionally by the dark room prone test and morphologically by ultrasound biomicroscopy (UBM). Eyes with IOP of ≥ 20 mmHg or with a glaucomatous visual field defect before iridotomy had a significantly higher prevalence of residual angle closure after iridotomy than did eyes without these findings ($P < 0.05$). In all the eyes with residual angle closure after iridotomy, the response to the prone test became negative after cataract surgery, with significant lowering of IOP ($P < 0.01$).³³ Residual angle closure after iridotomy was common, especially in eyes with primary angle closure and poorly controlled IOP or glaucomatous optic neuropathy. Cataract surgery effectively resolved residual angle closure after iridotomy and lowered IOP. Using UBM, Nonaka et al. measured anterior chamber depth (ACD), angle opening distance at points 500 μm from the scleral spur (AOD500), and trabecular-ciliary process distance (TCPD).³⁴ Correlated with one another, all parameters increased significantly after cataract surgery ($P < 0.001$). Cataract surgery not only eliminated pupillary block but also attenuated any anterior positioning of the ciliary processes.

In 12 consecutive patients with end-stage glaucoma who underwent cataract surgery, 6 months postoperatively, Altmeier et al. reported³⁵ improved mean visual acuity (from 0.3 to 0.5; $P = 0.007$) and decreased IOP (by 4.4 mmHg; $P = 0.007$); anti-glaucomatous drugs decreased in number from 1.5 preoperatively to 0.8, and mean deviation (MD) improved from -27.5 to -26.4 dB ($P = 0.036$). Thus patients with progressive cataract and end-stage glaucoma can benefit from cataract surgery.

Cataract and Glaucoma Surgery

Glaucoma patients with progressive visual loss and higher than desirable IOP, despite medical and laser strategies, require drainage surgery. In the presence of a visually significant cataract, determine whether cataract or glaucoma surgery or both are needed.

If the cataract is extracted first, IOP might fall. This is particularly likely if an angle-closure mechanism is eliminated before trabecular function has been damaged.³⁶ In open angle glaucoma patients, the reasons for reduced IOP after cataract surgery are less obvious.

Routine cataract surgery provokes subclinical inflammation. Increased flare after routine cataract surgery has been measured for up to 30 days postoperatively.³⁷ As this implies exaggerated wound healing, to optimize trabeculectomy

function, it could be better to delay drainage at least until after this period. If IOP control is poor following cataract surgery, despite maximal tolerable medication, then drainage will be needed under suboptimal conditions, increasing likely benefit from anti-metabolite augmentation and/or pre- as well as postoperative topical and even oral steroids. Luo et al. measured mean aqueous flare values of 15.12 ± 2.87 , 40.24 ± 3.75 , 24.33 ± 3.38 , 21.18 ± 1.77 , and 16.51 ± 1.70 (photon counts/ms) preoperatively and on days 1, 7, 30, and 90, respectively, after trabeculectomy ($P < 0.05$) compared with 6.94 ± 2.34 , 26.27 ± 10.21 , 13.96 ± 6.44 , 9.07 ± 2.67 , and 7.16 ± 1.89 , respectively, after phacoemulsification ($P < 0.05$). Trabeculectomy disrupted the blood-aqueous barrier permanently whilst phacoemulsification affected it transiently.³⁷

Drainage Surgery Followed by Cataract Surgery

In patients with uncontrolled IOP it might be urgent to perform drainage prior to cataract surgery. When IOP is high and/or there is advanced glaucoma damage threatening fixation, there is potential for visual “snuff-out,” especially with IOP spikes. Trabeculectomy was associated with progressive cataract—predominantly the posterior subcapsular variety.³⁸

Previously functioning drainage procedures can fail after cataract surgery, most likely by bleb exposure to induced inflammatory mediators. Approximately 50% of patients undergoing clear cornea phacoemulsification after trabeculectomy will require either further medication or further surgery to maintain target IOP.^{39,40} Identified risk factors for bleb failure include cataract extraction, age greater than 60 years, interval of 5 months or less between trabeculectomy and cataract extraction, use of pre-cataract extraction glaucoma medications, and postoperative IOP > 19 mmHg within 2 weeks.⁴¹ Cataract surgery after previously successful bleb needling revision significantly compromised bleb function.⁴²

To reduce the potential for fibrosis, subconjunctival 5-fluorouracil (5-FU) with or without needling can be useful. Sharma et al. retrospectively evaluated the protective role of subconjunctival 5-FU on a preexisting bleb in patients with primary open angle glaucoma undergoing phacoemulsification more than 12 months post-trabeculectomy. Data were collected for two groups of patients: Group 1 (22 patients) received 5-FU at the end of successful phacoemulsification, whereas group 2 (25 patients) did not. Reduced IOP control was seen in 13.6% of the patients in group 1 and in 36.4% in group 2 ($P = 0.03$). 5-FU seemed to protect bleb function.⁴³ Consider it at the end of phacoemulsification in such cases. See also Chapter 16.

Table 1.1 Filtration surgeries reported combined with cataract surgery

- Trabeculectomy
- Glaucoma drainage device
- EX-PRESS mini shunt
- Viscocanalostomy
- Canaloplasty
- Non-penetrating deep sclerectomy
- Goniotomy/trabeculotomy
- Eyepass shunt

Combined Surgery

Many studies address outcomes of combined versus separate glaucoma and cataract surgery (Table 1.1). Jin et al. reviewed two-site phacotrabeculectomy in 60 eyes of 43 patients. An IOP 21 mmHg or less was achieved in 95% with or without medications; however, only 50% had an IOP of 15 mmHg or lower.⁴⁴ This suggests less effective overall IOP reduction compared with trabeculectomy with mitomycin-C alone. Murthy et al. compared the 2-year outcomes of trabeculectomy with mitomycin-C (trabMMC) versus phacotrabeculectomy with mitomycin-C (phacotrabMMC).⁴⁵ Mean IOP drop from baseline was significantly greater with trabMMC throughout the study (-10.87 ± 8.33 mmHg in trabMMC versus -6.15 ± 7.01 mmHg in phacotrabMMC at 2 years, $P = 0.003$); however, baseline IOP was also higher in the trabMMC group (26.1 mmHg versus 20.3 mmHg, $P < 0.0001$). TrabMMC and phacotrabMMC may be equally safe and effective in bringing IOP to within an acceptable target range over 2 years in advanced glaucoma patients at increased risk for filtering surgery failure, although trabMMC appears to be associated with greater IOP reduction.

Same-site or two-site combined surgery has been assessed with no clear superiority of either.^{2,45–47} The role of combined surgery is advantageous in elderly patients who are unsuitable for multiple procedures. Cotran et al. studied one-site versus two-site phacotrabeculectomy over a 3-year period.⁴⁸ The mean preoperative IOP was 20.1 ± 3.8 mmHg in the one-site group and 19.5 ± 5.3 mmHg in the two-site group ($P = 0.56$) using 2.3 ± 0.9 and 2.5 ± 0.9 anti-glaucoma medications, respectively ($P = 0.27$). After 3 years, mean IOP was 12.6 ± 4.8 mmHg in the one-site group and 11.7 ± 4.0 mmHg in the two-site group ($P = 0.40$), instilling 0.3 ± 0.7 and 0.4 ± 0.9 medications, respectively ($P = 0.59$). At the end of the study, 73% of one-site eyes and 78.4% of two-site eyes had IOPs less than 18 mmHg on no anti-glaucoma medications ($P = 0.59$). Operating time was less in the one-site group ($P < 0.0001$). One-site fornix-based and two-site limbus-based phacotrabeculectomy were similarly effective in lowering IOP and in reducing the need for

anti-glaucoma medications over a 3-year follow-up period. See Chapter 6.

Phacoemulsification can also be combined with a glaucoma drainage device, such as an Ahmed valve. Nassiri et al. reviewed 41 eyes in 31 patients who underwent combined phacoemulsification and Ahmed valve implantation. The mean IOP lowered from 28.2 ± 3.1 to 16.8 ± 2.1 , while the number of anti-glaucoma medications fell from 2.6 ± 0.66 to 1.2 ± 1.4 . An IOP of <21 mmHg on no medications or on one or more medications was achieved in 56.1 and 31.7%, respectively. Five eyes (12.2%) were considered failures (IOP < 6 mmHg or > 21 mmHg).⁴⁹ Other devices, such as the Eyepass glaucoma implant are under trial, but may not achieve consistent low target IOPs.⁵⁰ Traverso et al. and Rivier et al. have studied a stainless steel glaucoma drainage implant (Ex-PRESS). With a subconjunctival position, conjunctival erosion and extrusion were significant problems.^{51,52} Positioned under a scleral trapdoor, these problems have been addressed.⁵³ Combined phacoemulsification and ab interno trabeculectomy and endoscopic-controlled erbium:YAG-laser goniotomy require more extensive study.^{54,55}

Deep sclerectomy with phacoemulsification may be viable if augmented with intraoperative mitomycin C. There is reduced hypotensive efficacy compared with trabeculectomy but with less chance of cystic blebs, delayed bleb leaks, and infection.⁵⁶ Viscocanalostomy has also been combined with phacoemulsification.^{57–61} Non-penetrating glaucoma surgery may not achieve low enough IOPs, especially for more advanced glaucoma patients.^{62,63} Larger long-term IOP fluctuations after this type of triple procedure were associated with progressive visual field deterioration even though patients with glaucoma maintained their IOPs.⁶⁴ Combined phacoemulsification and cyclophotocoagulation, either transscleral or endoscopic, is an option, particularly in patients unsuitable for drainage surgery. Problems are the narrow margins for success, with significant risks of uncontrolled IOP needing additional photocoagulation on the one hand, and of induced phthisis on the other.^{65,66} See Chapter 13.

Phacotrabeculectomy can be supplemented with early and repeated needle revisions with 5-FU to improve outcomes.⁶⁷ In “normal pressure glaucoma,” phacoviscocanalostomy achieved 20% and 30% IOP reductions with (or without) medications in 78.5% (67.4%) and 35.5% (37.4%) of patients at 24 months, and 58.0% (44.2%) and 28.0% (26.6%) of patients at 48 months; these were better than in the cataract-extraction-only group, with only 16.0% (9.5%) and 5.7% (2.9%) at 24 months ($P < 0.001$ for each comparison, Kaplan-Meier life-table analysis with log-rank test).⁶¹ Microincision bimanual phacotrabeculectomy may be an option as incision sizes reduce in future.⁶⁸

In aqueous misdirection glaucoma, a sequential three-step surgical approach has been suggested⁶⁹: initial vitrectomy, phacoemulsification, and definitive vitrectomy. Step 1: preliminary limited core vitrectomy to “debulk” the vitreous and soften the eye. Step 2: phacoemulsification performed in a standard manner. Step 3: residual vitrectomy, zonulohyaloidectomy, and peripheral iridectomy (if not already present) to create free communication between the posterior and anterior segments.⁶⁹

A novel combined approach is circumferential viscodilation and tensioning of the inner wall of Schlemm’s canal (canaloplasty) to treat open angle glaucoma (OAG), combined with clear corneal phacoemulsification and posterior chamber IOL implantation.⁷⁰ The mean preoperative baseline IOP was 24.4 ± 6.1 mmHg (SD) with a mean of 1.5 ± 1.0 medications per eye. In all eyes, the mean postoperative IOP was 13.6 ± 3.8 mmHg at 1 month, 14.2 ± 3.6 mmHg at 3 months, 13.0 ± 2.9 mmHg at 6 months, and 13.7 ± 4.4 mmHg at 12 months. Medication use dropped to a mean of 0.2 ± 0.4 per patient at 12 months. Surgical complications were reported in five eyes (9.3%): hyphema ($n = 3$, 5.6%), Descemet’s tear ($n = 1$, 1.9%), and iris prolapse ($n = 1$, 1.9%). Transient IOP elevation of >30 mmHg was observed in four eyes (7.3%) 1 day postoperatively. Canaloplasty is a complex procedure requiring expensive equipment; its long-term value remains to be demonstrated.

Summary

A careful history, thoughtful and thorough clinical assessment with the aid of emerging technologies, planned surgical steps, and a fully informed consent process will increase the chances of a satisfactory outcome for the majority of patients. The approach to surgery and the postoperative care is just as important as the surgery itself.

References

1. Arnavielle S, Lafontaine PO, Bidot S, et al. Corneal endothelial cell changes after trabeculectomy and deep sclerectomy. *J Glaucoma*. 2007;16(3):324–8.
2. Buys YM, Chipman ML, Zack B, et al. Prospective randomized comparison of one- versus two-site Phacotrabeculectomy two-year results. *Ophthalmology*. 2008;115(7):1130–3 e1.
3. Aung T, Nolan WP, Machin D, et al. Anterior chamber depth and the risk of primary angle closure in 2 East Asian populations. *Arch Ophthalmol*. 2005;123(4):527–32.
4. Mapstone R. One gonioscopic fallacy. *Br J Ophthalmol*. 1979;63(4):221–4.
5. Murray DC, Potamitis T, Good P, et al. Biometry of the silicone oil-filled eye. 1999;13(Pt 3a):319–24.
6. Koucheiki B, Nouri-Mahdavi K, Patel G, et al. Visual field changes after cataract extraction: the AGIS experience. *Am J Ophthalmol*. 2004;138(6):1022–8.
7. Musch DC, Gillespie BW, Niziol LM, et al. Cataract extraction in the collaborative initial glaucoma treatment study: incidence, risk factors, and the effect of cataract progression and extraction on clinical and quality-of-life outcomes. *Arch Ophthalmol*. 2006;124(12):1694–700.
8. Rehman Siddiqui MA, Khairy HA, Azuara-Blanco A. Effect of cataract extraction on SITA perimetry in patients with glaucoma. *J Glaucoma*. 2007;16(2):205–8.
9. Cai Y, Lim BA, Chi L, et al. Effects of lens opacity on AccuMap multifocal objective perimetry in glaucoma. *Zhonghua Yan Ke Za Zhi*. 2006;42(11):972–6.
10. Casson RJ, James B. Effect of cataract on frequency doubling perimetry in the screening mode. *J Glaucoma*. 2006;15(1):23–5.
11. Chan JC, Lai JS, Tham CC. Comparison of postoperative refractive outcome in phacotrabeculectomy and phacoemulsification with posterior chamber intraocular lens implantation. *J Glaucoma*. 2006;15(1):26–9.
12. Tan HY, Wu SC. Refractive error with optimum intraocular lens power calculation after glaucoma filtering surgery. *J Cataract Refract Surg*. 2004;30(12):2595–7.
13. Law SK, Mansury AM, Vasudev D, Caprioli J. Effects of combined cataract surgery and trabeculectomy with mitomycin C on ocular dimensions. *Br J Ophthalmol*. 2005;89(8):1021–5.
14. Kumar BV, Phillips RP, Prasad S. Multifocal intraocular lenses in the setting of glaucoma. *Curr Opin Ophthalmol*. 2007;18(1):62–6.
15. Seitzman G. Cataract surgery in Fuchs’ dystrophy. *Curr Opin Ophthalmol*. 2005;16(4):241–5.
16. Savini G, Zanini M, Barboni P. Influence of pupil size and cataract on retinal nerve fiber layer thickness measurements by Stratus OCT. *J Glaucoma*. 2006;15(4):336–40.
17. Dawczynski J, Koenigsdoerffer E, Augsten R, et al. Anterior segment optical coherence tomography for evaluation of changes in anterior chamber angle and depth after intraocular lens implantation in eyes with glaucoma. *Eur J Ophthalmol*. 2007;17(3):363–7.
18. Morgan JE, Chandna A. Intraocular pressure after peribulbar anaesthesia: is the Honan balloon necessary? *Br J Ophthalmol*. 1995;79(1):46–9.
19. Kolker AE. Visual prognosis in advanced glaucoma: a comparison of medical and surgical therapy for retention of vision in 101 eyes with advanced glaucoma. *Trans Am Ophthalmol Soc*. 1977;75:539–55.
20. Miyake K, Ibaraki N. Prostaglandins and cystoid macular edema. *Surv Ophthalmol*. 2002;47(Suppl 1):S203–18.
21. Altintas O, Yuksel N, Karabas VL, Demirci G. Cystoid macular edema associated with latanoprost after uncomplicated cataract surgery. *Eur J Ophthalmol*. 2005;15(1):158–61.
22. Henderson BA, Kim JY, Ament CS, et al. Clinical pseudophakic cystoid macular edema. Risk factors for development and duration after treatment. *J Cataract Refract Surg*. 2007;33(9):1550–8.
23. Dietlein TS, Jordan J, Dinslage S, et al. Early postoperative spikes of the intraocular pressure (IOP) following phacoemulsification in late-stage glaucoma. *Klin Monatsbl Augenheilkd*. 2006;223(3):225–9.
24. Levkovitch-Verbin H, Habot-Wilner Z, Burla N, et al. Intraocular pressure elevation within the first 24 hours after cataract surgery in patients with glaucoma or exfoliation syndrome. *Ophthalmology*. 2008;115(1):104–8.
25. Jeganathan VSE, Ghosh S, Ruddell JB, et al. Risk factors for delayed suprachoroidal haemorrhage following glaucoma surgery. *Br J Ophthalmol*. 2008;92:1393–6.
26. Park UC, Ahn JK, Park KH, Yu HG. Phacotrabeculectomy with mitomycin C in patients with uveitis. *Am J Ophthalmol*. 2006;142(6):1005–12.

27. Chandrasekaran S, Cumming RG, Rochtchina E, Mitchell P. Associations between elevated intraocular pressure and glaucoma, use of glaucoma medications, and 5-year incident cataract: the Blue Mountains Eye Study. *Ophthalmology*. 2006;113(3):417–24.
28. Mathalone N, Hyams M, Neiman S. Long-term intraocular pressure control after clear corneal phacoemulsification in glaucoma patients. *J Cataract Refract Surg*. 2005;31(3):479–83.
29. Cimetta DJ, Cimetta AC. Intraocular pressure changes after clear corneal phacoemulsification in nonglaucomatous pseudoexfoliation syndrome. *Eur J Ophthalmol*. 2008;18(1):77–81.
30. Damji KF, Konstas AG, Liebmman JM, et al. Intraocular pressure following phacoemulsification in patients with and without exfoliation syndrome: a 2 year prospective study. *Br J Ophthalmol*. 2006;90(8):1014–8.
31. Lai JS, Tham CC, Chan JC. The clinical outcomes of cataract extraction by phacoemulsification in eyes with primary angle-closure glaucoma (PACG) and co-existing cataract: a prospective case series. *J Glaucoma*. 2006;15(1):47–52.
32. Lam DS, Leung DY, Tham CC, et al. Randomized trial of early phacoemulsification versus peripheral iridotomy to prevent intraocular pressure rise after acute primary angle closure. *Ophthalmology*. 2007;115(7):1134–40.
33. Nonaka A, Kondo T, Kikuchi M, et al. Cataract surgery for residual angle closure after peripheral laser iridotomy. *Ophthalmology*. 2005;112(6):974–9.
34. Nonaka A, Kondo T, Kikuchi M, et al. Angle widening and alteration of ciliary process configuration after cataract surgery for primary angle closure. *Ophthalmology*. 2006;113(3):437–41.
35. Altmeyer M, Wirbelauer C, Häberle H, Pham DT. Cataract surgery in patients with end-stage glaucoma. *Klin Monatsbl Augenheilkd*. 2006;223(4):297–302.
36. Bleckmann H, Keuch R. Cataract extraction including posterior chamber lens implantation in the treatment of acute glaucoma. *Ophthalmologie*. 2006;103(3):199–203.
37. Luo LX, Liu YZ, Ge J, Zhang XY, Liu YH, Wu MX. Changes of blood-aqueous barrier after phacoemulsification in patients with previous glaucoma filtering surgery. *Zhonghua Yan Ke Za Zhi*. 2005;41(2):132–5.
38. Husain R, Aung T, Gazzard G, et al. Effect of trabeculectomy on lens opacities in an East Asian population. *Arch Ophthalmol*. 2006;124(6):787–92.
39. Ehrnrooth P, Lehto I, Puska P, Laatikainen L. Phacoemulsification in trabeculectomized eyes. *Acta Ophthalmol Scand*. 2005;83(5):561–6.
40. Klink J, Schmitz B, Lieb WE, et al. Filtering bleb function after clear cornea phacoemulsification: a prospective study. *Br J Ophthalmol*. 2005;89(5):597–601.
41. Mandal AK, Chelkerkar V, Jain SS, et al. Outcome of cataract extraction and posterior chamber intraocular lens implantation following glaucoma filtration surgery. *Eye*. 2005;19(9):1000–8.
42. Rotchford AP, King AJ. Cataract surgery after needling revision of trabeculectomy blebs. *J Glaucoma*. 2007;16(6):562–6.
43. Sharma TK, Arora S, Corridan PG. Phacoemulsification in patients with previous trabeculectomy: role of 5-fluorouracil. *Eye*. 2007;21(6):780–3.
44. Jin GJ, Crandall AS, Jones JJ. Phacotrabeculectomy: assessment of outcomes and surgical improvements. *J Cataract Refract Surg*. 2007;33(7):1201–8.
45. Murthy SK, Damji KF, Pan Y, Hodge WG. Trabeculectomy and phacotrabeculectomy, with mitomycin-C, show similar two-year target IOP outcomes. *Can J Ophthalmol*. 2006;41(1):51–9.
46. Tous HM, Nevarez J. Comparison between the outcomes of combined phaco/trabeculectomy by cataract incision site. *P R Health Sci J*. 2007;26(1):29–33.
47. Shingleton BJ, Price RS, O'Donoghue MW, Goyal S. Comparison of 1-site versus 2-site phacotrabeculectomy. *J Cataract Refract Surg*. 2006;32(5):799–802.
48. Cotran PR, Roh S, McGwin G. Randomized comparison of 1-Site and 2-Site phacotrabeculectomy with 3-year follow-up. *Ophthalmology*. 2008;115(3):447–54 e1.
49. Nassiri N, Nassiri N, Sadeghi Yarandi S, Mohammadi B, Rahmani L. Combined phacoemulsification and Ahmed valve glaucoma drainage implant: a retrospective case series. *Eur J Ophthalmol*. 2008;18(2):191–8.
50. Dietlein TS, Jordan JF, Schild A, et al. Combined cataract-glaucoma surgery using the intracanalicular Eyepass glaucoma implant: first clinical results of a prospective pilot study. *J Cataract Refract Surg*. 2008;34(2):247–52.
51. Traverso CE, De Feo F, Messas-Kaplan A, et al. Long term effect on IOP of a stainless steel glaucoma drainage implant (Ex-PRESS) in combined surgery with phacoemulsification. *Br J Ophthalmol*. 2005;89(4):425–9.
52. Rivier D, Roy S, Mermoud A. Ex-PRESS R-50 miniature glaucoma implant insertion under the conjunctiva combined with cataract extraction. *J Cataract Refract Surg*. 2007;33(11):1946–52.
53. Dahan E, Carmichael TR. Implantation of a miniature glaucoma device under a scleral flap. *J Glaucoma*. 2005;14(2):98–102.
54. Ferrari E, Bandello F, Roman-Pognuz D, Menchini F. Combined clear corneal phacoemulsification and ab interno trabeculectomy: three-year case series. *J Cataract Refract Surg*. 2005;31(9):1783–8.
55. Philippin H, Wilmsmeyer S, Felten N, Ness T, Funk J. Combined cataract and glaucoma surgery: endoscope-controlled erbium:YAG-laser goniotomy versus trabeculectomy. *Graefes Arch Clin Exp Ophthalmol*. 2005;243(7):684–8.
56. Funnell CL, Clowes M, Anand N. Combined cataract and glaucoma surgery with mitomycin C: phacoemulsification-trabeculectomy compared to phacoemulsification-deep sclerectomy. *Br J Ophthalmol*. 2005;89(6):694–8.
57. Hassan KM, Awadalla MA. Results of combined phacoemulsification and viscocanalostomy in patients with cataract and pseudoexfoliative glaucoma. *Eur J Ophthalmol*. 2008;18(2):212–9.
58. Wishart MS, Dages E. Seven-year follow-up of combined cataract extraction and viscocanalostomy. *J Cataract Refract Surg*. 2006;32(12):2043–9.
59. Kobayashi H, Kobayashi K. Randomized comparison of the intraocular pressure-lowering effect of phacoviscocanalostomy and phacotrabeculectomy. *Ophthalmology*. 2007;114(5):909–14.
60. Park M, Hayashi K, Takahashi H, Tanito M, Chihara E. Phacoviscocanalostomy versus phaco-trabeculectomy: a middle-term study. *J Glaucoma*. 2006;15(5):456–61.
61. Shoji T, Tanito M, Takahashi H. Phacoviscocanalostomy versus cataract surgery only in patients with coexisting normal-tension glaucoma: midterm outcomes. *J Cataract Refract Surg*. 2007;33(7):1209–16.
62. Hondur A, Onol M, Hasanreisoglu B. Nonpenetrating glaucoma surgery: meta-analysis of recent results. *J Glaucoma*. 2008;17(2):139–46.
63. Lüke C, Dietlein TS, Lüke M, Konen W, Krieglstein GK. Phacotrabeculectomy combined with deep sclerectomy, a new technique in combined cataract and glaucoma surgery: complication profile. *Acta Ophthalmol Scand*. 2007;85(2):143–8.
64. Hong S, Seong GJ, Hong YJ. Long-term intraocular pressure fluctuation and progressive visual field deterioration in patients with glaucoma and low intraocular pressures after a triple procedure. *Arch Ophthalmol*. 2007;125(8):1010–3.
65. Janknecht P. Phacoemulsification combined with cyclophotocoagulation. *Klin Monatsbl Augenheilkd*. 2005;222(9):717–20.

66. Lin SC. Endoscopic and transscleral cyclophotocoagulation for the treatment of refractory glaucoma. *J Glaucoma*. 2008;17(3): 238–47.
67. Li G, Kasner O. Review of consecutive phacotrabeculectomies supplemented with early needle revision and antimetabolites. *Can J Ophthalmol*. 2006;41(4):457–63.
68. Tham CC, Li FC, Leung DY, Kwong YY, Yick DW, Lam DS. Microincision bimanual phacotrabeculectomy in eyes with coexisting glaucoma and cataract. *J Cataract Refract Surg*. 2006;32(11):1917–20.
69. Sharma A, Sii F, Shah P, Kirkby GR. Vitrectomy-phacoemulsification-vitrectomy for the management of aqueous misdirection syndromes in phakic eyes. *Ophthalmology*. 2006;113(11):1968–73.
70. Shingleton B, Tetz M, Korber N. Circumferential viscodilation and tensioning of Schlemm canal (canaloplasty) with temporal clear corneal phacoemulsification cataract surgery for open-angle glaucoma and visually significant cataract: one-year results. *J Cataract Refract Surg*. 2008;34(3): 433–40.