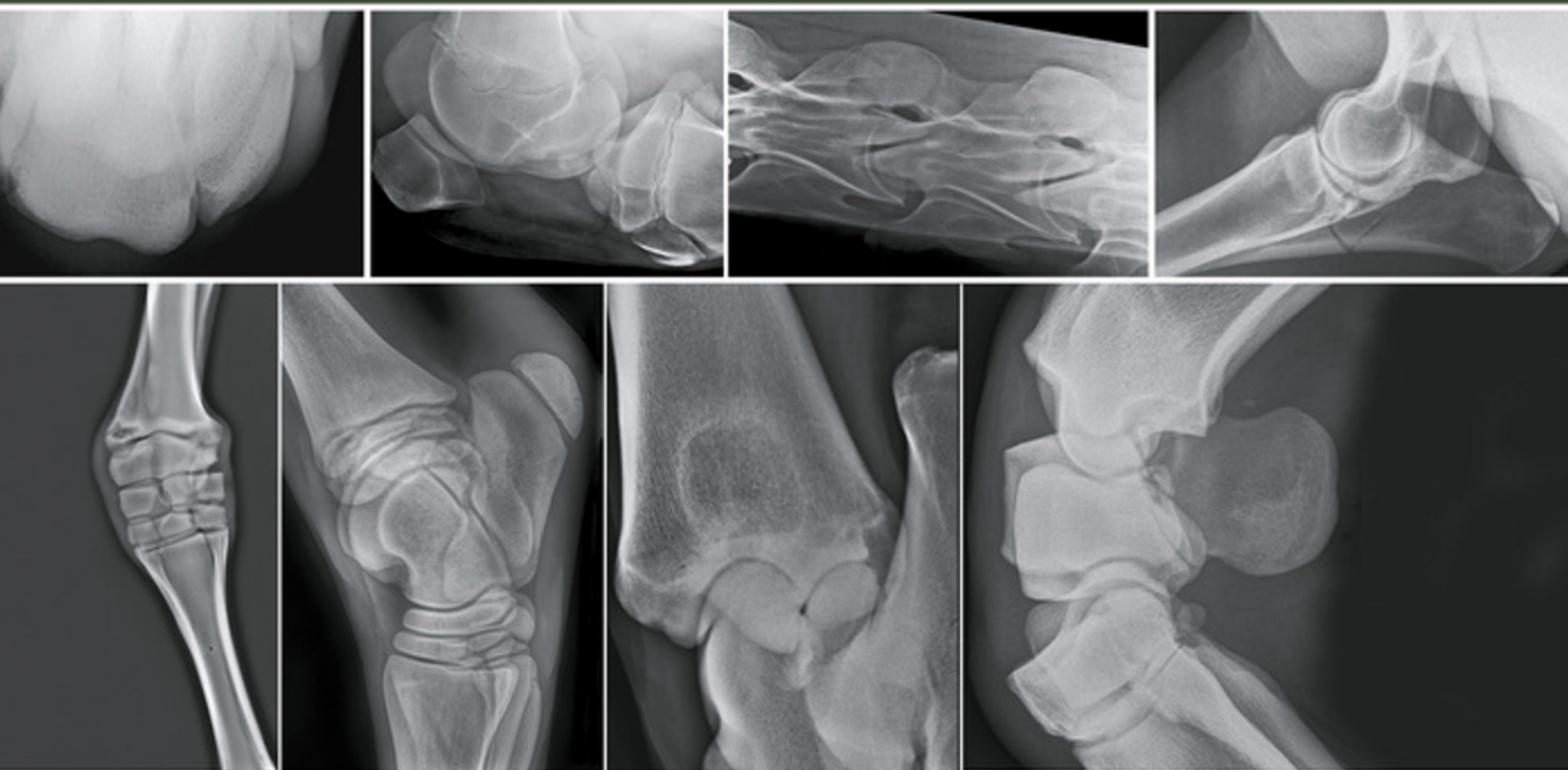

# CLINICAL RADIOLOGY OF THE HORSE

**Fourth Edition**

JANET A. BUTLER, CHRISTOPHER M. COLLES, SUE J. DYSON,  
SVEND E. KOLD AND PAUL W. POULOS



WILEY Blackwell



# Clinical Radiology of the Horse

## Fourth Edition

**JANET A. BUTLER**

*B&W Equine Group, Berkeley, UK*

**CHRISTOPHER M. COLLES**

BVetMed, PhD, MRCVS, Hon FWCF  
*Avonvale Veterinary Practice Ltd., Banbury, UK*

**SUE J. DYSON**

MA, VetMB, PhD, DEO, FRCVS  
*Centre for Equine Studies, Animal Health Trust, Newmarket, UK*

**SVEND E. KOLD**

DVM, Dr Med Vet, CUEW, RFP, MRCVS  
*Svend Kold Ltd., Tetbury, UK*

**PAUL W. POULOS**

JR, DVM, PhD, DipACVR  
*California, USA*

With contributions from **SARAH PUCHALSKI**

DVM, DipACVR  
*California, USA*

**WILEY** Blackwell

This edition first published 2017 © 2017 by John Wiley & Sons, Ltd.  
Third edition © 2008 by Janet Butler, Christopher Colles, Sue Dyson, Svend Kold and Paul Poulos  
Second edition © 2000 by Blackwell Science Ltd, a Blackwell Publishing Company  
First edition © 1993 by Blackwell Science Ltd, a Blackwell Publishing Company

*Registered Office*

John Wiley & Sons, Ltd, The Atrium, Southern Gate, Chichester, West Sussex, PO19 8SQ, UK

*Editorial Offices*

9600 Garsington Road, Oxford, OX4 2DQ, UK  
The Atrium, Southern Gate, Chichester, West Sussex, PO19 8SQ, UK  
1606 Golden Aspen Drive, Suites 103 and 104, Ames, Iowa 50010, USA

For details of our global editorial offices, for customer services and for information about how to apply for permission to reuse the copyright material in this book please see our website at [www.wiley.com/wiley-blackwell](http://www.wiley.com/wiley-blackwell)

The right of the author to be identified as the author of this work has been asserted in accordance with the UK Copyright, Designs and Patents Act 1988.

All rights reserved. No part of this publication may be reproduced, stored in a retrieval system, or transmitted, in any form or by any means, electronic, mechanical, photocopying, recording or otherwise, except as permitted by the UK Copyright, Designs and Patents Act 1988, without the prior permission of the publisher.

Designations used by companies to distinguish their products are often claimed as trademarks. All brand names and product names used in this book are trade names, service marks, trademarks or registered trademarks of their respective owners. The publisher is not associated with any product or vendor mentioned in this book. It is sold on the understanding that the publisher is not engaged in rendering professional services. If professional advice or other expert assistance is required, the services of a competent professional should be sought.

The contents of this work are intended to further general scientific research, understanding, and discussion only and are not intended and should not be relied upon as recommending or promoting a specific method, diagnosis, or treatment by health science practitioners for any particular patient. The publisher and the author make no representations or warranties with respect to the accuracy or completeness of the contents of this work and specifically disclaim all warranties, including without limitation any implied warranties of fitness for a particular purpose. In view of ongoing research, equipment modifications, changes in governmental regulations, and the constant flow of information relating to the use of medicines, equipment, and devices, the reader is urged to review and evaluate the information provided in the package insert or instructions for each medicine, equipment, or device for, among other things, any changes in the instructions or indication of usage and for added warnings and precautions. Readers should consult with a specialist where appropriate. The fact that an organisation or Website is referred to in this work as a citation and/or a potential source of further information does not mean that the author or the publisher endorses the information the organisation or Website may provide or recommendations it may make. Further, readers should be aware that Internet Websites listed in this work may have changed or disappeared between when this work was written and when it is read. No warranty may be created or extended by any promotional statements for this work. Neither the publisher nor the author shall be liable for any damages arising herefrom.

*Library of Congress Cataloging-in-Publication Data*

Names: Butler, Janet A., author. | Colles, Christopher M., author. | Dyson, Sue J., author. | Kold, Svend E., author. | Poulos, Paul W., author.  
Title: Clinical radiology of the horse / Janet A. Butler, Christopher M. Colles, Sue J. Dyson, Svend E. Kold, Paul W. Poulos.  
Description: Fourth edition. | Chichester, West Sussex, UK ; Ames, Iowa : John Wiley & Sons Ltd., 2016. | Preceded by Clinical radiology of the horse / Janet A. Butler ... [et al.]. 3rd ed. 2008. | Includes bibliographical references and index.  
Identifiers: LCCN 2016026160 | ISBN 9781118912287 (cloth) | ISBN 9781118912263 (Adobe PDF) | ISBN 9781118912270 (ePub)  
Subjects: LCSH: Horses--Anatomy--Atlases. | Veterinary radiography--Atlases. | MESH: Horse Diseases--radiography | Horses--anatomy & histology  
Classification: LCC SF765 .C56 2016 | NLM SF 951 | DDC 636.1/0891--dc23  
LC record available at <https://lcn.loc.gov/2016026160>

A catalogue record for this book is available from the British Library.

Wiley also publishes its books in a variety of electronic formats. Some content that appears in print may not be available in electronic books.

Front cover images reproduced from figures within the book: *Top row, from left to right:* See figure 7.30's caption; see figure 10.32b's caption; see 12.15a's caption; see figure 8.40's caption. *Bottom row, from left to right:* See figure 1w.11g's caption; see figure 9.3b's caption; see figure 9.34b's caption; see figure 7.28b's caption.

Set in 10.5/13pt Times Ten by SPi Global, Pondicherry, India

# Contents

ABOUT THE AUTHORS	v
PREFACE TO THE FOURTH EDITION	vii
ABOUT THE COMPANION WEBSITE	ix
<b>1 GENERAL PRINCIPLES</b>	<b>1</b>
Introduction, 1; Principles of radiography, 3; Principles of radiographic interpretation: radiology, 15; Radiological appearance of physiological changes and some common pathological lesions, 20	
<b>2 COMPUTED AND DIGITAL RADIOGRAPHY</b>	<b>41</b>
<b>3 THE FOOT</b>	<b>55</b>
Distal phalanx (pedal bone), 55; Hoof, 97; Navicular bone, 113	
<b>4 THE PROXIMAL AND MIDDLE PHALANGES AND THE PROXIMAL INTERPHALANGEAL JOINT</b>	<b>149</b>
<b>5 METACARPOPHALANGEAL AND METATARSOPHALANGEAL (FETLOCK) JOINTS</b>	<b>175</b>
<b>6 THE METACARPAL AND METATARSAL REGIONS</b>	<b>215</b>
<b>7 THE CARPUS AND ANTEBRACHIUM</b>	<b>259</b>
<b>8 THE SHOULDER, HUMERUS, ELBOW AND RADIUS</b>	<b>301</b>
Scapulohumeral (shoulder) joint and humerus, 301; Humeroradial, humeroulnar and radioulnar (elbow or cubital) joints and radius, 330	
<b>9 THE TARSUS</b>	<b>349</b>
<b>10 THE STIFLE AND TIBIA</b>	<b>399</b>
Stifle, 399; Tibia, 440	
<b>11 THE HEAD</b>	<b>449</b>
Cranium, 451; Paranasal sinuses (frontal, maxillary, conchal) and maxilla, 466; Teeth and mandible, 480; Pharynx, larynx and Eustachian tube diverticulum, 512	
<b>12 THE VERTEBRAL COLUMN</b>	<b>531</b>
Cervical vertebrae, 531; Thoracolumbar vertebrae, 569; Sacrum and coccygeal vertebrae, 602	

13	<b>THE PELVIS AND FEMUR</b>	609
	Pelvis, 609; Femur, 632	
14	<b>THE THORAX</b>	639
15	<b>THE ALIMENTARY AND URINARY SYSTEMS</b>	687
	Oesophagus, 694; Abdomen and gastrointestinal tract, 705; Urinary system, 715	
16	<b>MISCELLANEOUS TECHNIQUES</b>	723
	Arthrography and bursography, 723; Tendonography, 724; Angiography, 725; Venography, 730; Myelography, 733; Pneumocystography, 743; Intravenous Pyelography, 744; Other techniques, 744	
	<b>APPENDIX A: FUSION TIMES OF PHYSES AND SUTURE LINES</b>	749
	<b>APPENDIX B: EXPOSURE GUIDE, IMAGE QUALITY AND FILM PROCESSING FAULTS</b>	753
	<b>APPENDIX C: GLOSSARY</b>	761
	<b>INDEX</b>	767

# About the authors

## **Janet A. Butler**

Jan has specialised in equine radiography and has 40 years' experience in this field. She joined the Animal Health Trust in Newmarket in 1975 where she gained considerable experience working with many internationally renowned veterinary surgeons. Since 1997 she has been working in private practice, initially at the Willesley Equine Clinic in Gloucestershire, which since 2009 has been part of the B&W Equine Group.

## **Christopher M. Colles**

Chris qualified from the Royal Veterinary College, London in 1971. After three years in mixed practice (where he obtained a Part I Diploma in Radiology) he joined the Animal Health Trust as a clinician in 1975. He was awarded a PhD for work on Navicular Disease in 1981, and has carried out research in many areas of equine orthopaedics and radiology, having a particular interest in the horse's foot. In 1988 he returned to practice, where he became a senior partner in Avonvale Veterinary Practice, specialising in equine orthopaedics, until his recent retirement from practice. Chris still carries out some second opinion veterinary work, and teaching. He is recognised by the Royal College of Veterinary Surgeons as a Specialist in Equine Orthopaedic Surgery. Chris was awarded an Honorary Fellowship of the Worshipful Company of Farriers in 2000 in recognition of his research into conditions of the foot, and involvement with farriery education.

## **Sue J. Dyson**

After qualifying from the University of Cambridge in 1980, Sue worked for a year at New Bolton Center, University of Pennsylvania, and then spent a year in private practice in Pennsylvania. Sue then joined the Centre for Equine Studies of the Animal Health Trust, Newmarket, where she has specialised in lameness diagnosis and diagnostic imaging. Sue is recognised as a Specialist in Equine Orthopaedics by the Royal College of Veterinary Surgeons and holds the RCVS Diploma in Equine Orthopaedics. She is an Associate of the European College of Veterinary Diagnostic Imaging. She has published widely on lameness, radiography, ultrasonography, nuclear scintigraphy and magnetic resonance imaging.

## **Svend E. Kold**

Svend qualified from The Royal Veterinary and Agricultural University in Copenhagen in 1979. He then spent over 10 years at the Animal Health Trust in Newmarket, where he completed his Dr.Med.Vet Thesis on femorotibial subchondral bone cysts. After a sabbatical year at Colorado State University, he joined the Willesley Equine Clinic, Gloucestershire in 1991, where he was a partner until 2009. He is now a private consultant. He specialises in lameness

and orthopaedic diagnostics and surgery and is recognised as a Specialist in Equine Orthopaedic Surgery by the Royal College of Veterinary Surgeons. He is veterinary consultant to a European equine insurance company and is involved as an expert in many equine legal cases, both in the UK and Europe. He has published regularly on orthopaedic subjects.

**Paul W. Poulos**

Following graduation from the University of California at Davis in 1960, Paul founded a private practice. In 1972 he returned to Davis to specialise in radiology where he became Diplomate of the American College of Veterinary Radiology. He moved to the Royal Veterinary College of Stockholm, Sweden and was awarded a Veterinary Medicine Doctorate (PhD) for his thesis on osteochondrosis in 1977. He was Associate Professor of Radiology at the University of Utrecht, and on return to the USA, was Professor of Radiology at University of Florida. From 1983, he was chairman of the Department of Radiology. In 1990 Paul left academia to establish his own consulting practice, Poulos Veterinary Imaging, based in Ukiah, California. He has published widely on osteochondrosis, navicular disease and diseases of the fetlock. Paul is now retired and has not contributed to the fourth edition of the book.

**Sarah Puchalski**

Following graduation from the University of Saskatchewan in 1999, Sarah worked for two years at New Bolton Center, University of Pennsylvania. In 2001 she moved to the University of Davis, California to specialise in diagnostic imaging. In 2004, she was awarded Diplomate of the American College of Veterinary Radiology. After 12 years in the diagnostic imaging department of the University of Davis, California, Sarah recently moved into private practice in California, but remains Adjunct Associate Professor of Diagnostic Imaging, Department of Surgical and Radiological Sciences, School of Veterinary Medicine, University of California, Davis. Sarah has published widely on many aspects of diagnostic imaging.

# Preface to the fourth edition

When we wrote the first edition of *Clinical Radiology of the Horse*, it was with the intention of providing a comprehensive book dedicated to equine radiography and radiology which would be of practical help to the practitioner, as well as providing specialist information. We have now evolved to the fourth edition, but our aims remain the same. The authors have all practised radiography and radiology and have pooled our collective knowledge and experiences to write a book by consensus, rather than a multi-author text. This has tested the patience and endurance of us all, but we hope that it continues to enhance the value of the book to the reader. We thank Paul Poulos who contributed extensively to the first three editions of the book, but having now retired has opted out of involvement with the fourth edition. We wish him well for the future. We welcome Sarah Puchalski who has contributed to three of the chapters in the fourth edition, and whose additional expertise we hugely appreciate. Once again Geoff Lane has cast his knowledgeable eye over the chapter on the head, and we are grateful for his assistance in this area, while acknowledging that any errors remain our own.

We have continued to update the text of the book, reflecting advances in our own knowledge and collective experiences and incorporating relevant new published material. We are aware that there are some readers who would prefer this to be a referenced text, but that does not fit with our original aims. We have however endeavoured to include in the Further Reading lists comprehensive references not only to radiography and radiology, but also to complementary imaging techniques including ultrasonography, scintigraphy, computed tomography and magnetic resonance imaging. In some chapters these references have been collected together to refer to specific anatomical regions and conditions. In the text, which continues to focus on radiography and radiology, we make reference to other imaging techniques where they may provide valuable additional information.

We realise that in many parts of the world digital imaging has superseded conventional film-screen radiography; however, we hope that this text will continue to be used worldwide, and so we have maintained references to conventional radiography. Whatever method of radiography is used, we believe that attention to the basic details of patient preparation, positioning, exposure values and appropriate collimation are crucial for optimal image quality.

We have replaced the majority of figures with digital images, but there are a few examples of relatively unusual conditions illustrated using conventional film-screen images. We have greatly expanded the number of images by providing additional figures online. This has enabled us to provide many more examples both of normal variants and a variety of abnormal conditions. We hope that the detailed figure legends will encourage readers to evaluate

radiographs systematically, describing each abnormal feature, before establishing a differential diagnosis list, rather than 'lesion spotting'.

The majority of the images in the fourth edition were provided by the Animal Health Trust, Avonvale Veterinary Practice, B & W Equine Hospital, Willesley Equine Clinic, and the University of Davis, California, to all of whom we are grateful. We thank J. Weaver, S. Stover and T. O'Brien and the *Equine Veterinary Journal* for figures illustrating soft-tissue attachments in the fetlock and pastern regions and B. Maulet, I. Mayhew, E. Jones and T. Booth and the *Equine Veterinary Journal* for figures illustrating soft-tissue attachments in the stifle. We also thank all the veterinarians who have supplied figures which illustrate conditions which we did not have in our archives, who are cited in the legends of their respective figures.

We have all learnt from professional colleagues around the world and thank them for sharing their knowledge and experiences and also providing some constructive criticisms of previous versions of the book, which we hope have enhanced the current edition. We are enormously grateful to our wives, husbands, partners and friends, without whose willing support this book could never have been completed.

Janet A. Butler  
Christopher M. Colles  
Sue J. Dyson  
Svend E. Kold

# About the companion website

This book is accompanied by a companion website:

**[www.clinical-radiology-horse.com](http://www.clinical-radiology-horse.com)**

The website includes:

- Over 200 additional figures
- All the figures from the book
- A full list of further reading references from the book, with CrossRef hyperlinks

All the figures, including those available on the companion website, are cited in the printed book. Those that are prefixed with the letter 'w', e.g. Figures 1w.4c–f, appear online only. They are not in the printed book or e-book formats.

Access to the website requires a password – there is a prompt on the website about how to obtain the password.



# Chapter 1

## General principles

### INTRODUCTION

There are many books that describe the principles of radiography. This book does not attempt to provide detailed information in this area, and readers who do not have a working knowledge of radiography are advised to consult one of the standard texts in order to obtain the necessary understanding of radiographic physics. This book does aim to provide up-to-date information specific to the horse. As various forms of competitive and pleasure riding have become more popular, the demand on veterinary surgeons to provide the highest quality of treatment has increased. Similarly radiography of the horse in sickness as well as in health, for insurance and purchase examinations, has increased. The book is intended for all who radiograph horses and read radiographs, be they equine specialist, general practitioner or student. It gives information on equipment required, radiographic techniques, positioning, and the views required to examine the various areas of the horse adequately. It also provides information on the normal radiographic anatomy of the immature and skeletally mature horse, variations, and incidental findings. Finally it gives information on the types of lesion that may be detected, with examples of as many of the more common problems as practical, as well as brief clinical remarks where appropriate. The 'Further reading' lists at the end of each chapter are not intended to be complete lists of every paper written on the subject of the chapter. They list references that the authors consider of particular interest, and that are complementary to the text. Many of these references give more detailed information in specific areas than can be justified in a textbook of this type.

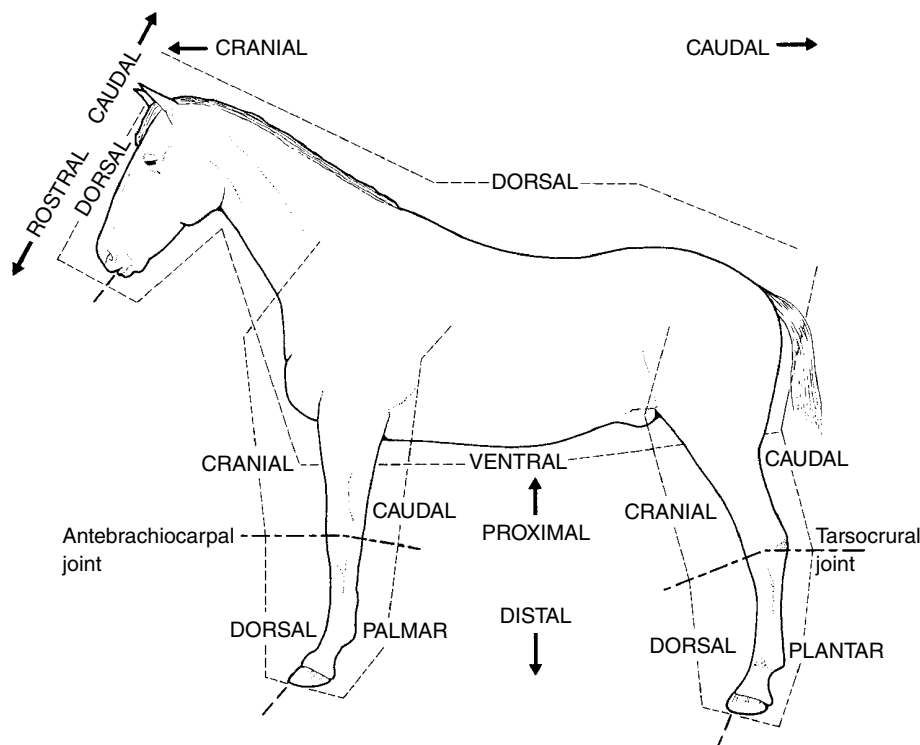
Interpreting the clinical significance of radiological changes is always difficult. We set out to indicate certain lesions that may always be regarded as clinically significant, and some that are known to have no clinical significance. The section in each chapter on 'Normal variation and incidental findings' attempts to differentiate between variations that have no clinical significance at any time (e.g. radiolucent lines in the fibula, that represent remnants of separate centres of ossification) and those that may be clinically significant for a specific but limited period of time, and therefore require further clinical investigation to determine their significance (e.g. enthesophyte formation). The radiograph is only a reflection of the state of the tissues at the fraction of a second when they were radiographed. There are many findings which indicate a past event that has 'left its mark', but which

is no longer clinically significant. For example, enthesiophyte formation at the insertion of a ligament may indicate a sprain to that ligament at some time in the past. As enthesiophytes take time to form, once they are visible on radiographs they no longer represent an acute injury, but are the result of an incident that occurred at least several weeks previously; on the other hand, their radiographic appearance might be used to approximate their age.

Radiography is a continually developing science, and as more powerful and sophisticated equipment becomes generally available, the diagnostic possibilities for veterinary practitioners become ever greater. It is hoped that this book will enable veterinarians to get the best out of their equipment, to obtain diagnostic radiographs, and to give a correct and meaningful diagnosis from the radiographs. The information in the text has been collated from the literature where possible, and complemented by the authors' experience. In some areas, however, there is no published work, or published information is contradictory. In these circumstances the authors have relied on their own collective experience, but have only presented information if all the authors are in agreement. (For example, reported physal closure times for some physes vary widely between texts. The times given are based on the authors' experience of radiographic closure, in some cases backed up by radiographic examinations of animals specifically to aid completion of this text.) The authors are experienced clinicians who routinely obtain and read equine radiographs, and it is hoped that the broad range of experience that they offer to the reader will prove to be of practical value. It is important to remember that, as radiography is a developing science, 'new' lesions and radiographic views are continually being found and described, and no text can hope to be complete when published, let alone as time progresses.

This text has made use of current terminology. *Nomina Anatomica Veterinaria* (5th edition, 2005) was consulted for anatomical terms and names. In some instances we refer first to the correct nomenclature, but make subsequent reference to the more commonly used colloquial name (e.g. distal sesamoid bone and navicular bone). It should be noted that long bones have cortices and a myeloid cavity (the medulla), sesamoid bones and short bones (e.g. the central and third tarsal bones) have compact bone and spongiosa. Radiographic views are described using the method advocated by the American College of Veterinary Radiologists, which first describes where the x-ray beam originates relative to the horse (e.g. dorsolateral), then where the beam is directed to (e.g. palmaromedial) (i.e. dorsolateral-palmaromedial oblique). Reference to Figure 1.1 may help to elucidate the current terminology used. While at first sight this may appear cumbersome, it does provide a specific description of the views, which allows them to be reproduced accurately. Terminology in common usage is included in parentheses and serves only to maintain continuity with other texts and references. A glossary (Appendix C) is also included and lists former and current scientific terminology as well as common lay terms.

We have not set out to provide radiographs of every variation of all lesions. Rather we have given typical examples of lesions, and in the text have indicated how these may vary. We also hope that the reader will use this text as a basis to understand why certain types of radiographic lesions form, and the processes that are likely to cause them, so that an inexhaustible supply of radiographic variations would be superfluous. Although we have done our utmost to find radiographs that reproduce well, we ask the reader to



**Figure 1.1** Correct nomenclature to describe various aspects of the horse.

remember that inevitably some detail is lost in the process of transferring radiographs to print, however all images can be viewed on the website, and this also provides additional images that are not present in the printed version.

## PRINCIPLES OF RADIOGRAPHY

The following paragraphs serve only as a reintroduction to the subjects of image production and differentiation. For more detailed information the reader is referred to the standard radiography texts. It is important that any radiograph is of maximum quality and yields sufficient detail to allow subtle radiographic lesions to be detected.

### Production of x-rays

An x-ray beam consists of high-energy electromagnetic radiation. It is produced by accelerating a beam of electrons into a tungsten target. This results in the production of a beam of x-rays, and the liberation of considerable energy as heat. A small target area produces a narrower beam of x-rays, and better definition on the resultant radiograph than a larger target area. The area of the target struck by electrons is called the 'focal spot'. Ninety-nine percent of the energy from the electron beam is given off as heat, not x-rays, and so there is a risk of the target being melted. Dissipating this heat and keeping the target as small as possible are major factors in design of x-ray tubes. For generators with a large output, the target in the tube is the edge of a disc. By rotating the disc at very high speeds during x-ray production, the area being heated is continually being changed, allowing a small focal spot in spite of high output. This is standard in large static x-ray generators.

Smaller mobile or portable generators generally have fixed targets, which does limit the output possible. Any x-ray beam is made up of photons of mixed wavelengths. The older half- and full-wave rectification in small x-ray generators resulted in very marked variations in the energy of the individual photons of the x-ray beam. The high-frequency generators currently available have greatly improved the consistency of the x-ray beam produced, causing less scatter and a better resultant image.

### **Production of a radiographic image**

An image is created by detecting the differential absorption of x-rays that pass through an object placed in the path of the primary x-ray beam. The x-rays that pass right through the object are either detected using conventional x-ray film, or digital images are created (see Chapter 2). The number of x-rays that are absorbed by a given thickness of a specific tissue varies between tissues, and thus affects the number of x-rays passing through to form the image. For example it is more difficult to penetrate bone than air, and therefore less x-rays reach the film if they have to penetrate bone rather than air. The areas of the image relating to relatively unobstructed x-rays are black, whereas the areas protected by bone, which absorbs or deflects a proportion of the x-rays, are paler or white. Intermediate densities of tissues produce variable shades of grey. Fat is the least dense tissue, and gives relatively black tones, with muscle and bone giving increasingly light tones. It is the juxtaposition of these tissues of varying densities that allows differentiation of form and structure.

### **Exposure factors**

Exposure factors affect the *opacity* and *contrast* of the radiographic image. The quantity of photons (x-rays) reaching the film (or digital sensor) affects opacity (blackness). This is primarily controlled by the milliamperage (mA), higher mA resulting in a greater number of photons being produced in the x-ray beam. By lengthening the time for which the beam is produced, the total number of photons is increased in proportion, i.e. doubling the time, doubles the number of photons reaching the film. This is normally recorded for any exposure as mAs, i.e. mA times time (milliamperage seconds).

A major factor influencing the number of photons reaching the film is the distance of the film from the focal spot. This is known as the focus–film distance (FFD), or the source–image distance (SID). Because the x-ray beam spreads out to cover a two-dimensional area, the number of photons reaching the film falls as a square of the distance. This means that changing the distance by a relatively small amount can have a marked effect on image opacity, although it has only a minor effect on contrast, because all areas experience a similar percentage drop in numbers of photons reaching the film.

The kilovoltage (kV) governs the energy of the x-rays and their ability to penetrate through tissue. The higher the kV, the greater the energy of the x-rays, and the greater their ability to penetrate tissues. This has some effect on opacity, but more importantly affects contrast. Soft tissues such as fat and muscle absorb limited numbers of x-rays, even of low kV. Bone however absorbs far more x-rays of low kV than high kV, so there is a relatively large difference in numbers of x-rays passing through the soft tissues compared to

the bone using low kV, giving relatively high contrast. Increasing the kV allows relatively more x-rays to penetrate through the bone, and so affects both opacity and contrast. A low kV produces a high-contrast image but has low exposure latitude; therefore the exposure values are critical for a diagnostic image. A high kV results in low contrast, but has wider exposure latitude and the exact exposure levels are less critical. With digital radiography this can be more difficult to appreciate as the algorithms applied to the image during processing can override adjustments to kV and mA.

To obtain a radiograph with the same opacity as an original but with reduced contrast, halve the mAs and increase the kV by 15% (approximately 10 kV). Conversely, to increase contrast levels, double the mAs and reduce the kV by 15% to achieve the same opacity. Normally for good bone detail the kilovoltage should be less than 70 kV. Attenuation of the x-ray beam is heavily dependent on the atomic number of the tissues, and it is desirable that photoelectric absorption predominates. Increasing the kV also results in more forward scatter (see Grid below).

### **X-ray film and image intensifying screens**

Although in many countries conventional x-ray film has been largely replaced by imaging plates, x-ray film is still in use and therefore merits discussion. Details of the structure of film, image intensifying screens and chemistry cannot be covered here, but are readily available in other radiographic textbooks. The principle however is important to an understanding of radiography. In simple terms a film consists of a cellulose acetate sheet coated with a light- (or x-ray) sensitive emulsion (a layer of complex silver halide crystals). When these crystals are subjected to x-rays (or light), they undergo partial chemical reduction, creating a latent image. Submersion in developer completes the chemical reduction. Subsequently when immersed in fixer, the reduced crystals are insoluble and remain on the film, but the unexposed crystals are dissolved, leaving the visible image. To make the system more sensitive, it is usual for the film to be placed in a cassette, which places an image intensifying screen on either side of the film. The screens fluoresce when stimulated by x-rays, and because the film is much more sensitive to light than x-rays, an image can be produced with a reduced x-ray exposure.

Important variables include the type of film being used and the compatibility of the screens, which intensify the image. It is important to match the spectral output of the screen with the spectral sensitivity of the film (see Appendix B). The large number of film and screen combinations available is beyond the scope of this book. The clinician should rely on a veterinary radiologist or knowledgeable sales person to help decide which film–screen combination is best suited to the x-ray machine and the practice, although Appendix B gives some guidelines. With a high-output x-ray machine (100 kV, 100 mAs), it is worthwhile investing in high-definition screens for use with single emulsion, relatively slow film, for distal extremity work. This gives excellent detail, but is unsuitable for low-output machines, because long exposure times result in loss of definition through movement blur. Rare earth screens are essential for obtaining high-quality images proximal to the carpus and tarsus. Old screens are like old horses, they collect scars and lose performance as they age, and therefore should be replaced on a regular basis in order to maintain the optimum level of performance. It is also important

that screens are cleaned regularly, to prevent the build-up of dust and extraneous materials within the cassette, which can result in white spots and lines on processed films.

### **Film processing**

Good darkroom practice is an important consideration in the final quality of the radiograph but is often overlooked. Correct processing, whether manual or automatic, plays a major role. Standard darkroom procedures are available in any standard radiology text and are not covered here. There are however some processing errors that often cause film artefacts (see Appendix B) and thus affect interpretation. The following is a brief review of some of the basic principles that most often affect film quality and interpretation, especially when hand processing.

### ***Film fogging***

The most common darkroom problem whether using hand or automatic processing is fogging of the film either by light leaking into the darkroom, or improper darkroom lighting. Regardless of whether blue- or green-sensitive films are used, never rely on red or ruby bulbs as the source of darkroom lighting. For blue-sensitive film use a Wratten Series 6B filter with a 7–10 Watt bulb and for green-sensitive film use a Kodak GS1 filter with a 7–10 Watt bulb. In general the Kodak GS1 works with both blue- and green-sensitive film. The safelight should be at least 1 metre from the working area. There are two methods to check film for possible fogging:

**1** In the darkroom place a sheet of film on the counter, then place an object on the film. Turn on the darkroom safelight and wait for approximately 30 seconds. This is the time it normally takes to place a film in a processor or on a hanger. Process the film as normal. If the darkroom is adequately dark and the safelight is suitable for the film, the film will be perfectly clear after developing. If the filter is incorrect or there is light leakage in the room, there will be fogging of the film around the object and the area covered by the object will be clear.

**2** Expose a film in the cassette to an x-ray beam of 1–2 mAs and 40–50 kVp. This increases the sensitivity of the film. In the dark room place the exposed film on the counter and cover two thirds of the film with cardboard. Turn on the safelight for 30 seconds then move the cardboard over another third and continue the exposure for an additional 30 seconds. Process the film normally and compare the areas for fogging as described above.

### ***Processing***

There are three stages in the processing cycle that affect the final quality of the radiograph:

- Developer – converts exposed silver halide grains to metallic silver
- Fixer – converts unexposed, undeveloped silver halides into a form that can be removed from the emulsion and clear the film
- Washing – removes residual chemicals from film emulsion.

Important factors are the temperature and dilution of the chemicals and the time the film is in the developer and fixer.

**1** Prepare the chemicals to the correct working dilution and agitate to ensure even mixing. Temperature is absolutely correlated with processing time. Deviation from time and temperature guidelines results in under- or over-development and loss of detail. At the optimal temperature of 20°C (68°F) developing time should be 5 minutes. A variation in time should be calculated for other temperatures. The temperature of the solutions should be checked after the rinse water has been on for at least 15 minutes. The darkroom should be kept at a constant temperature to assist in maintaining the solutions at the ideal temperature.

**2** During development, fixing and washing, agitate the film several times to remove any air bubbles that cling to the emulsion. Air bubbles cause light or dark spots, or circular artefacts on the film, depending upon which solution the bubbles occurred in. Care must be taken to prevent films touching or being scraped by the hangers during agitation in order to prevent scratches of the wet (swollen) emulsion, or the development of kissing defects. A kissing defect occurs when two films cling to each other during any phase of the developing process, resulting in an area of incorrect processing. This can also occur when two films overlap each other in an automatic processor. When processing several films, all films should be loaded into hangers prior to being processed in order to maintain optimal timing.

**3** Chemical levels must be high enough to cover the film in the hanger. Low chemical levels result in portions of the films being undeveloped which can result in loss of important information. To avoid chemical carry-over, in order to maintain developer and fixer strengths, fluid should drain from the film and hanger prior to placement in each solution, including the rinse tank. Loss of strength of developer results in underexposed film, while loss of fixer strength results in yellowing with age. Developer should be replenished after every session of processing to maintain it at correct working strength.

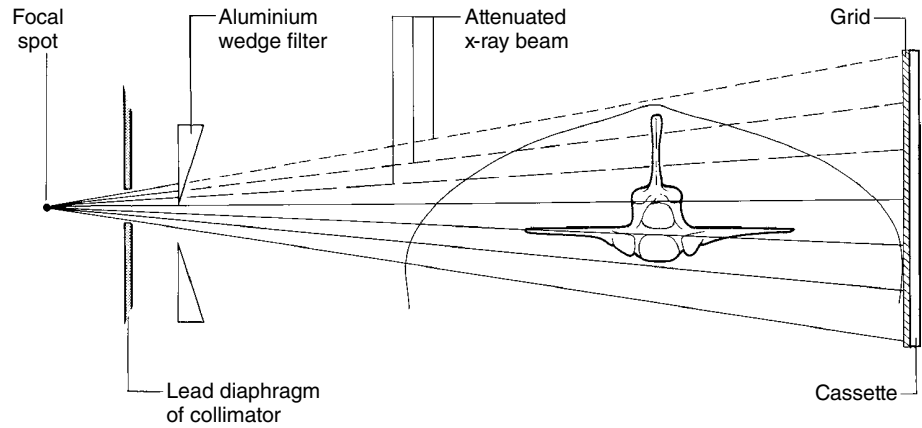
**4** Developer deteriorates when not in use, therefore it must be changed regularly. If not kept covered the developer oxidizes. In either case this results in underdevelopment.

**5** If it is essential to examine a wet film, wait until fixing is complete then quickly rinse the film and view it. Remember that wet films have swollen emulsion and detail is lost until the film is dry, when the halide crystals will have coalesced into a more definitive image!

**6** The final wash is an important part of the processing cycle to remove residual chemicals from the emulsion. This prevents discolouration and fading of the image.

#### AUTOMATIC PROCESSING

The advantages of an automatic processor over manual processing are considerable. There is absolute consistency of processing, which enables a consistent estimate of exposure values, and results in marked improvement in film quality. There are also benefits of economy and speed. With automatic processing a dry film is available to read within 60–90 seconds compared with approximately 1 hour for manually processed film. Both manual and automatic processing require proper upkeep and maintenance of equipment to ensure diagnostic quality films. Regular maintenance of the processor is important as is making sure that processing fluids are fresh and in adequate



**Figure 1.2** Use of an aluminium wedge filter placed between the x-ray machine collimator and the object to be radiographed. The upper leaves of the filter placed in the x-ray beam reduce the exposure of the upper part of the beam.

supply. The most common problems with an automatic processor occur when upkeep is not maintained.

### **Radiographic practice**

In several parts of the following text, reference is made to an aluminium wedge filter (Figure 1.2). This is placed immediately in front of the x-ray tube, and absorbs a proportion of the x-rays. It allows the intensity of the beam to be reduced in specific areas. It is of particular value when radiographing parts of the horse that show a marked change in soft-tissue thickness from one side of the film to the other, e.g. the thoracolumbar spine or stifle, but is of less value when used with digital systems.

### **Exposure chart**

It is advantageous to record the exposure settings used for each image, and gradually build an exposure chart. This should include a record of the size and age of the horse, the area radiographed, and the exposures and the film–screen combination or imaging plate used. This allows better and more consistent radiographs to be obtained, and also provides a basis for estimating the required exposures for animals of different sizes and ages. When creating this chart, it is important to maintain a constant FFD. A reduction in FFD increases the radiation reaching the screen by a square of the change in distance (necessitating a reduction in the exposure factors). An increase in distance has the opposite effect. Generally in equine radiography a FFD of 75–100 cm is used. Note that single emulsion film is particularly sensitive to changes in radiation dose; a slight change in FFD can therefore have a relatively big effect on exposure.

### **Grids**

Most of the radiation during an exposure passes through the subject and exposes the film, or is absorbed by the tissues. Some radiation however is deflected (termed ‘scatter’) and this results in a low background exposure over the entire film, causing reduced film contrast. Good collimation of the primary beam reduces the amount of scatter at acquisition (Figures 2w.1a–c). The effect of scatter can be reduced by placing a grid in front of the cassette to absorb the scattered radiation. As a rough guide, grids are generally only needed if the area being radiographed exceeds 11 cm in thickness. Thus equine extremities below

the carpus and tarsus usually do not require the use of a grid. Grids are generally not required for soft-tissue evaluation, and may be contraindicated in this situation. There are numerous types of grid, and advice on the best one for any specific situation is beyond the scope of this text. The disadvantages of a grid are that they increase the exposure required and produce lines on the films, which are sometimes found objectionable when reading the radiograph. If a focused grid is used, the x-ray beam must be perpendicular to the grid, centred on it, and at the correct FFD. When grids are of value, this is noted in the discussion of the projections described in the following text. Grids used with digital radiography have particular problems, and can cause serious image artefacts. The reader is advised to obtain specialist advice before acquiring grids for use with digital systems.

An alternative strategy is to use an air gap between the horse and the imaging plate rather than a grid. This can be helpful in areas surrounded by large muscle masses, for example the back or the pelvis, but will result in increased magnification of the area being radiographed.

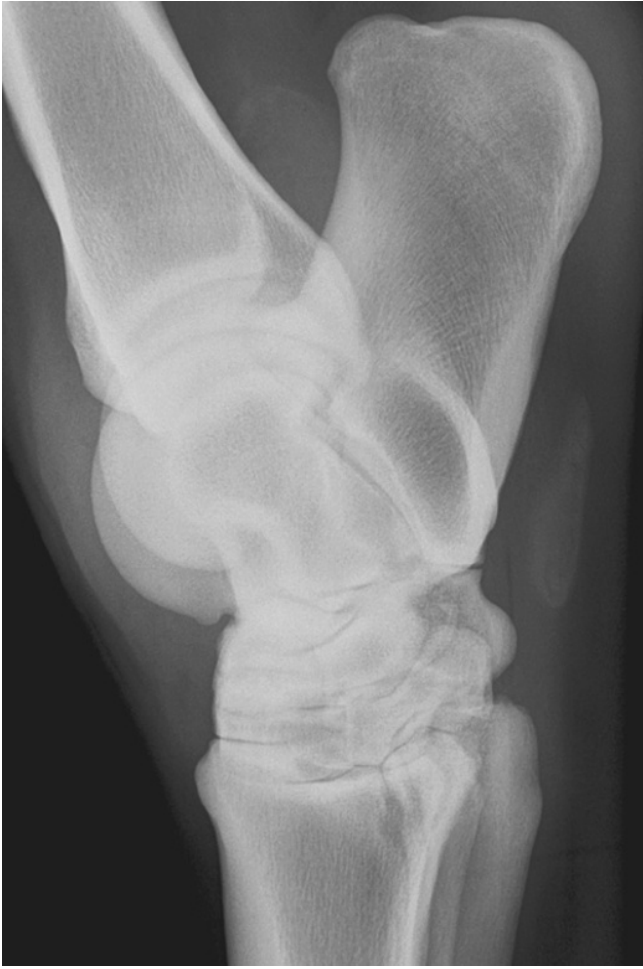### ***Preparation and positioning***

Preparation of the patient is essential to good radiography. Quiet and careful handling reduces movement, and sedation is often beneficial. Blinkers, blocking the horse's line of vision, may make it less apprehensive. Cotton wool earplugs or background music may make the horse less aware of the noise of the x-ray machine. Areas to be radiographed should be brushed to remove mud from the coat, which can produce confusing artefacts. For radiographs of the feet, the shoes normally need to be removed and the feet trimmed to remove loose horn and dirt.

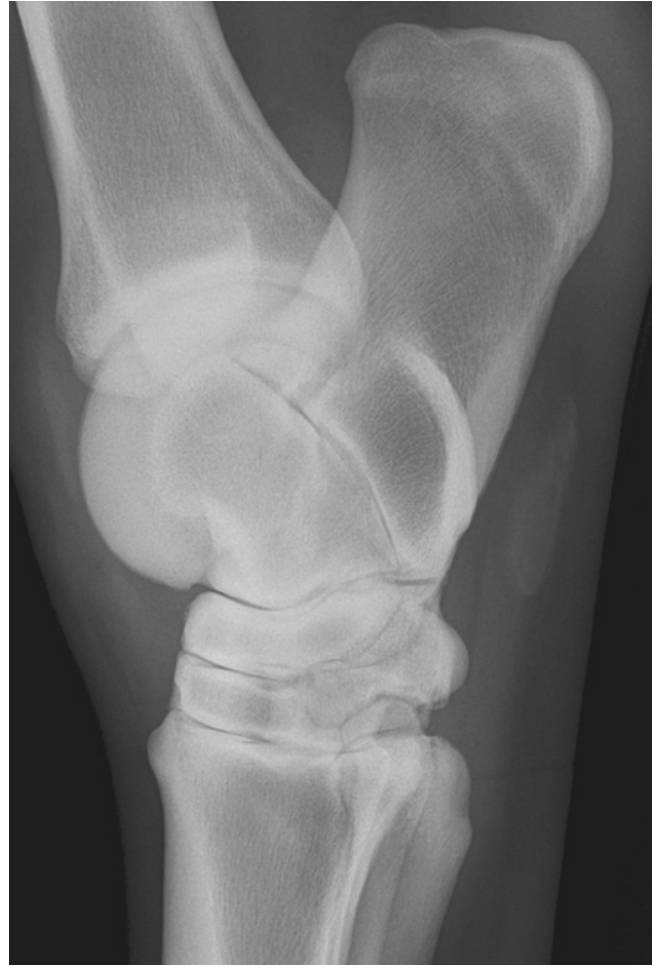It is important to ensure correct positioning of the horse before acquiring the radiograph. A small deviation in limb position can result in poor quality images with misleading information, making accurate interpretation difficult (Figure 1.3). In a well-positioned radiograph, the x-ray beam is perpendicular to the cassette to minimise image distortion.

### ***Acquisition of additional images***

It is important, if possible, to assess all the acquired images before terminating the examination. The images should be scrutinised for correct positioning and exposure, the presence of artefacts, and the identification of one or more potential lesions. Incorrect positioning may create an image which appears to have a lesion, but which disappears with correct positioning (Figures 1.4a and 1.4b, Figures 1w.4c–f; Figures 3.68b and 3.68c). The interpretation of the closeness of spinous processes is a good example. When on the margin of an image two spinous processes may appear separated because of a divergent x-ray beam, but if in the centre of the image clearly impinge (Figures 1w.5a and 1w.5b). Alternatively a lesion can be missed with inappropriate positioning, but become apparent on an image acquired with the limb correctly positioned (Figures 1.6a and 1.6b). Artefacts due to superimposition of normal structures, or the result of an opacity due to mud on the skin, can be confirmed by examination of the horse and an additional image can be acquired if necessary (Figure 1.7a, Figures 1w.7b–e). A lesion may be suspected from conventional images, but acquisition of additional images using additional projections may verify its presence and/or determine its



**Figure 1.3(a)** Lateromedial radiographic image of a hock of a 7-year-old riding horse with distension of the tarsocrural joint. This radiograph is not of diagnostic quality. The horse was standing base wide during image acquisition and as a result this is not a true lateromedial view. There is considerable overlap of the joint spaces of the talocalcaneal-centroquartal, centrodistal and tarsometatarsal joints. The trochleas of the talus are not superimposed.

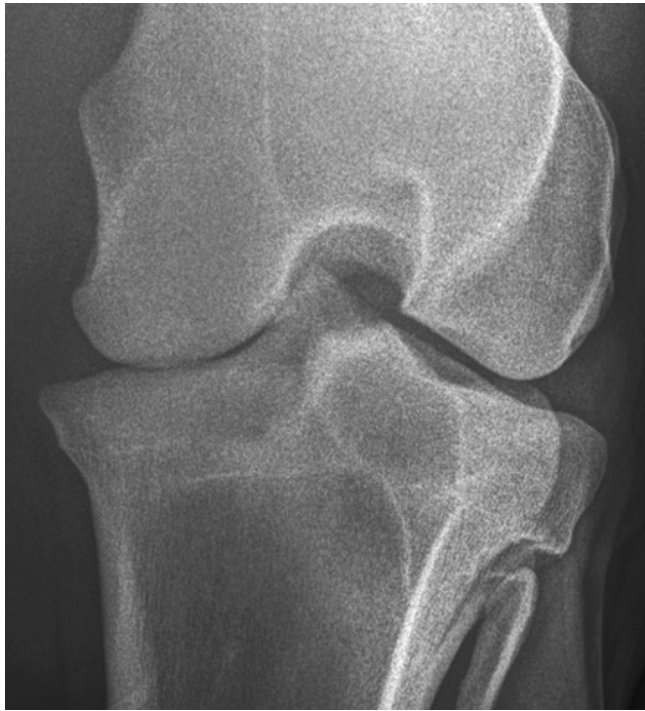

**Figure 1.3(b)** Lateromedial radiographic image of a hock of a 7-year-old riding horse, the same hock as in Figure 1.3(a). This is a well-positioned image and the joint spaces of the talocalcaneal-centroquartal, centrodistal and tarsometatarsal joints are clearly defined. The trochleas of the talus are superimposed.

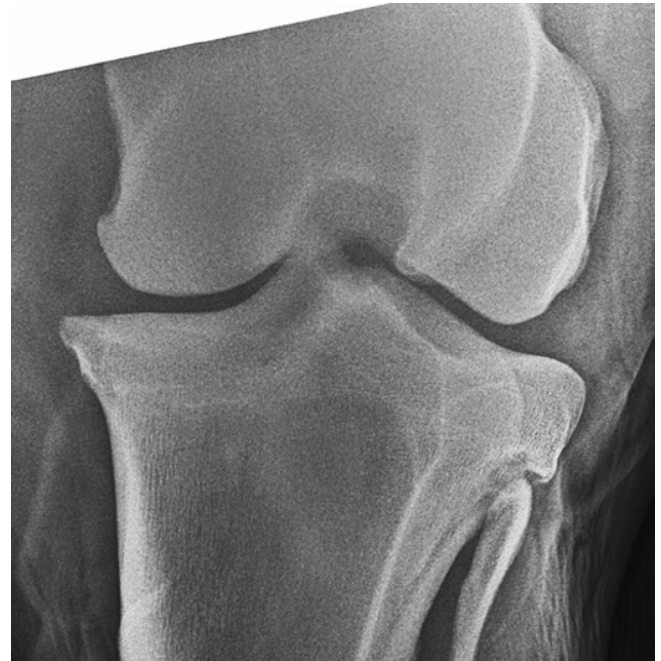position more accurately (Figures 1w.8a–e). Ideally the presence of a lesion should be verified in more than one plane.

### ***Progression of lesions***

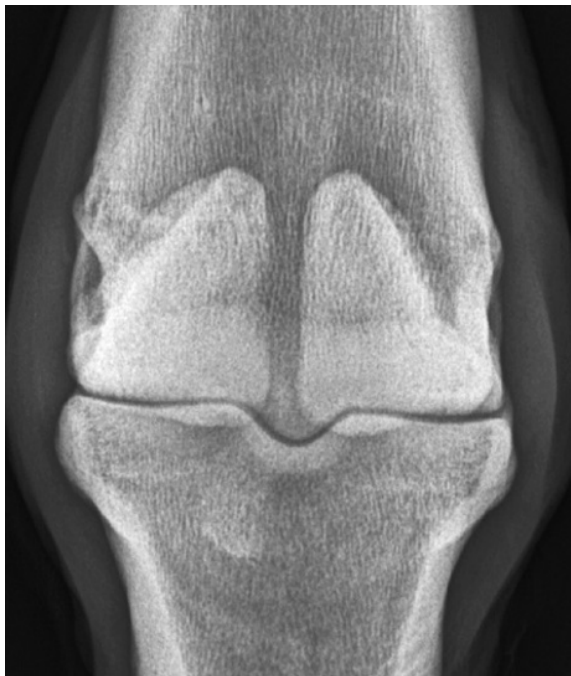Images acquired at the time of onset of lameness may show advanced radiological abnormality despite the short duration of clinical signs (e.g. advanced degenerative joint disease of the centrodistal joint) (Figure 1w.9). Clearly the development of radiological changes preceded the onset of recognisable pain. Alternatively images acquired immediately after acute onset of lameness may show no detectable abnormality, but sequential examinations may reveal progression of the underlying disease process (Figure 1.10a–c). In some instances there will be resolution of a lesion over time (Figures 1w.11a–i), but some lesions remain radiographically evident after they cease to be of clinical significance (Figure 1w.12).



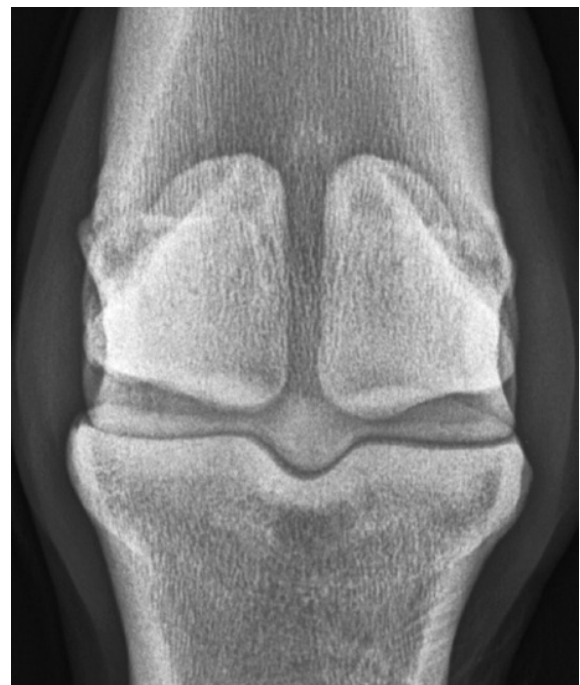**Figure 1.4(a)** Caudocranial radiographic image of a stifle. Medial is to the left. The medial femorotibial joint space appears to be markedly narrowed. This was the result of inappropriate positioning during image acquisition. The limb to be examined should be positioned caudal to the contralateral limb. Compare with Figure 1.4(b).



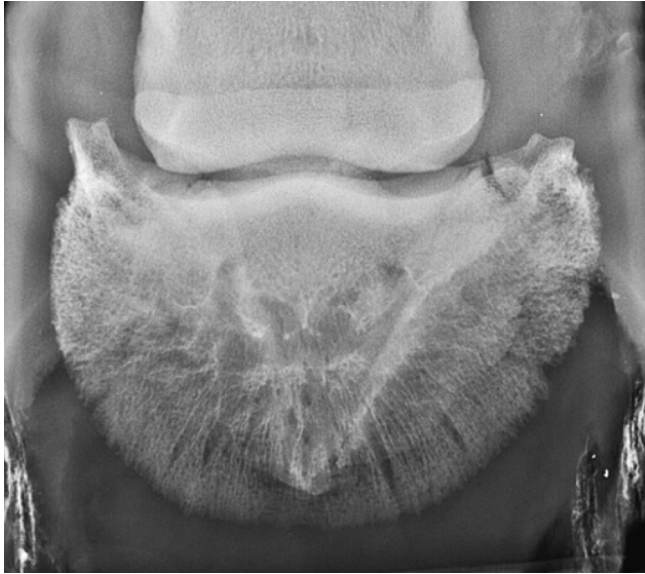
**Figure 1.4(b)** Caudocranial radiographic image of the same stifle as Figure 1.4(a). Medial is to the left. The medial femorotibial joint space is normal.



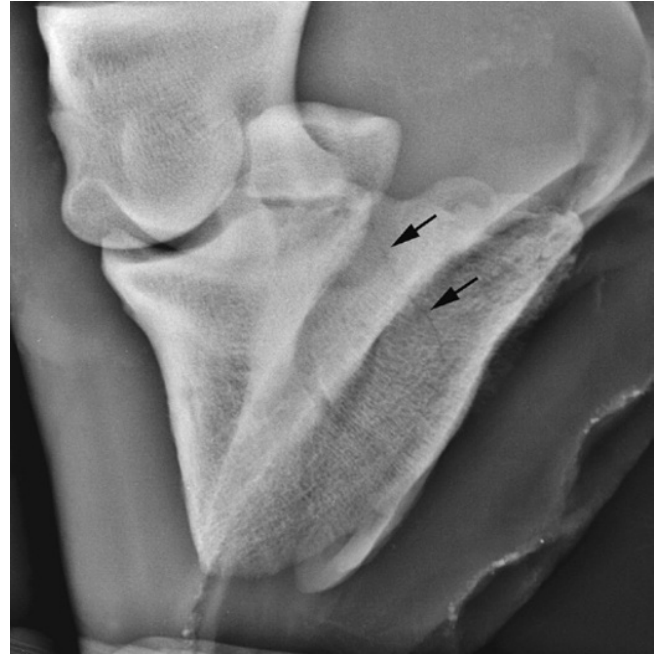**Figure 1.6(a)** Dorsopalmar radiographic image of a right metacarpophalangeal joint of a 4-year-old pony. Medial is to the left. The proximal sesamoid bones are superimposed over the metacarpophalangeal joint space.



**Figure 1.6(b)** Dorsal 10° proximal-palmarodistal oblique image of the same metacarpophalangeal joint as in Figure 1.6(a). Medial is to the left. The proximal sesamoid bones are now projected proximal to the metacarpophalangeal joint space which appears narrower medially, consistent with degenerative joint disease. Narrowing of a joint space should ideally be confirmed by being seen on more than one image.



**Figure 1.7(a)** Dorsoproximal-palmarodistal oblique image of a right front foot. Lateral is to the right. There is a radiolucent line in the lateral palmar process of the distal phalanx. This could potentially be misdiagnosed as a fracture but note that the line extends just proximal to the proximal margin of the bone and is the result of inadequate packing during image acquisition.

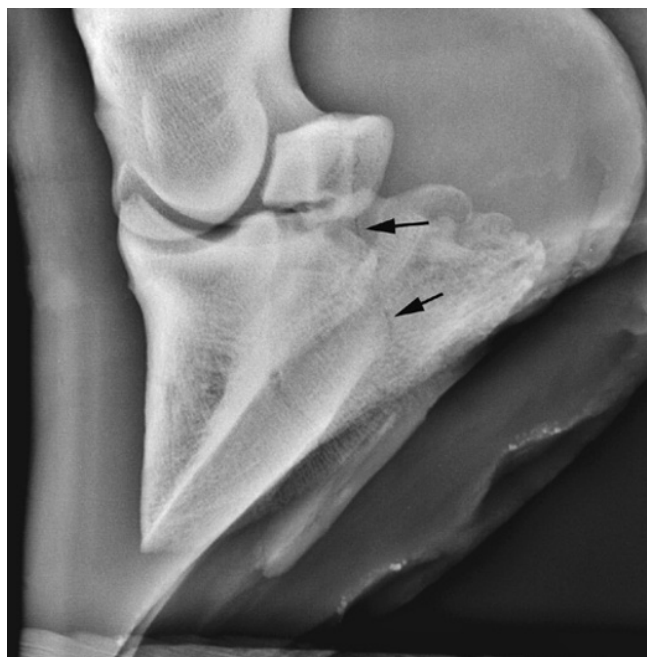


**Figure 1.10(a)** Dorsolateral-palmaromedial oblique (flexed) image of the right front foot of a 9-year-old pleasure horse with sudden-onset severe right forelimb lameness the previous day while misbehaving when loading to travel. There is a narrow radiolucent line through the lateral palmar process of the distal phalanx (arrows) representing a fracture.

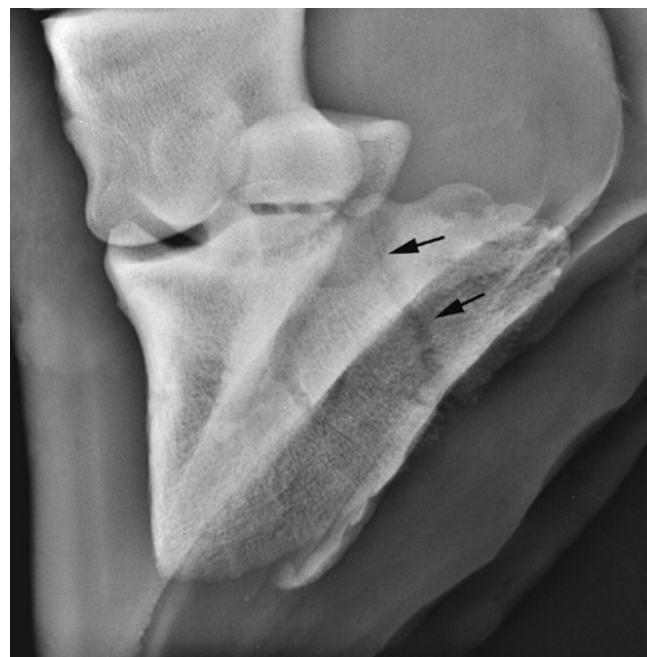### Radiation safety

Radiation safety, i.e. ensuring that personnel around the horse do not receive doses of radiation, is extremely important. There are codes of practice available in different countries, but the basic principles can be summarised as follows:

- 1** Keep the number of people present when radiographing a horse to the absolute minimum required for its safe handling.
- 2** Use appropriate restraint of the horse to keep it still during exposures (so that repeat exposure to radiation is not necessary). Sedation may be required.
- 3** Use cassette holders whenever possible. Because radiation intensity follows the inverse square law, increasing distance from the source is an important safety factor. Certain views, where 'patient tolerance' is low, may prompt the hand holding of cassettes. This may be justified if it reduces the repetition of radiographs or prevents the horse panicking. If it is essential to hand hold a cassette, then large cassettes should be used, with the x-ray beam well collimated, and the holder's gloved hands as far from the primary x-ray beam as possible.
- 4** The primary x-ray beam should be well collimated, and a light beam diaphragm used to enable maximum collimation. *No part of any attending person, even if covered with protective clothing, should be placed in the primary beam.* Protective lead clothing protects from scattered radiation only, not the primary beam. Remember that the primary beam continues through the patient and cassette, and personnel standing on the opposite side of the patient are at risk.



**Figure 1.10(b)** Dorsolateral-palmaromedial oblique (flexed) image of the same right front foot as Figure 1.10(a), 8 days later, i.e. 9 days after the onset of lameness. The margins of the fracture line are less distinct (arrows).



**Figure 1.10(c)** Dorsolateral-palmaromedial oblique (flexed) image of the same right front foot as Figures 1.10(a) and (b), 17 days after the onset of lameness. The fracture line has become wider, especially distally (arrows). This is typical progression of a fracture.

**5** All personnel who must remain present during radiography must wear protective gowns, and if near the primary beam should also wear gloves or similar hand and arm protection, and a thyroid protector.

**6** All personnel working with and around x-ray machines should be monitored using a film badge or dosimeter system.

**7** Walls of a room or stable provide a primary barrier but be aware that although dense breeze block will stop the primary beam, a wooden partition will not.

**N.B.** Digital processing of images will marginally reduce the radiation dose, but this is not a reason to ignore normal radiation safety precautions. In practice the use of digital imaging often increases the number of images acquired, and increases the need for vigilance regarding radiation safety.

### **Examination for purchase**

Because of the general acceptance of this text world-wide, it is impossible to write a comprehensive section that covers all areas of the radiographic examination included as part of a pre-purchase examination in all countries. When making such an examination, it is necessary to take into account many variable factors such as the breed and intended use, as well as considering both the country of origin and the country to which an animal is being sold. This carries many different legal implications and is therefore well beyond a text that is limited to radiology. Guidelines regarding this have been published, and the reader is referred to 'Further reading'.

As a general guide, the radiographic portion of a pre-purchase examination must first take into account the general health, age and condition of the

horse. It is important that the previous and intended use(s) of the horse are considered, with special emphasis on conditions prevalent in the relevant breed or use of the horse. The radiographic evaluation should follow the physical examination, to include areas that might be expected to face the greatest stress in the performance of the expected use, and to investigate potentially significant findings discovered during the physical examination. It is essential that if adequate interpretation is to be made, film quality must be good, and an adequate number of views obtained to evaluate the specific area(s) of concern. No simple guide can be given for this, except to say that as a general rule there must be at least two views of a suspected lesion, and it is clinically better to have too many views than too few, bearing in mind the overriding importance of radiation safety. When imaging apparently normal joints (such as fetlock or hock) it is generally necessary to obtain dorsopalmar (dorsoplantar), lateromedial and two oblique views of each joint. If the horse is to be insured, the insurance company may have specific minimum requirements for views to be obtained. Sales companies for Thoroughbred yearlings and racehorses in training frequently specify what views of which joints are required. Some countries have a designated set of radiographs that should be obtained as part of a pre-purchase examination. If a client is purchasing a horse abroad they should be advised that the radiographs obtained may not be the same as in their own country, where additional views may be considered necessary to provide a comprehensive examination.

A report on pre-purchase radiographs should begin with a clear identification of the animal examined. This must be followed by sections on each area examined, stating the views obtained and giving a clear and concise description of the radiological findings, starting with the most significant finding. Finally an opinion on the potential significance of any abnormalities should be provided, relative to the intended use of the horse. If for any reason the radiographic study is limited, this should be clearly stated in a disclaimer. For example, 'The owner refused to allow sedation and therefore the examination of the foot is incomplete'; or, 'The study is compromised by the presence of shoes which could not be removed due to permission being refused'. In extensive reports it is useful to finish with a clear summary of significant findings relevant to the potential use of the horse if purchased.

### **Records and labelling**

Radiographic images and reports are part of medical records, and should be stored carefully with patient records. In the United States both radiographs and radiographic reports must be kept for legal reasons for a minimum of 7 years, and this is a good principle to apply. The quality of the films/images will reflect on the quality of the practice, and this becomes particularly important when films may be viewed by other practitioners, for example in a pre-purchase examination. All films and digital images should be clearly identified with permanent labels at the time of acquisition.

With the increasing use of radiography, and the rise in litigation involving veterinarians worldwide, it is essential that radiographs are carefully labelled. This should be done digitally or photographically on the film, either by the use of one of the special tapes produced for this purpose, attached to

the cassette when the film is exposed, or by a labelling light-box system in the darkroom. Labels should include as a minimum:

- 1 The identity of the horse and owner.
- 2 The limb radiographed.
- 3 The date.
- 4 Lateral or medial markers where relevant should be placed on the cassette.
- 5 The identity of the veterinary practice.
- 6 The view employed (assuming this cannot be determined from the radiograph).

Digital systems may produce such labelling automatically, and the technician acquiring the images should ensure that correct information is recorded.

It is essential that a complete examination is carried out, with an adequate number of views of each area involved. The exposures must be correct to demonstrate any lesions present, the radiographs must be of diagnostic quality, and images should include all of the area being examined (e.g. images of hock joints frequently miss the proximal aspect of the calcaneus, or the tarsometatarsal joint). An inadequate examination may be at best inconclusive and at worst totally misleading. Such examinations in the hands of the legal profession may prove devastating!

## PRINCIPLES OF RADIOGRAPHIC INTERPRETATION: RADIOLOGY

It is important to read radiographic films when they are dry. The emulsion swells when wet and detail cannot be appreciated on wet films.

It is helpful if radiographs are always viewed using the same orientation, i.e. with the horse facing to the viewer's left, medial on the left, and when appropriate the left side on the right. This aids interpretation, as only one image need be remembered for each area radiographed. (This varies slightly from the convention that any film should be viewed as if the examiner was looking at the patient face on, e.g. the left forelimb is viewed with medial to the left, and the right forelimb with medial to the right.) The number of views required for any area varies, and is mentioned in the text. It is important to obtain an adequate number of views to ensure that no lesion is missed, and an attempt to compromise with fewer views is a false economy. The use of 'special' views, e.g. oblique and 'skyline' views, of suspected lesions can be very rewarding.

Adequate radiological interpretation is dependent on complete and systematic evaluation of all of the information that is found on the image. Films should be viewed on a viewing box, in a room with subdued light. This optimises the ability of the reader to differentiate structures and to obtain the maximum information from a film. The darker the film, the more important it becomes that the conditions under which it is read are ideal.

Initially the film should be evaluated from a distance of several feet before viewing closely, in order to get an overall impression before concentrating on details. Areas of diffuse, subtle change in radiopacity are usually more readily identified from a distance than close up. Masking the light around the edge of the radiograph also improves the ability to read a film, as do high-intensity illumination devices.

Digital images should be viewed on high-definition flat screens, again in a room with subdued light. As with film, it is helpful to mask the image to remove light areas around the point of interest. In many systems it is then possible to select the area of most relevance, and to adjust contrast and brightness of the region concerned to aid evaluation of a wide range of tissue densities. Most systems also allow for enlargement of the whole image, or of specific regions of interest (see Chapter 2).

With film or digital images, start by assessing the image itself:

- Is the quality of the image adequate for interpretation?
- Is the view correctly positioned to allow correct interpretation?
- Are there any processing or other artefacts (e.g. mud on the horse) that will influence interpretation?

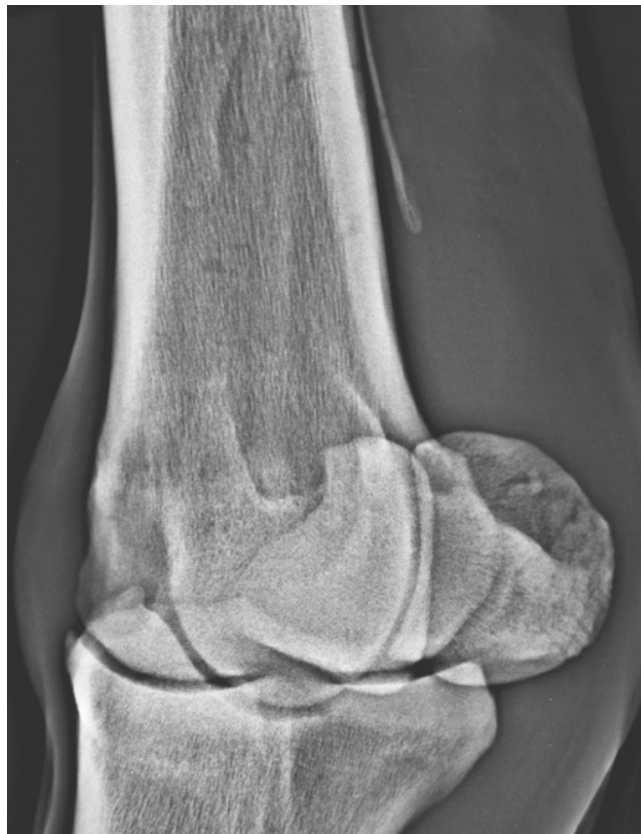Then move on to assess the area radiographed:

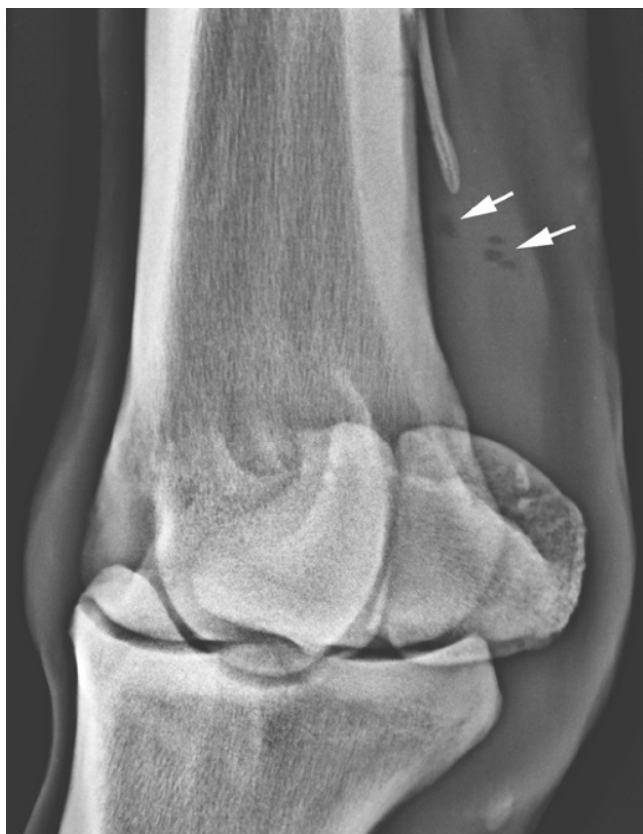- Is there any soft-tissue swelling?
- Is there any alteration of opacity of the soft tissues?
- What is the approximate age of the patient?

Finally look at the outline of the bones and their detailed internal structure:

- If an 'abnormality' is identified, ensure that it is real – can it be seen on another view? Can it be explained by positioning or overlap of other bones or soft-tissue structures? Is it a variation rather than an abnormality, e.g. the position and shape of a nutrient foramen can vary considerably. Could a radiolucent zone be explained by introduction of air during a previously performed local analgesic technique (Figure 1.13a and b). Intra-articular gas appears as a semicircular or more diffuse radiolucent area, often in the proximal

**Figure 1.13(a)** Dorsolateral-palmaromedial oblique image of the distal metacarpal region and metacarpophalangeal joint of a mature horse. There are radiolucent areas superimposed over the third metacarpal bone. These gas shadows are the result of inadvertent introduction of air into the metacarpophalangeal joint while performing intra-articular analgesia. Such lucent areas may persist for up to 48 hours. Note also the periarticular osteophyte formation on the dorsoproximal medial aspect of the proximal phalanx consistent with degenerative joint disease. There are also multiple radiolucent lines in the lateral proximal sesamoid bone.





**Figure 1.13(b)** Dorsomedial-palmarolateral oblique image of the same limb as Figure 1.13(a). There are discrete radiolucent areas (arrows) in the soft tissues distal to the distal aspect of the second metacarpal bone representing air in the palmar recess of the metacarpophalangeal joint.

part of a joint, whereas extra-articular gas appears as a linear radiolucency. These lucencies may persist for up to 48 hours after injection

- Would additional views aid or complete adequate evaluation?
- If it is a true radiographic lesion, describe it in radiological terms.

In this process of description it is often possible to determine if it is an active or inactive process. In general, terms like smooth, regular and well marginated (defined) lead towards a conclusion of normal, benign or long-standing lesions. Terms such as roughened, irregular, sharp, poorly demarcated or destructive, lead to a conclusion of active disease. If the process is considered to be pathological, then think what pathological process could cause this change and then consider what diseases could cause this type of pathology.

If images are obtained to confirm the presence of a specific disease or disease process and are not completely evaluated, the severity of the condition, complications of the process or other concurrent lesions may be overlooked. Thus to read radiographs successfully, it is important to relate the changes seen to known behaviour of the tissues under consideration, rather than relating the radiographic appearance to a clinical condition seen before. The latter method relies heavily on experience and does not allow interpretation of changes that have not been previously encountered. It is important to remember that each radiograph can only represent a fraction of a second in the life of the patient, and the development of a disease process. It is a static image of a dynamic process. When a radiograph is read, all the changes from the normal should be considered and used to build up an impression that can then be related to disease processes known to occur in the region.

For accurate interpretation it is important to take into account factors such as the period of time for which the clinical signs have been present, the age, sex and breed of the patient, and the validity of the history and possible complicating factors. A working diagnosis can then be formed, which will complement any laboratory findings and other imaging techniques, and help to confirm a clinical diagnosis. There is no substitute for a good clinical history and examination, and radiographs should only be used as an aid to the clinical diagnosis.

It is beneficial to have bone specimens available when reading radiographs, particularly oblique images. An anatomy book and a library of normal radiographs of each anatomical area at different ages are invaluable. If problems are encountered in evaluating an area, it is often helpful to obtain a similar radiograph of the contralateral limb for comparison, thus providing a perfect age-, sex- and breed-matched radiograph. Remember that, in the neonate, some structures are not ossified and therefore cannot be seen. More confusing is the appearance of partially ossified structures (e.g. incompletely ossified subchondral tissues have an irregular opacity, which may seem similar to the radiographic appearance of infection). The normal radiographic appearance of the structures of immature animals is therefore described in each chapter. Digital images are easily transferred electronically, therefore it is always easy to get the advice of an expert if there are queries concerning interpretation.

Radiographs are only one part of a jigsaw puzzle and may be used for several purposes:

- To confirm, refute or suggest a diagnosis
- To give information on progression and severity of a condition, and aid formation of a prognosis
- To add information regarding size, shape, position, alignment and possibly duration of a lesion.

When reading a radiograph the result must be fitted into the general picture presented to the clinician. It is one aid to diagnosis that the clinician has available. In some cases special views or contrast studies may provide valuable additional information. There are many other complementary imaging techniques (e.g. ultrasonography, nuclear scintigraphy, computed tomography and magnetic resonance imaging) and other sources of clinical information that are available. The radiograph is an aid to diagnosis and not the ultimate diagnosis in itself.

One of the most difficult questions to answer is how long a lesion has been present. This is often of importance, but can seldom be answered with any degree of certainty. Minimum times for certain lesions to develop can be estimated, but the time for which a lesion has been present often remains uncertain. The following pointers may be of value:

- Osteophyte formation of any type is not normally visible, even under optimum conditions, in less than 3 weeks
- Treatment after injury may delay osteophyte formation
- Incomplete or fissure fractures may take up to 2 weeks to become visible
- Active bone changes are characterised by lesions with irregular or fuzzy margins, which may be less opaque than the parent bone
- Inactive bone changes are generally smooth, regular and uniformly opaque