

The Dental Reference Manual

A Daily Guide for
Students and Practitioners

Geraldine M. Weinstein
Mitchell T. Zientz
Editors

 Springer

The Dental Reference Manual

Geraldine M. Weinstein • Mitchell T. Zientz
Editors

The Dental Reference Manual

A Daily Guide for Students
and Practitioners

 Springer

Editors

Geraldine M. Weinstein
University of Connecticut
School of Dental Medicine
Farmington
CT
USA

Mitchell T. Zientz
Wellspring Dental
Brooklyn
New York
USA

ISBN 978-3-319-39728-3

ISBN 978-3-319-39730-6 (eBook)

DOI 10.1007/978-3-319-39730-6

Library of Congress Control Number: 2016958298

© Springer International Publishing Switzerland 2017

This work is subject to copyright. All rights are reserved by the Publisher, whether the whole or part of the material is concerned, specifically the rights of translation, reprinting, reuse of illustrations, recitation, broadcasting, reproduction on microfilms or in any other physical way, and transmission or information storage and retrieval, electronic adaptation, computer software, or by similar or dissimilar methodology now known or hereafter developed.

The use of general descriptive names, registered names, trademarks, service marks, etc. in this publication does not imply, even in the absence of a specific statement, that such names are exempt from the relevant protective laws and regulations and therefore free for general use.

The publisher, the authors and the editors are safe to assume that the advice and information in this book are believed to be true and accurate at the date of publication. Neither the publisher nor the authors or the editors give a warranty, express or implied, with respect to the material contained herein or for any errors or omissions that may have been made.

Printed on acid-free paper

This Springer imprint is published by Springer Nature
The registered company is Springer International Publishing AG Switzerland

Preface

What Are the Benefits for the Student and/or Practitioner?

This is a succinct and truncated reference manual for the young dentist.

It will serve as an accessible means to quickly find answers to common dental questions.

It is a reference aid with an educational delivery designed for the student (both in school and in practice).

The aim is for the student to keep it handy.

It is a study guide of sorts including the particulars that should be second nature for every dentist.

It allows the new student to look ahead at the big picture and begin familiarizing with topics to come.

It allows the practicing dentist a daily reference of common and important materials/topics/techniques/conditions.

In academia, inspiration can come from the very students who you work with on a daily basis. The idea for this book was born from a dental student, Mitch Zientz, who wanted to capture the most important aspects of his clinical education. His original idea was to author each chapter on his own. A herculean task that I ultimately discouraged. Instead, we developed the idea and searched for experts in the field, mostly educators to document their evidence-based teachings. The chapters are a collective work from authors across different disciplines. The dental reference manual exhibits the necessities for the practice of general dentistry. It exemplifies answers to the most haunting questions that we stumble upon on a daily basis. We hope that it is a useful tool for all our young dental practitioners.

Our deepest gratitude to all the authors in this book who helped make the dream a reality! We hope with this collection of works to inspire the new practitioner to learn, grow, and most importantly do what is right for their patients. Dentistry is a lifelong journey of learning; never cease to ask questions!

Farmington, CT, USA
Brooklyn, NY, USA

Geraldine M. Weinstein
Mitchell T. Zientz

Contents

Part I Essentials of Dental Practice

1 Comprehensive Head and Neck Exam	3
Rosalia Rey, Nereyda Clark, and Pamela Sandow	
2 Dental Radiology	21
Rujuta Katkar	
3 Caries Risk Assessment, Remineralizing, and Desensitizing Strategies in Preventive-Restorative Dentistry	39
Saulo Geraldeli and Alex J. Delgado	
4 Local Anesthesia Challenges	53
Sidni Paige Manne and Rosalia Rey	
5 Modern Day Treatment Planning Dilemmas; Natural Tooth Versus Implants	61
Sharon C. Siegel, John R. Antonelli, and Mauricio Hervas	
6 Restorative Considerations for Endodontically Treated Teeth	83
John R. Antonelli	
7 Fixed Restorative Materials	115
Mauricio Castellanos and Alex Delgado	
8 Removable Partial Dentures (RPD) Treatment: A Clinical Guide	129
Mauricio Castellanos and Luisa F. Echeto	
9 Introduction to Occlusion	147
Margarete C. Ribeiro-Dasilva, James Nguyen, Keith Kiskaddon, and Peter E. Dawson	
10 Indirect Restorations with CAD/CAM Technology	161
Geraldine Weinstein, W. Stephen Howard, and Richard Fox	
11 Digital Impressions	177
Stefanie D. Seitz and Richard L. Zimmermann	

Part II The Specialties in General Dentistry

- | | | |
|-----------|---|-----|
| 12 | Endodontics for the General Practitioner | 185 |
| | Uma Nair | |
| 13 | Periodontics for the General Dental Practitioner | 197 |
| | Peter Harrison, Eugenia Monaghan, and Karin Schey | |
| 14 | Common Lesions in Oral Pathology for
the General Dentist | 227 |
| | Indraneel Bhattacharyya, Hardeep K. Chehal,
and Mohammed N. Islam | |
| 15 | Oral and Maxillofacial Surgery | 291 |
| | Stacey Nedrud and John Hardeman | |
| 16 | Pediatric Dentistry for the General Practitioners | 315 |
| | Dennis Bear, Maggie Wang, and Abimbola Adewumi | |
| 17 | Orthodontics | 343 |
| | Eddy J. Sedeño III, Melissa Alfonso, and Calogero Dolce | |
| 18 | Implants for the General Practitioner | 373 |
| | Mitch Zientz, Geraldine Weinstein, and Luiz Gonzaga DMD | |

Part III References for Everyday Practice

- | | | |
|-----------|--|-----|
| 19 | The Examination, Differential Diagnosis, and Management
of Toothache Pain | 391 |
| | Christopher J. Spencer | |
| 20 | Communicating with Dental Laboratories | 409 |
| | Tamra Culp and Lee Culp | |
| 21 | Navigating Evidence-Based Dentistry | 427 |
| | Jaana Autio-Gold and Scott Tomar | |
| 22 | Common Dental Prescriptions | 433 |
| | Geraldine Weinstein and Fong Wong | |
| 23 | Medical Considerations and Emergency Protocols | 445 |
| | Mary Kuhns and Christopher Kuhns | |

Part IV Pathways of a Dental Career

- | | | |
|-----------|--|-----|
| 24 | Private Practice | 467 |
| | Annelise Ydstebo Driscoll | |
| 25 | The President's Dentist | 483 |
| | Boyd Robinson | |

26	On Building a Dental School	487
	Margaret B. Wilson	
27	In Pursuit of Dentistry from Zimbabwe!	507
	Criswell Tafadzwa Gandhi	
	Index	515

Part I

Essentials of Dental Practice

Rosalia Rey, Nereyda Clark, and Pamela Sandow

Contents

1.1 The Interview of the Patient Is Critical to Identify High Risk Factors	3
1.2 Extraoral Exam	4
1.3 Intraoral Exam	11
1.4 How to Record Findings	18
References.....	20

Abstract

An exam of the head and neck region is essential for every patient that we encounter as dentists. When done in a systematic and efficient way, it should only take a few minutes of time. The key to performing this exam is noting asymmetries and determining if pathology is involved.

1.1 The Interview of the Patient Is Critical to Identify High Risk Factors

- *Smoking history* – Document the pack-years; multiply the number of packs of cigarettes smoked per day by the number of years the patient has smoked (National Cancer Institute).

R. Rey, DMD • N. Clark, DMD
Restorative Dental Sciences, University of Florida, College of Dentistry,
Gainesville, FL, USA

P. Sandow, DMD (✉)
Oral Medicine, University of Florida, College of Dentistry, Gainesville, FL, USA
e-mail: PSANDOW@dental.ufl.edu

- *Other tobacco use.*
- *Alcohol and drug use* – Document amount of use ([National Institute on Alcohol Abuse and Alcoholism](#)).
- *Poor diet.*
- *Human papillomavirus (HPV) history* – See Chap. 14, for more information. ([Oral Cancer Foundation](#)).
- *Sun exposure.*
- *Reported changes in the voice, skin, or mouth.*

1.2 Extraoral Exam

- *Head, neck, face, skin, and hairline* (Fig.1.1)
 - Standing in front of the patient, visually inspect the face.
 - Look for symmetry; color, pigmentation, contour, consistency, and function.
- *Forehead and eyes*
 - Palpate the forehead. Look for nodules, swellings, and masses (Fig.1.2).
- *Cranial nerves and facial muscles*

Fig. 1.1 Forehead and hairline (Photos courtesy of Anna Christine Napoli and Dr. Karin Schey)

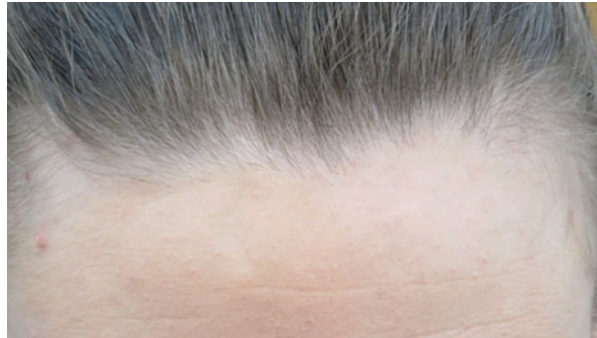

Fig. 1.2 Palpation is a quick way to examine a patient for asymmetries

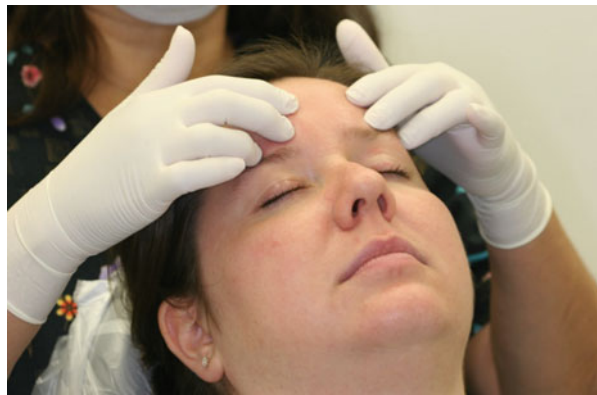

Fig. 1.3 The patient should follow finger movements with the eyes, while not moving the head. Movement of the eye is controlled by the oculomotor, trochlear, and abducens nerves

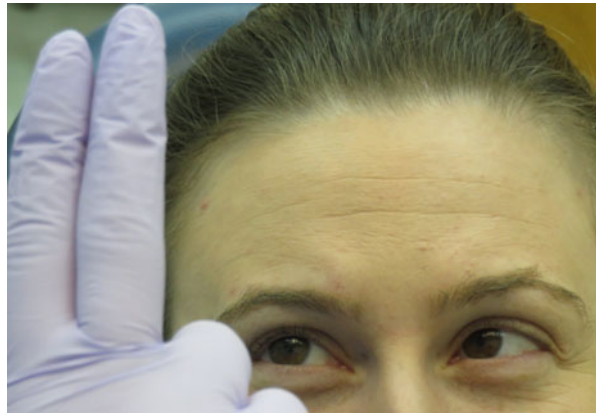
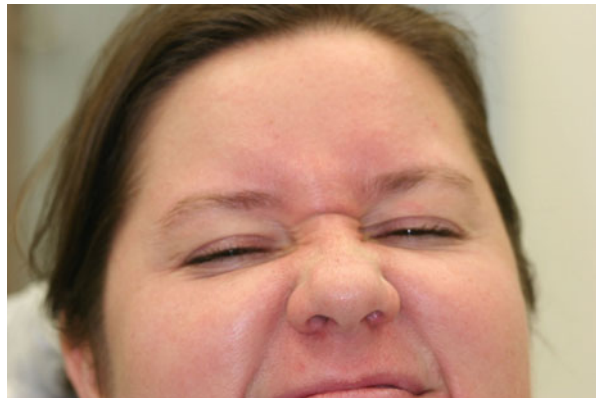
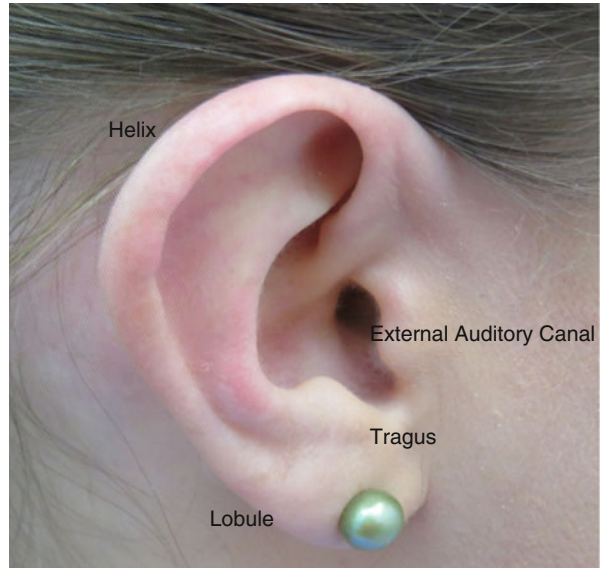
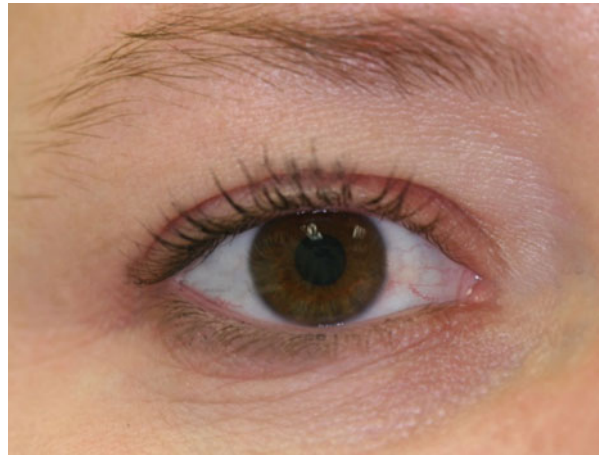
Fig. 1.4 Squinting may detect facial nerve symmetry (normal finding) or asymmetry (abnormal finding)



- Have patient follow your fingers in an H pattern. Assess possible deficiency in facial nerve function (Fig.1.3).
- Have patient squint, look for symmetry. Asymmetry during squinting could indicate facial muscle deficiency (Fig.1.4).
- *Ears*
 - Inspect and palpate all visible portions of the ear (Fig.1.5).
 - Look for color, pigmentation, contour, consistency, and function.
- *Eyes*
 - Inspect the eyes (Fig.1.6).
 - Look for white sclera, absence of swelling, or drainage.
 - Yellow sclera may suggest jaundice.
 - Hematoma could indicate a bleeding disorder or injury.
- *Nose*
 - Look up the nares (nostrils) and palpate the nose (Fig.1.7).
 - Look for nodules, swellings, and masses.
- *TMJ*
 - Sitting or standing behind the patient, visually inspect the face. Look for symmetry in function. Note any abnormal deviation of the mandible.

Fig. 1.5 Outer ear**Fig. 1.6** Check the eyes for sclera coloring, drainage, or swelling

- Palpate the temporomandibular joint (TMJ) while having patient open and close with fingers placed over the condyles, bilaterally. Note clicking, popping, and discomfort/pain (Fig.1.8).
- Look for nodules, swellings, and/or masses.
- *Parotid gland and preauricular nodes*
 - Feel the parotid bilaterally and the preauricular nodes (Fig.1.9).
 - Compare for symmetry, identify nodes by size and if they are hard or soft, painful or painless, and freely movable or fixed.
 - Possible findings: Lymph nodes may have nodules, swelling, and/or masses.

Fig. 1.7 Lack of symmetry of the nose should be noted when performing esthetic dental procedures as it may be critical when determining facial midlines

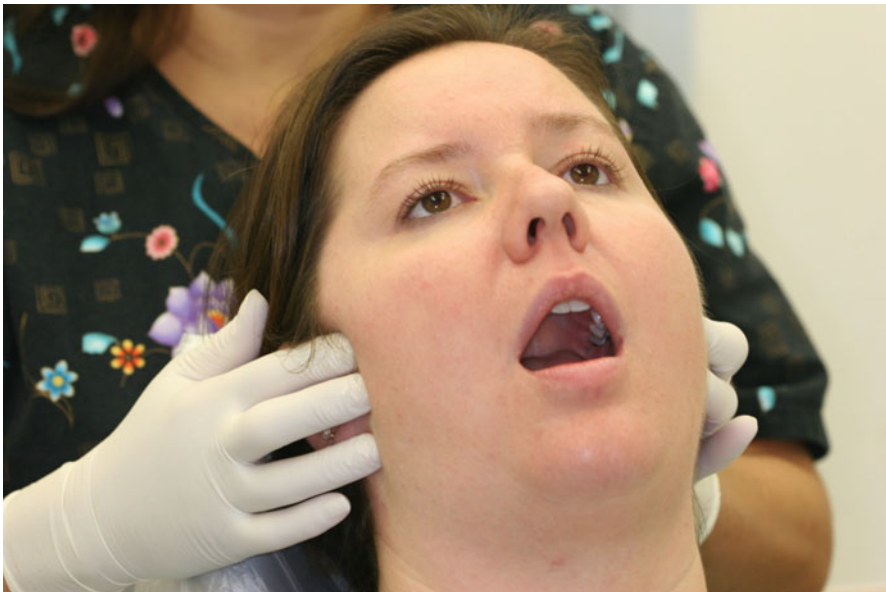
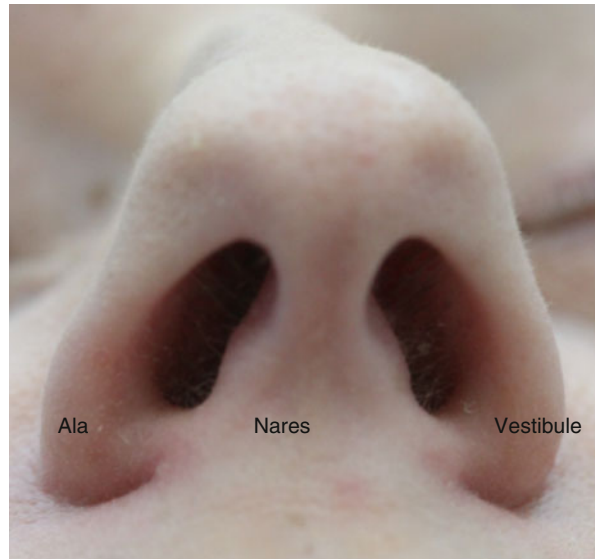


Fig. 1.8 If TMJ symptoms are present, a more extensive evaluation will be necessary

- *Posterior neck nodes*
 - To palpate the posterior auricular and occipital nodes, drop head forward to enhance access to these areas.
 - Palpate over the trapezius muscle for the spinal accessory and posterior cervical nodes (Fig. 1.10a, b).

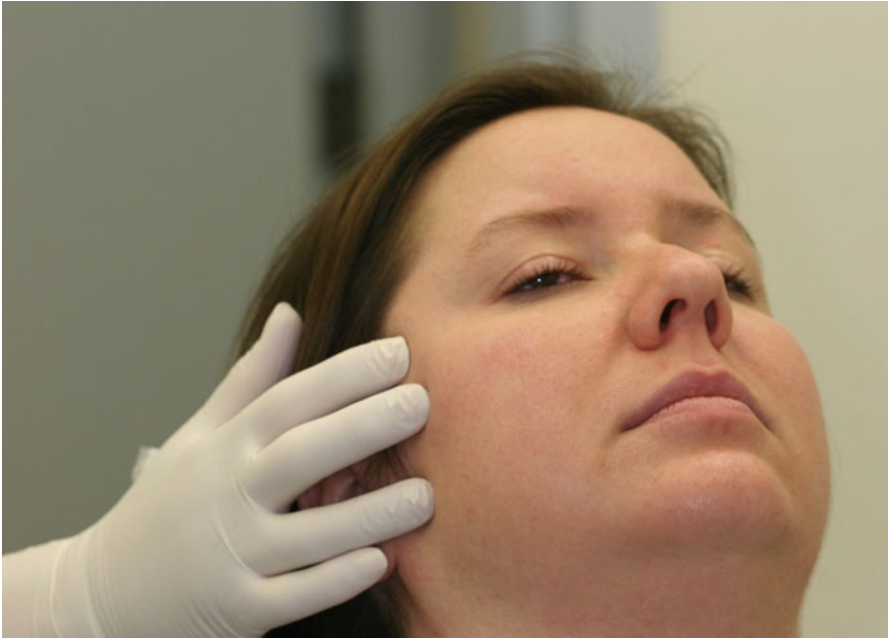

Fig. 1.9 Bilateral palpation of the parotid gland and preauricular area

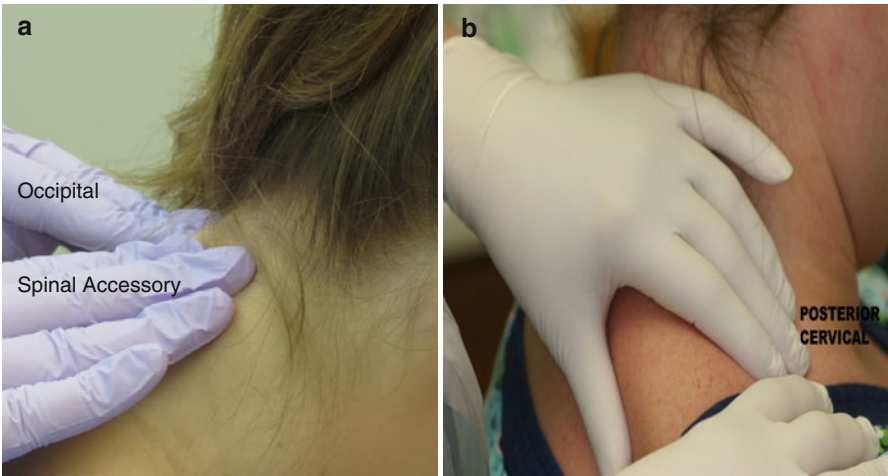
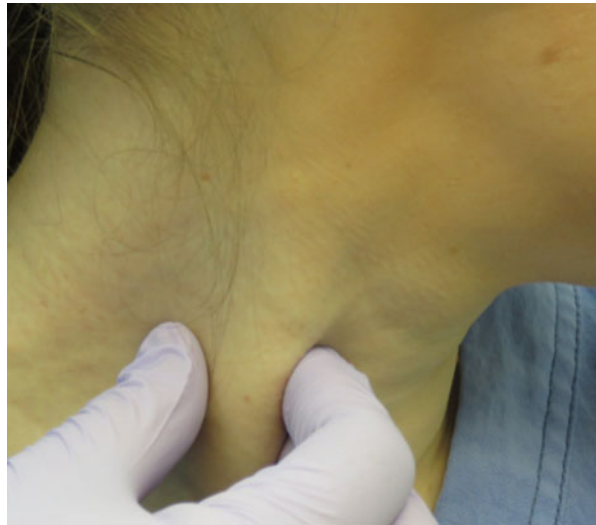

Fig. 1.10 (a, b) Tenderness to palpation should also be noted

Fig. 1.11 Jugular lymph node enlargement along the sternocleidomastoid is common in patients experiencing the common cold or with head and neck cancer (Photo Courtesy of Dr. Eugenia Monaghan)



- Compare for symmetry and identify nodes for size, consistency (hard or soft), level of pain, or if freely movable or fixed.
- *Anterior neck nodes*
 - Palpate the jugular chain, deep and superficial cervical nodes, by placing fingers firmly on both sides of the sternocleidomastoid muscle from its origin at the clavicle to its insertion at the mastoid process behind the ear (Fig. 1.11).
 - Palpate the supraclavicular, anterior scalene, and delphian nodes above the clavicles and near the inferior midline of the neck.
 - Compare for symmetry and identify nodes for size, consistency (hard or soft), level of pain, or if freely movable or fixed.
- *Thyroid gland and larynx*
 - Visually inspect and bimanually palpate the thyroid. Compare both lobes for symmetry.
 - Normally, the thyroid gland is difficult to palpate.
 - Palpate the larynx while the patient swallows (Fig. 1.12).
 - Inspect for enlargement or mobility. Listen for hoarseness.
- *Submandibular neck nodes*
 - To palpate the submandibular and submental nodes have the patient lower the chin and manually palpate directly underneath the chin and the medial side of the mandible (Fig.1.13).
 - Grasp and roll the tissue over the bony edge of the mandible, anteriorly and bilaterally.

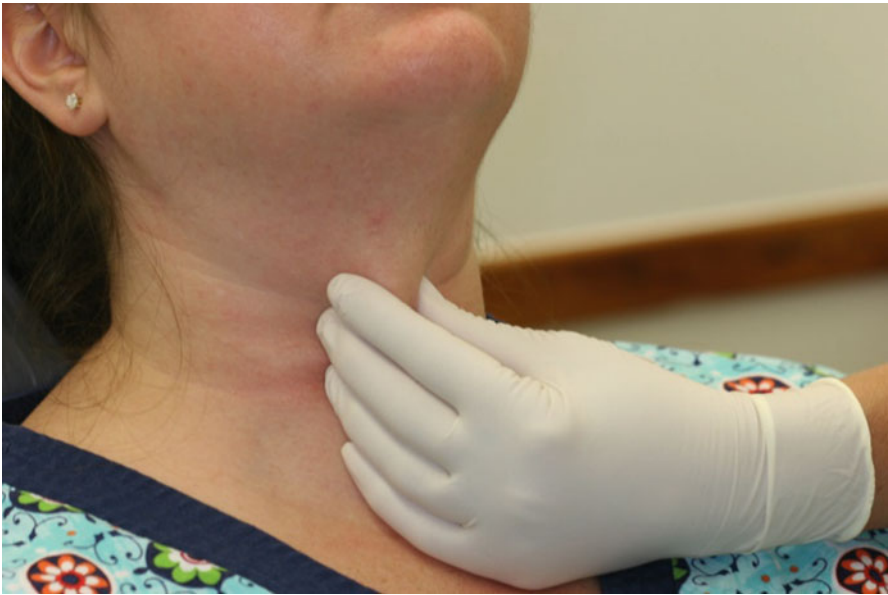

Fig. 1.12 Inquire if patient has any difficulty swallowing

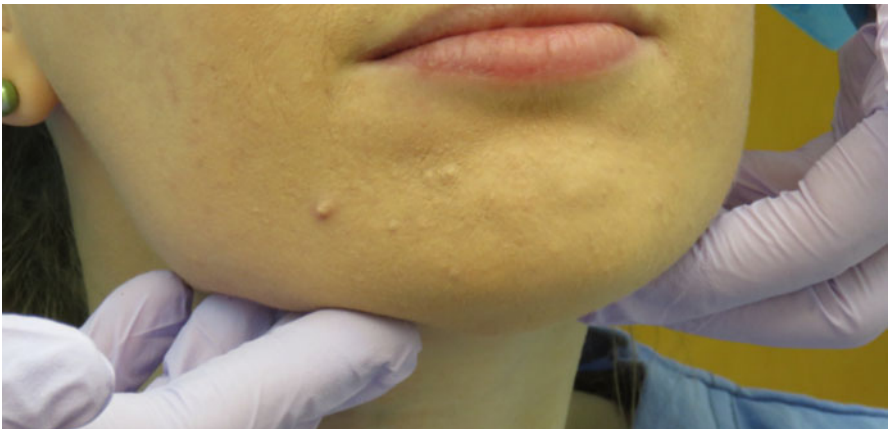

Fig. 1.13 Insure that palpation of soft tissue is done against the hard, bony surface of the mandible

1.3 Intraoral Exam

- *Gloves*
 - Remove soiled gloves and replace with clean latex-free gloves.
- *Lips*
 - Evaluate closed and open.
 - Visualize vermilion border, commissures, and mucosa. The border should be uniform and pink with no cracking or ulcerations at the commissures (Fig. 1.14).
 - Palpate bilaterally and bi-digitally between the thumb and fingers from one commissure to the other in the lower lip (Fig. 1.15a).
 - Use the same technique for the upper lip (Fig. 1.15b).
 - Submucosal lumps (minor salivary glands) should be small and uniform in size.

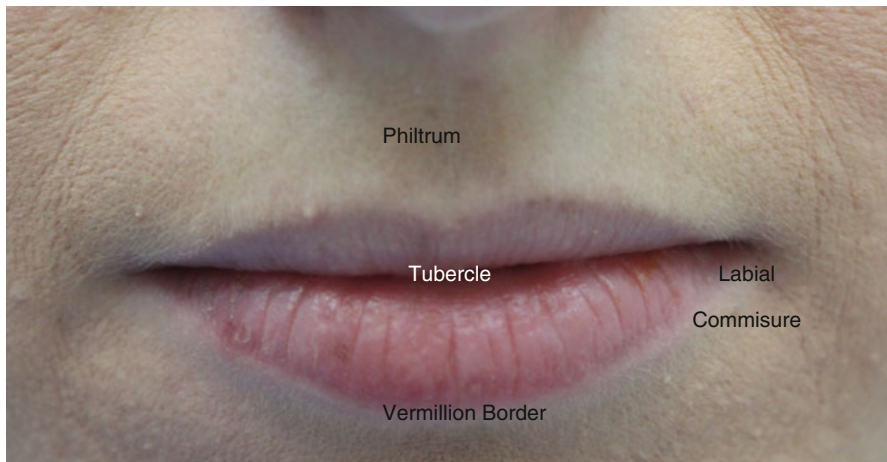


Fig. 1.14 The vermilion border

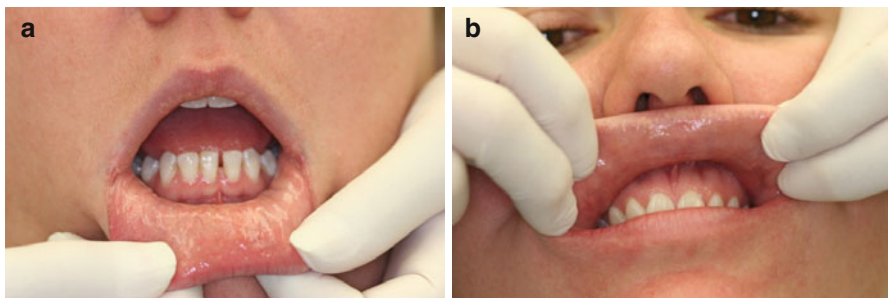


Fig. 1.15 (a, b) Palpating and visualizing the lips

Fig. 1.16 The linea alba may be more pronounced in pigmented gingiva or people who chew their cheeks

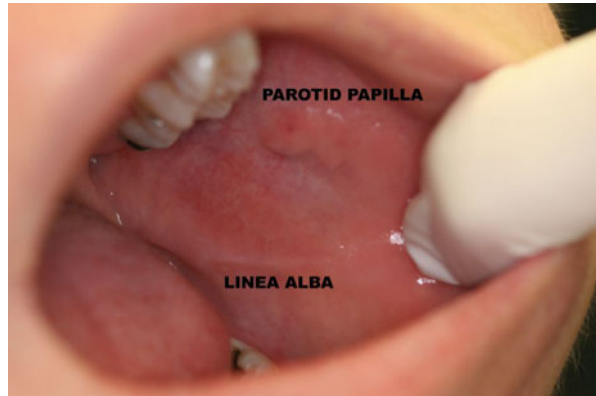
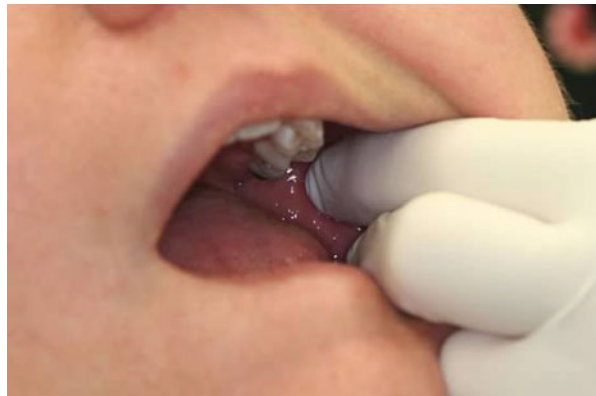
Fig. 1.17 Thorough medical history review will help determine if lesions are traumatic or pathologic



- *Buccal mucosa*
 - Retract the buccal mucosal tissue and visualize, while the mouth is in a relaxed open position.
 - Linea alba (white line) at the mid-buccal mucosa is a normal finding (Fig.1.16).
 - If the tissue appears white and disappears when stretched, it may indicate leukoedema (see Chap. 14).
 - White lacy lines on the buccal mucosa could be a sign of lichen planus or lichenoid drug reaction (see Chap. 14).
- *Parotid gland*
 - Bi-digitally palpate the buccal mucosa and parotid gland, comparing both sides for symmetry (Fig.1.17).
 - A malignancy is usually red or red/white in color and indurated (hard).
- *Alveolar ridges*
 - Visually inspect the vestibular area and alveolar ridges (Fig. 1.18).
 - Assess the color, contour, consistency, and function.
- *Buccal gingiva*
 - With an index finger, palpate the buccal and labial surfaces of the alveolar ridges and vestibules (Fig. 1.19).

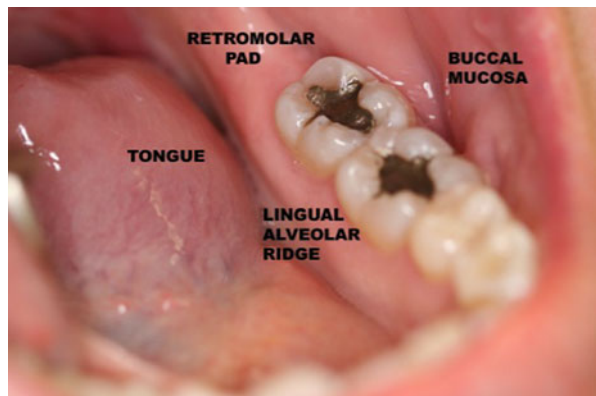
Fig. 1.18 When a lesion is found along the alveolar ridges, endodontic testing and radiographs will help determine if the lesion may be due to tooth pathology as opposed to a soft tissue lesion. (see Chaps. 12 and 14)

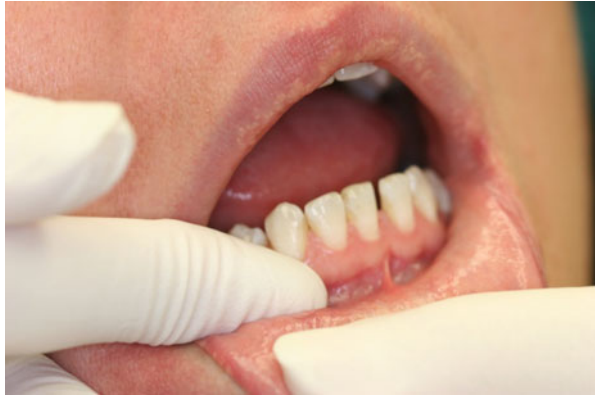

Fig. 1.19 Note tori, if present, as this may impact future restorative treatment

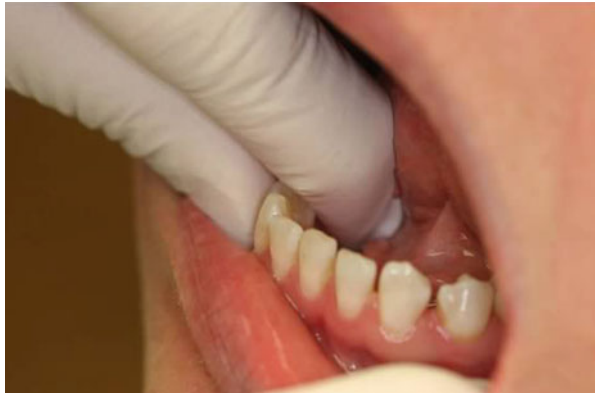

Fig. 1.20 It is important to perform a quick visual inspection of the patient at every dental visit



- *Lingual gingiva*
 - Inspect and palpate the lingual surfaces of the mandible.
 - Amalgam tattoos are common findings found near large fillings or root canals, even after teeth are extracted.

Fig. 1.21 Note palatal torus as this may impact future restorative treatment

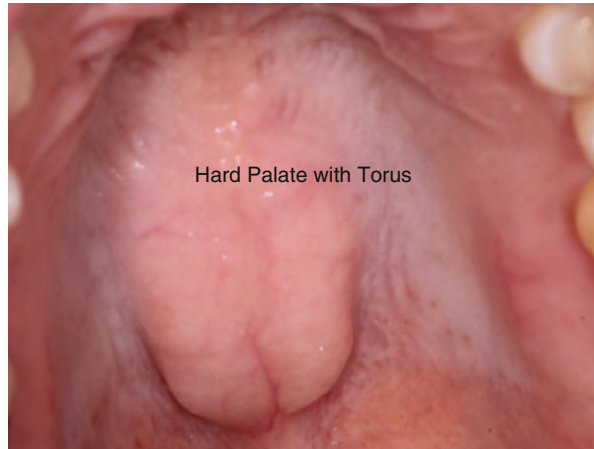
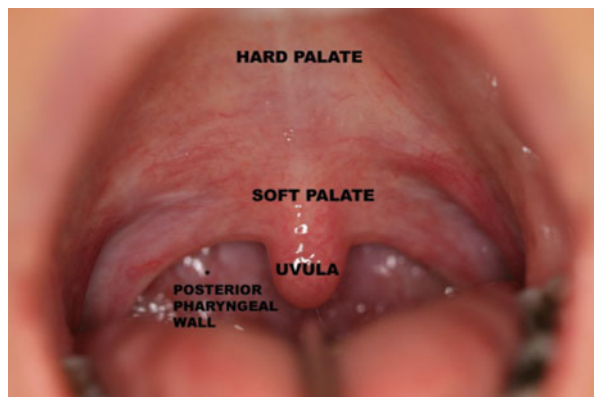


Fig. 1.22 The oropharyngeal area should be inspected as part of the head and neck exam



- Inspect for bone loss/mobility associated with one tooth that is not consistent with the rest of the oral cavity as it could indicate underlying pathology or malignancy.
- Inspect for unilateral enlargement of the bone as this may be a sign of an odontogenic cyst or tumor, as opposed to tori which are usually bilateral (Fig.1.20).
- *Hard palate*
 - Visually inspect and palpate the hard palate (Fig.1.21).
 - Inspect for irregularities in coloration, ulcerations, and/or asymmetrical sub-mucosal masses.
- *Soft palate and uvula*
 - Have the patient open wide and visually inspect the soft palate and uvula.
 - Inspect for discolorations, changes in mucosal texture, swelling, asymmetrical enlargement of tonsils, ulcerations, growths, masses, bleeding, and/or pain.
- *Tonsillar pillars*
 - With gentle pressure place the mouth mirror on the middle of the tongue and ask the patient to say “ahhhh” while relaxing the tongue (Fig.1.22).

Fig. 1.23 Symmetric mobility of the uvula should be observed when a patient says “ahh”

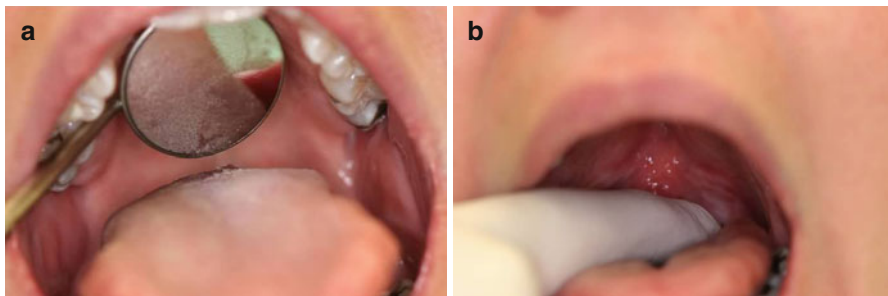
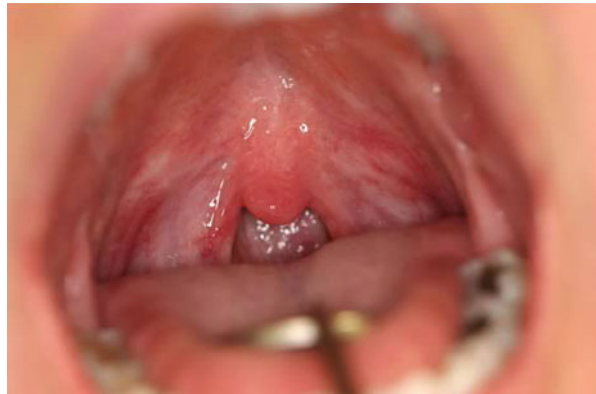

Fig. 1.24 (a, b) Visualize and palpate the tongue posterior to the circumvallate papillae

- A unilateral earache can be a sign of oropharyngeal carcinoma or lymphoma (American Cancer Society).
- *Pharynx and portions of the oropharynx*
 - Visually inspect the uvula and the visible portions of the pharynx including the tonsils (Fig. 1.23).
- *Posterior tongue*
 - Protrude the tongue and visualize the posterior tongue, posterior to the circumvallate papillae, with the mouth mirror (Fig. 1.24a, b).
 - Also, if possible, palpate posterior to the circumvallate papillae with a sweep of the finger.
 - Inspect for discolorations, changes in mucosal texture, swelling, asymmetrical enlargement of tonsils, ulcerations, growths, masses, bleeding, and/or pain.
 - Upon protrusion observe if the tongue is symmetrical or deviates to one side.
- *Lateral surface of the tongue*
 - Have the patient gently extend the tongue and wrap a gauze square around the anterior third of the tongue in order to obtain a firm grasp (Fig. 1.25).
 - Inspect for discolorations, changes in mucosal texture, swelling, asymmetrical enlargement of tonsils, ulcerations, growths, masses, bleeding, and/or pain.
 - Turn the tongue slightly on its side.

Fig. 1.25 Use of gauze allows the tongue to be examined without slipping

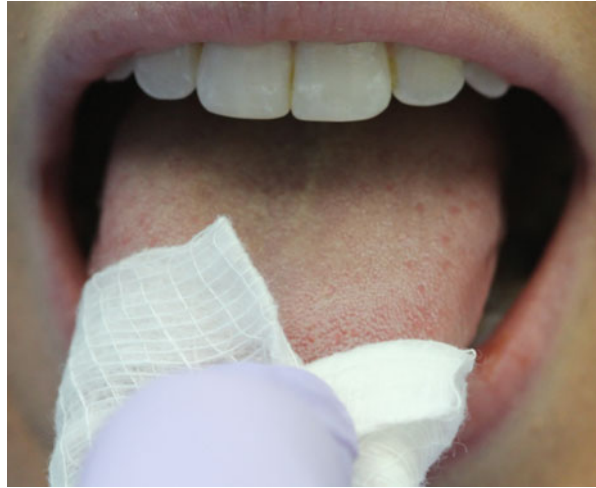
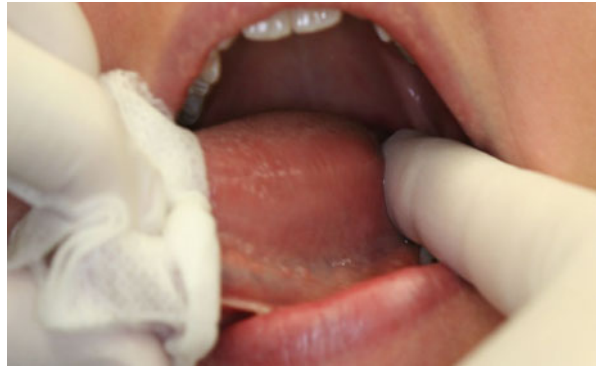
Fig. 1.26 Visualize and palpate the lateral surfaces of the tongue



- Visually inspect and digitally palpate its base and lateral borders (Fig.1.26).
- *Dorsal tongue*
 - Bi-digitally palpate the dorsal surface (Fig.1.27).
 - Foliate papillae are a normal finding along the posterior lateral border of the tongue, bilaterally.
 - Inspect for asymmetry and palpate for masses.
- *Ventral tongue and floor of the mouth*
 - While the patient lifts the tongue to the palate, visually inspect the mucosa of the ventral tongue and floor of the mouth (Fig.1.28).
 - Use the mouth mirror to assist in lighting.
- *Submandibular and sublingual salivary glands*
 - Palpate the sublingual region by placing one index finger intraorally and the fingertips of the opposite hand under the chin, compressing the tissue between the fingers (Fig.1.29).
 - Check for symmetry.

Fig. 1.27 Use fingers on both sides of the tongue to detect masses

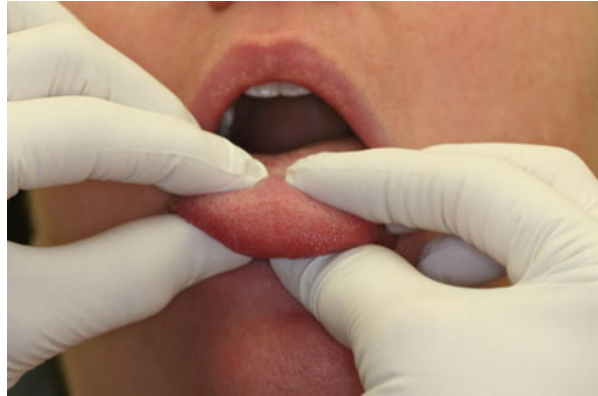

Fig. 1.28 Inspect the floor of the mouth. Normal findings like tori or unusual lingual frenum attachments should be noted as it may affect future restorative decisions

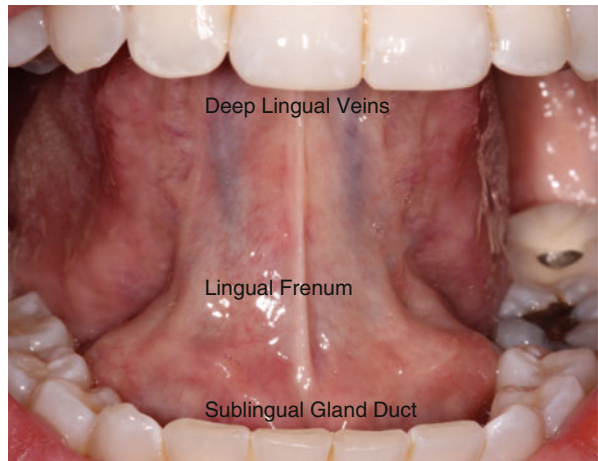
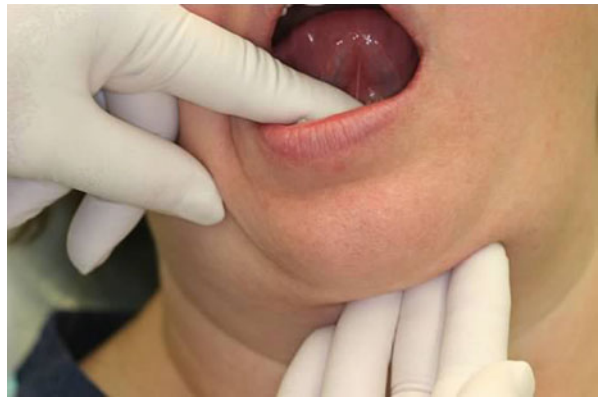

Fig. 1.29 Palpate using index fingers intraorally and in the submental region. Use the hard surface of the mandible to assist in compressing the tissue



1.4 How to Record Findings

A practice should have a standardized form to record all head and neck findings. This should be done at the initial visit when the patient first presents for a comprehensive exam and updated on a yearly basis. Proper referrals to other specialists should be noted if pathology exists. Below is an example of a form that can be utilized (Figs. 1.30a, b and 1.31). More details on oral cancer screenings can be found on the Oral Cancer Foundation website, ISSN: <http://www.oralcancerfoundation.org/discovery-diagnosis/screening.php>.

a Head and Neck Screening Exam Finding Control # _____

First Name _____ Last Name _____ DOB _____ / _____ / _____ SCREENING EXAM: by _____

Site	Normal	Abnor.	Photo	Descriptors			Diagram
				Color # of lesions Size	Shape Surface Growth, Attachment	Consistency Length of Time Pain	
Forehead							
Eyes							
Nose							
Lower Face							
Facial Muscles							
Cranial Nerves							
TMJ							
Auricular/Parotid Nodes							
External Ears							
Post Neck Nodes							
Ant Neck Nodes							
Thyroid Larynx							
Submandibular/Mental Nodes							
Lips							
<p>Location: Anatomical location and Symmetry Unilateral, Bilateral, Symmetrical, Midline, Right, Left</p> <p># of lesions: Single Few Multiple, Generalize</p> <p>Size: in millimeters</p> <p>Color: White, Red, Red and White, Fluid Filled Vesicle, Blue, Black, Pigmented</p> <p>Overall Configuration: Raised (nodular) Flat (macular)</p> <p>Shape: Round, Oval, Irregular Borders, Assymetrical</p> <p>Surface: Smooth, Rough, Ulcerated, Hyperkeratotic, Scaly, Crusty, Oozing, Bleeding, Dry</p> <p>Attachment: Sessile/broad - Fixed Base Pedunculated-narrow stalk</p> <p>Consistency: Hard Soft indurated Non-indurated (esp if ulcerated)</p> <p>Growth: Endophytic, Exophytic, Compressible Blanches, Swelling</p>							

Fig. 1.30 (a, b) Screening forms insure that a proper exam is done for each patient

b

Head and Neck Screening Exam Finding Control # _____

First Name _____ Last Name _____ DOB / / SCREENING EXAM: by _____

Site	Normal	Abnormal	Photogra	Descriptors			Diagram
				Color # of lesions Size	Shape Surface Growth, Attachment	Consistency Length of Time Pain	
Labial Mucosa							<div style="display: flex; justify-content: space-between;"> R L </div>
Buccal Mucosa							
Parotid Gland							
Max Gingiva B & L							
Mand Gingiva B & L							
Hard Palate							
Soft Palate							
Tonsils							
Oropharynx							
Tongue Dorsal							
Lateral Border							
Ventral							
Floor of Mouth							
Sublingual Gland							
<p>Location: Anatomical location and Symmetry Unilateral, Bilateral, Symmetrical, Midline, Right, Left</p> <p># of lesions: Single Few Multiple, Generalize</p> <p>Size: in millimeters</p> <p>Color: White, Red, Red and White, Fluid Filled Vesicle, Blue, Black, Pigmented</p> <p>Overall Configuration: Raised (nodular) Flat (macular)</p> <p>Shape/margins: Round, Oval, Irregular Borders, Assymetrical, Stripes/papules Wicken Striae</p> <p>Surface: Keratinized, Nonkeratinized, Smooth, Rough, Pebbly, Hyperplastic, Papillary/Verrucous, Ulcerated, Hyperkeratotic, Inflamed, Pseudoembranous, Scaly, Crusty, Oozing, Exudate, Bleeding, Dry</p>							<p>Attachment: Sessile/broad - Fixed Base Pedunculated-narrow stalk</p> <p>Consistency: Hard Soft Erythematous, Petechiae Indurated Non-indurated (esp if ulcerated)</p> <p>Growth: Endophytic, Exophytic, Compressible Blanches Swelling</p> <p>Length of time: not aware. aware < 2 weeks aware 3 months, aware > 3 months Has it happened before? Trauma Recurrent Medication Has it changed?</p> <p>Pain: On palpation? Unprovoked? yes no</p> <p>Tongue: Ankyloglossia, Macroglossia, Hairy, Fissured, Scrotal, Geographic, Papilla missing</p>

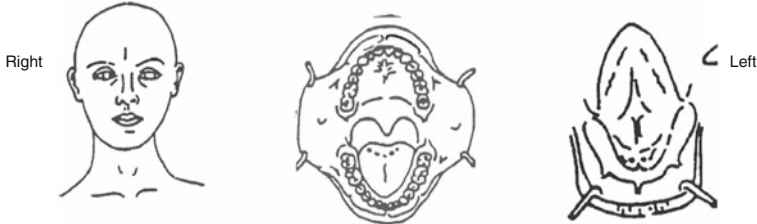
Fig.1.30 (continued)

Head and Neck Screening Exam Finding Control # _____

First Name _____ Last Name _____ DOB ____/____/____ SCREENING EXAM: by _____

_____ I participated in the oral cancer self examination
 _____ I participated in the smoking cessation presentation

Please indicate location of abnormal finding or diagram(s) below.



RECOMMENDATIONS:

- _____ Routine follow-up with your dentist.
- _____ Routine follow-up with primary care physician (medical doctor).
- _____ If problem identified persists, further head and neck evaluation id necessary with your dentist or medical doctor
- _____ Immediate evaluation and possible biopsy (tissue sampling) for suspected tumor id strongly advised.

REFERRAL INFORMATION

_____ Follow-up with: _____ to set up an immediate appointment.
 _____ Appointment date and time in the _____ Clinic on Date _____ Time _____
 Signature of Person receiving the exam, _____ Date ____/____/____

Fig. 1.31 This is a form that is completed and given to a patient with an unusual finding. The bottom half includes a provider that the patient needs to see for follow-up care or biopsy

References

American Cancer Society. ISSN register: <http://www.cancer.org/cancer/oralcavityandoropharyngealcancer/detailedguide/oral-cavity-and-oropharyngeal-cancer-signs-symptoms>. Accessed on 11 Mar 2016.

National Cancer Institute. ISSN register: <http://www.cancer.gov/publications/dictionaries/cancer-terms?cdrid=306510>. Accessed: 11 Mar 2016.

National Institute of Abuse and Alcoholism. ISSN register: <http://pubs.niaaa.nih.gov/publications/aa65/AA65.htm>. Accessed on 11 Mar 2016.

Oral Cancer Foundation. Cancer Screening Protocols. 2016. ISSN register: <http://www.oralcancerfoundation.org/discovery-diagnosis/screening.php> Accessed on 11 Mar 2016.

The Oral Cancer Foundation. ISSN register: <http://www.oralcancerfoundation.org/hpv/>. Accessed on 11 Mar 2016.

Rujuta Katkar

Contents

2.1 Radiation Safety and Protection.....	21
2.2 Normal Radiographic Anatomy.....	23
2.3 Radiographic Interpretation.....	24
2.4 Advanced Imaging.....	24
References.....	38

Abstract

This chapter focusses on the very basic concepts in dental radiology that a general dental practitioner should be aware of, including radiation safety and protection, current ADA imaging guidelines, radiographic exposure from common radiographic exams, normal radiographic anatomy, radiographic interpretation, radiographic features of common disease categories, and advanced imaging techniques.

2.1 Radiation Safety and Protection

- Check with local state board of dentistry for rules and regulations regarding use of radiation.
- Register all new x-ray equipment with the local state agency for radiation control.

R. Katkar, BDS, MDS, MS
University of Texas Health Science Center in San Antonio, San Antonio, TX, USA
e-mail: rujukatkar@gmail.com

Table 2.1 Effective dose from radiographic examinations and equivalent background exposure (White and Pharoah 2014)

Examination	Effective dose (μSv)	Equivalent background exposure (days)
<i>Intraoral</i>		
<i>Rectangular collimation</i>		
Posterior bitewings: PSP or F- speed film	5	0.6
Full-mouth: PSP or F-speed film	35	4
Full-mouth: CCD sensor (estimated)	17	2
<i>Round collimation</i>		
Full-mouth: D-speed film	388	46
Full-mouth: PSP or F-speed film	171	20
Full-mouth: CCD sensor (estimated)	85	10
<i>Extraoral</i>		
Panoramic	9–24	1–3
Cephalometric	2–6	0.3–0.7
Cone-beam CT		
Large field of view	68–1073	8–126
Medium field of view	45–860	5–101
Small field of view	19–652	2–77
Multi-slice CT		
Head: conventional protocol	860–1500	101–177
Head: low-dose protocol	180–534	21–63
Abdomen	5300	624
Chest	5800	682
Plain films		
Skull	70	8
Chest	20	2
Barium enema	7200	847

CCD charge-coupled device, PSP photostimulable phosphor

- Do clinical examination and justify the need for each radiograph before ordering it. Refer to ADA/FDA selection criteria for prescribing radiographs (<http://www.fda.gov/RadiationEmittingProducts/RadiationEmittingProductsandProcedures/MedicalImaging/MedicalX-Rays/ucm116503.htm>).
- Follow 'ALARA' principle (As Low As Reasonably Achievable) for optimizing radiation dose based on specific diagnostic tasks.
- Use fastest speed films (F-speed)/photostimulable phosphor (PSP) plates/digital receptors.
- Rectangular collimation reduces patient dose by five times compared to round collimation.
- Use protective aprons and thyroid collars when appropriate.
- Develop a radiographic quality assurance program and document the steps taken to follow it. For digital radiography, periodically check the sensors for any physical damage, resolution, contrast, and density by comparing to good reference radiographs. Calibrate monitors periodically.
- See table 2.1 for effective radiation dose from common radiographic procedures and equivalent background radiation.

2.2 Normal Radiographic Anatomy (Fig. 2.1)

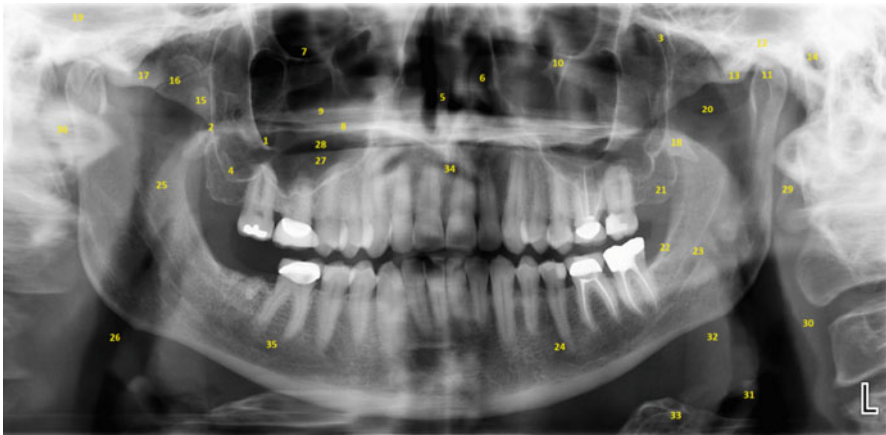


Fig. 2.1 Panoramic radiograph showing normal anatomical structures. Use the numbers in the radiograph to correspond to the key

Key: 1 zygomatic process of the maxilla, 2 posterior wall of the maxillary sinus, 3 pterygomaxillary fissure, 4 floor of the maxillary sinus, 5 nasal septum, 6 inferior nasal concha, 7 inferior orbital rim, 8 hard palate, 9 ghost image of opposite hard palate, 10 infraorbital canal, 11 mandibular condyle, 12 glenoid fossa, 13 articular eminence, 14 external auditory meatus, 15 coronoid process of the mandible, 16 zygomatico-temporal suture, 17 zygomatic arch, 18 pterygoid plate, 19 middle cranial fossa, 20 sigmoid notch, 21 maxillary tuberosity, 22 external oblique ridge, 23 mandibular canal, 24 mental foramen, 25 soft palate, 26 pharyngeal airway, 27 dorsal surface of tongue, 28 palatoglossal airway, 29 styloid process, 30 posterior pharyngeal wall, 31 epiglottis, 32 base of tongue, 33 hyoid bone, 34 intervertebral disk space between C1 and C2, 35 submandibular salivary gland fossa, 36 anterior arch of C1

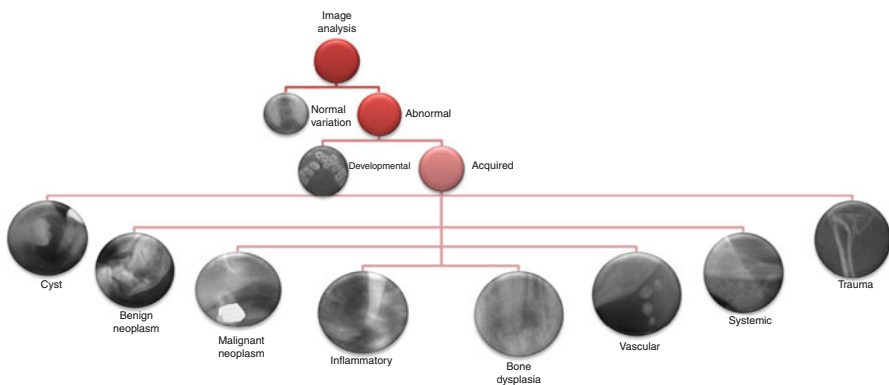


Fig. 2.2 Radiographic image analysis algorithm representing the diagnostic process