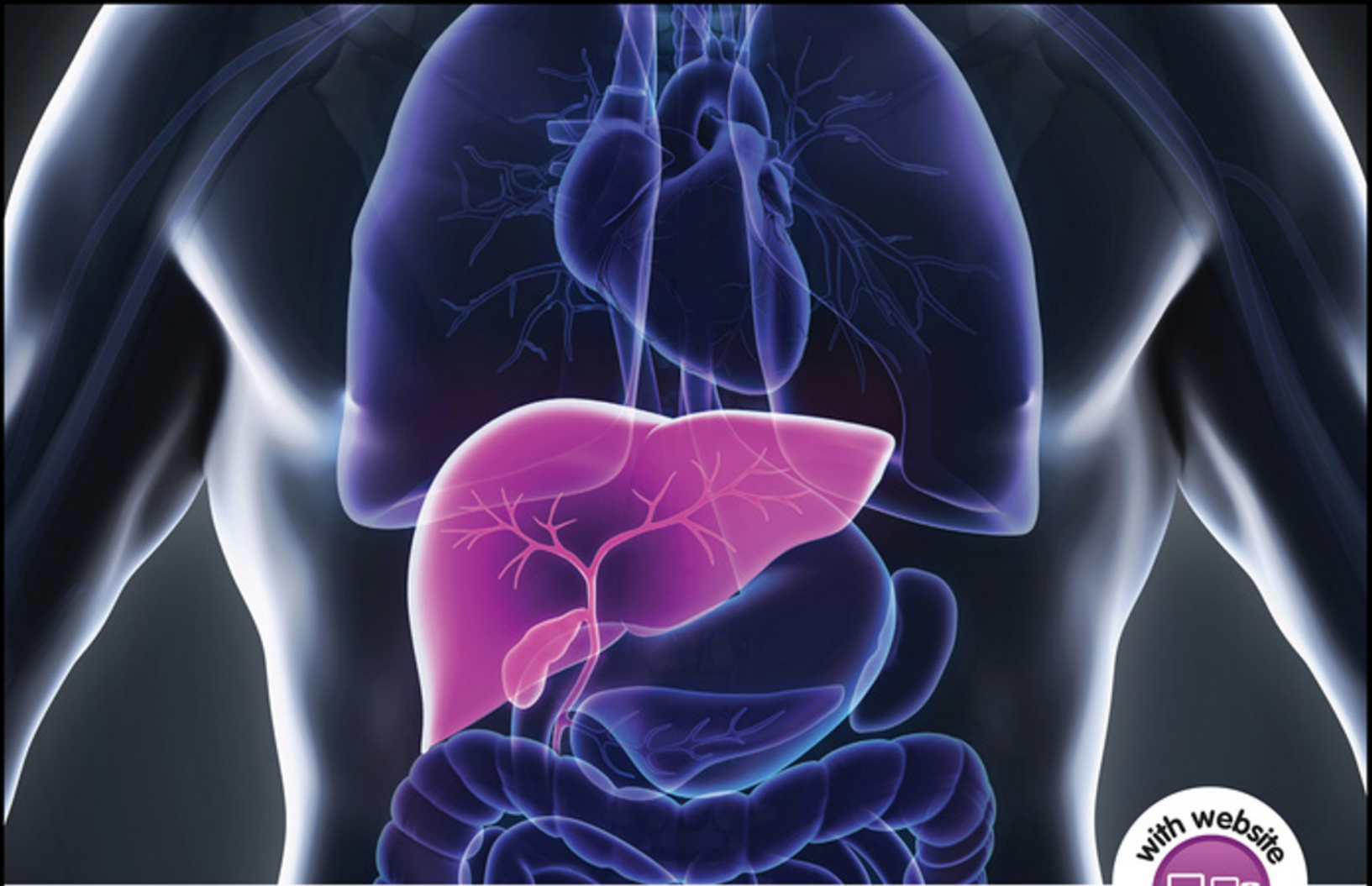



# SHERLOCK'S DISEASES OF THE LIVER AND BILIARY SYSTEM

13TH EDITION

Edited by

**James Dooley | Anna Lok**

**Guadalupe Garcia-Tsao | Massimo Pinzani**

**WILEY** Blackwell



## SHERLOCK'S DISEASES OF THE LIVER AND BILIARY SYSTEM

## About the Companion Website

This book is accompanied by a companion website:

[www.wiley.com/go/sherlock/liver13e](http://www.wiley.com/go/sherlock/liver13e)

The website includes:

- PowerPoints of all figures from the book for downloading

# Sherlock's Diseases of the Liver and Biliary System

Thirteenth Edition

*Edited By*

**James S. Dooley**

*University College London Institute for Liver and Digestive Health and  
Sheila Sherlock Liver Centre  
Royal Free London NHS Foundation Trust  
London  
UK*

**Anna S. F. Lok**

*Division of Gastroenterology and Hepatology  
Michigan Medicine, University of Michigan  
Ann Arbor, MI  
USA*

**Guadalupe Garcia-Tsao**

*Section of Digestive Diseases  
Yale University School of Medicine  
New Haven, CT;  
Veterans Affairs Connecticut Healthcare System  
West Haven, CT  
USA*

**Massimo Pinzani**

*University College London Institute for Liver and Digestive Health and  
Sheila Sherlock Liver Centre  
Royal Free London NHS Foundation Trust  
London  
UK*

**WILEY** Blackwell

This edition first published 2018.  
© 2018 John Wiley & Sons Ltd

*Edition History*

Blackwell Publishing Ltd (1e, 1955; 2e, 1958; 3e, 1963; 4e, 1968; 5e, 1975; 6e, 1981; 7e, 1985; 8e, 1989; 9e, 1993; 10e, 1997; 11e, 2002; 12e, 2011)

All rights reserved. No part of this publication may be reproduced, stored in a retrieval system, or transmitted, in any form or by any means, electronic, mechanical, photocopying, recording or otherwise, except as permitted by law. Advice on how to obtain permission to reuse material from this title is available at <http://www.wiley.com/go/permissions>.

The right of James S. Dooley, Anna S. F. Lok, Guadalupe Garcia-Tsao, Massimo Pinzani to be identified as the authors of the editorial material in this work has been asserted in accordance with law.

*Registered Office(s)*

John Wiley & Sons, Inc., 111 River Street, Hoboken, NJ 07030, USA  
John Wiley & Sons Ltd, The Atrium, Southern Gate, Chichester, West Sussex, PO19 8SQ, UK

*Editorial Office*

9600 Garsington Road, Oxford, OX4 2DQ, UK

For details of our global editorial offices, customer services, and more information about Wiley products visit us at [www.wiley.com](http://www.wiley.com).

Wiley also publishes its books in a variety of electronic formats and by print-on-demand. Some content that appears in standard print versions of this book may not be available in other formats.

*Limit of Liability/Disclaimer of Warranty*

The contents of this work are intended to further general scientific research, understanding, and discussion only and are not intended and should not be relied upon as recommending or promoting scientific method, diagnosis, or treatment by physicians for any particular patient. In view of ongoing research, equipment modifications, changes in governmental regulations, and the constant flow of information relating to the use of medicines, equipment, and devices, the reader is urged to review and evaluate the information provided in the package insert or instructions for each medicine, equipment, or device for, among other things, any changes in the instructions or indication of usage and for added warnings and precautions. While the publisher and authors have used their best efforts in preparing this work, they make no representations or warranties with respect to the accuracy or completeness of the contents of this work and specifically disclaim all warranties, including without limitation any implied warranties of merchantability or fitness for a particular purpose. No warranty may be created or extended by sales representatives, written sales materials or promotional statements for this work. The fact that an organization, website, or product is referred to in this work as a citation and/or potential source of further information does not mean that the publisher and authors endorse the information or services the organization, website, or product may provide or recommendations it may make. This work is sold with the understanding that the publisher is not engaged in rendering professional services. The advice and strategies contained herein may not be suitable for your situation. You should consult with a specialist where appropriate. Further, readers should be aware that websites listed in this work may have changed or disappeared between when this work was written and when it is read. Neither the publisher nor authors shall be liable for any loss of profit or any other commercial damages, including but not limited to special, incidental, consequential, or other damages.

*Library of Congress Cataloging-in-Publication Data*

Names: Dooley, James (James S.), editor. | Lok, Anna S. E., editor. | Garcia-Tsao, Guadalupe, editor. | Pinzani, Massimo, editor.  
Title: Sherlock's diseases of the liver and biliary system / edited by James S. Dooley, Anna S.F. Lok, Guadalupe Garcia-Tsao, Massimo Pinzani.  
Other titles: Diseases of the liver and biliary system  
Description: 13th edition. | Hoboken, NJ : Wiley, 2018. | Preceded by Sherlock's diseases of the liver and biliary system / edited by James S. Dooley ... [et al.]. 12th ed. 2011. | Includes bibliographical references and index. |  
Identifiers: LCCN 2017057075 (print) | LCCN 2017059204 (ebook) | ISBN 9781119237563 (pdf) | ISBN 9781119237648 (epub) | ISBN 9781119237549 (cloth)  
Subjects: | MESH: Liver Diseases | Biliary Tract Diseases  
Classification: LCC RC845 (ebook) | LCC RC845 (print) | NLM WI 700 | DDC 616.3/6--dc23  
LC record available at <https://lccn.loc.gov/2017057075>

Cover image: © Nerthuz/Shutterstock

Cover design by Wiley

Set in 10/12pt Warnock by SPi Global, Pondicherry, India

## Contents

- List of Contributors** *xi*  
**Preface to the Thirteenth Edition** *xv*  
**Preface to the First Edition** *xvi*
- 1 Anatomy and Function** *1*  
*Jay H. Lefkowitz*  
 Development of the liver and bile ducts *1*  
 Anatomy of the liver *1*  
 Functional liver anatomy: sectors and segments *3*  
 Anatomical abnormalities of the liver *3*  
 Anatomy of the biliary tract *4*  
 Surface marking *5*  
 Methods of examination *6*  
 Microanatomy of the liver *7*  
 Hepatic ultrastructure (electron microscopy) and organelle functions *9*  
 Functional heterogeneity of the liver *13*  
 Dynamics of the hepatic microenvironment in physiology and disease *14*  
 Hepatocyte death and regeneration *15*  
 References *16*
- 2 Liver Function in Health and Disease: Clinical Application of Liver Tests** *20*  
*George Mells and Graeme Alexander*  
 Bilirubin metabolism *21*  
 Bile acids *23*  
 Lipid and lipoprotein metabolism *26*  
 Amino acid metabolism *28*  
 Plasma proteins *29*  
 Carbohydrate metabolism *31*  
 Markers of hepatocellular injury: the serum transaminases *32*  
 Markers of cholestasis: alkaline phosphatase (ALP) and gamma-glutamyl transferase (GGT) *33*  
 Haematology in liver disease *34*  
 Effects of ageing on the liver *35*  
 References *36*
- 3 Biopsy of the Liver** *39*  
*David Patch and Tu Vinh Luong*  
 Selection and preparation of the patient *39*  
 Techniques *40*  
 Risks and complications *43*  
 Sampling variability *45*  
 Naked-eye appearances *46*  
 Preparation of the specimen *46*  
 Interpretation: a stepwise diagnostic approach *46*  
 Indications *48*  
 Special methods *49*  
 References *50*
- 4 Coagulation in Cirrhosis** *53*  
*Nicolas M. Intagliata and Stephen H. Caldwell*  
 Introduction *53*  
 Normal coagulation pathways: a hepatologist's perspective *54*  
 The coagulation system in cirrhosis *56*  
 Bleeding and thrombosis in cirrhosis *57*  
 Clinical laboratory tests of the coagulation system in cirrhosis *58*  
 Conclusion *60*  
 References *60*
- 5 Acute Liver Failure** *62*  
*Shannan R. Tujios and William M. Lee*  
 Definition *62*  
 Epidemiology and aetiologies *63*  
 Clinical features *66*  
 Initial investigations *67*  
 Complications and management of acute liver failure *68*  
 Specific therapies *73*  
 Prognosis *75*  
 Liver transplantation *76*  
 Conclusion *78*  
 References *78*

- 6 Hepatic Fibrogenesis 82**  
*Meena B. Bansal and Scott L. Friedman*  
 Introduction 82  
 Natural history of hepatic fibrosis 82  
 Cellular and molecular features of hepatic fibrosis 83  
 Clinical aspects of hepatic fibrosis 89  
 Emerging antifibrotic targets and strategies 89  
 References 90
- 7 Non-invasive Assessment of Fibrosis and Cirrhosis 93**  
*Avik Majumdar and Massimo Pinzani*  
 Introduction 93  
 The use of invasive and non-invasive tests 93  
 Non-invasive tests: specifics 95  
 Conclusions 102  
 References 103
- 8 Hepatic Cirrhosis 107**  
*P. Aiden McCormick and Rajiv Jalan*  
 Definition 107  
 Causes of cirrhosis 107  
 Anatomical diagnosis 108  
 Reversible cirrhosis 110  
 Clinical cirrhosis: compensated versus decompensated 110  
 Prognosis (Child–Pugh score, MELD, UKELD) 111  
 Clinical and pathological associations 112  
 Management 119  
 Acute-on-chronic liver failure 120  
 References 123
- 9 Ascites 127**  
*Guadalupe Garcia-Tsao*  
 Mechanisms of ascites formation 127  
 Clinical features 130  
 Differential diagnosis 132  
 Spontaneous bacterial peritonitis 132  
 Treatment of cirrhotic ascites 134  
 Hyponatraemia 138  
 Refractory ascites 139  
 Hepatorenal syndrome 141  
 Prognosis 144  
 References 145
- 10 Hepatic Encephalopathy in Patients with Cirrhosis 151**  
*Marsha Y. Morgan*  
 Clinical Features 151  
 Classification 153  
 Prevalence and consequences 154  
 Diagnosis 154
- Diagnostic comorbidities, confounders, and alternatives 160  
 Pathogenesis 161  
 Management 167  
 Prevention 174  
 References 174
- 11 Portal Hypertension in Cirrhosis 180**  
*Jaime Bosch and Annalisa Berzigotti*  
 Introduction 180  
 Pathophysiology and rational basis of therapy 185  
 Evaluation and diagnosis 188  
 Natural history and prognosis 194  
 Management 196  
 Treatment of portal hypertension according to clinical scenarios 200  
 References 205
- 12 Vascular Disorders of the Liver and Extrahepatic Portal Hypertension 209**  
*Dominique-Charles Valla*  
 Hepatic artery occlusion 209  
 Aneurysms of the hepatic artery 210  
 Hepatic arterioportal fistula 211  
 Hepatic vascular malformations in hereditary haemorrhagic telangiectasia 212  
 Congenital portosystemic shunts – Abernethy malformation 213  
 Budd–Chiari syndrome – hepatic venous outflow tract obstruction 214  
 Extrahepatic portal vein obstruction – portal vein thrombosis and portal cavernoma in the absence of cirrhosis 217  
 Portal vein thrombosis in patients with cirrhosis 220  
 Idiopathic non-cirrhotic intrahepatic portal hypertension 221  
 Hypoxic hepatitis 223  
 Congestive cardiac hepatopathy 223  
 Non-obstructive sinusoidal dilation (NOSD) and peliosis 225  
 References 226
- 13 Jaundice and Cholestasis 231**  
*Peter L. M. Jansen*  
 Introduction 231  
 Mechanics of bile formation 233  
 Syndrome of cholestasis 238  
 Causes of isolated hyperbilirubinaemia 239  
 Causes of cholestatic and hepatocellular jaundice 242



- Consequences of cholestasis and their management 244
- Investigation of the jaundiced patient 247
- Decisions to be made in the jaundiced patient 250
- Management of cholestatic disorders 251
- References 251
- 14 Gallstones and Benign Biliary Disease 256**  
*James S. Dooley, Kurinchi S. Gurusamy, and Brian R. Davidson*
- Introduction 256
- Imaging the gallbladder and biliary tract 256
- Gallstones 259
- Symptoms and complications of gallstones 264
- Cholecystectomy 266
- Complicated acute gallbladder disease 268
- Percutaneous cholecystostomy 269
- Asymptomatic gallbladder stones 269
- Non-surgical treatment of gallstones in the gallbladder 269
- Common bile duct stones 270
- Acute gallstone pancreatitis 272
- Large common duct stones 272
- Mirizzi syndrome 273
- Intrahepatic gallstones 274
- Haemobilia 274
- Functional gallbladder and sphincter of Oddi disorders 274
- Other gallbladder pathologies 276
- Relationships to malignant change 279
- Benign biliary strictures 279
- Anastomotic strictures following biliary surgery 282
- IgG4-related sclerosing cholangitis 283
- Chronic pancreatitis 283
- References 284
- 15 Malignant Biliary Diseases 294**  
*Rahul S. Koti and John Bridgewater*
- Carcinoma of the gallbladder 294
- Carcinoma of the bile duct (cholangiocarcinoma) 296
- Other biliary malignancies 301
- Metastases at the hilum 301
- Ampullary and periampullary carcinomas 301
- Conclusion 305
- References 305
- 16 Fibropolycystic Liver Diseases and Congenital Biliary Abnormalities 308**  
*Nedim Hadžić and Mario Strazzabosco*
- Overview 308
- Polycystic liver disease 309
- Fibropolycystic diseases 313
- Autosomal recessive polycystic kidney disease 314
- Congenital hepatic fibrosis 314
- Caroli disease 316
- Microhamartomas (von Meyenberg complexes) 318
- Choledochal cysts 318
- Solitary non-parasitic liver cyst 320
- Congenital anomalies of the biliary tract 321
- References 324
- 17 Primary Biliary Cholangitis 328**  
*David E. J. Jones*
- Clinical features 328
- Diagnosis 329
- Epidemiology 333
- Aetiology and pathogenesis 334
- Management 335
- Prognosis 337
- References 338
- 18 Sclerosing Cholangitis 341**  
*Tom Hemming Karlsen and Kirsten Muri Boberg*
- Introduction 341
- Primary sclerosing cholangitis 341
- Secondary sclerosing cholangitis 350
- Sclerosing cholangitis in systemic inflammatory diseases 351
- References 351
- 19 Autoimmune Hepatitis and Overlap Syndromes 355**  
*Ashnila Janmohamed and Gideon M. Hirschfield*
- Introduction 355
- Disease overview 356
- Biological determinants of disease 357
- Disease presentation 359
- Laboratory features 361
- Imaging 363
- Liver biopsy and histological features 363
- Differential diagnosis 365
- Diagnostic dilemmas 366
- Making a diagnosis in practice 367
- Management strategies 368
- Pretreatment and on-treatment considerations 371
- Treatment challenges and alternative agents 371
- Pregnancy and autoimmune hepatitis 372
- The elderly and autoimmune hepatitis 372
- Childhood-onset autoimmune hepatitis 373
- Autoimmune hepatitis and liver transplantation 373
- Overlap syndromes 374
- Conclusion 377
- References 377

**20 Enterically Transmitted Viral Hepatitis: Hepatitis****A and Hepatitis E 380***Rinjal D. Brahmabhatt and Anna S. F. Lok*

General features of enterically transmitted viral hepatitis 380

Hepatitis A virus 385

Hepatitis E virus 389

References 391

**21 Hepatitis B 395***Anna S. F. Lok*

Introduction 395

Hepatitis B virus 395

Immune response and mechanisms of hepatic injury 398

Epidemiology 399

Prevention 400

Diagnosis 402

Clinical manifestations 404

Natural history 405

Treatment 408

HBV and HCV coinfection 414

HBV and HDV coinfection 414

HBV and HIV coinfection 414

References 415

**22 Hepatitis D 421***Patrizia Farci and Grazia Anna Niro*

History 421

Hepatitis D virus 421

Epidemiology 422

Pathogenesis 425

Modes of infection and clinical course 425

Diagnosis 428

Treatment 429

Prevention 432

References 432

**23 Hepatitis C 436***Geoffrey Dusheiko*

Introduction 436

Epidemiology 436

Virology 438

Pathology and pathogenesis 439

Diagnostic tests for hepatitis C 440

Acute hepatitis C 441

Chronic hepatitis C 441

References 459

**24 Drug-Induced Liver Injury 468***Frank W. DiPaola and Robert J. Fontana*

Introduction 468

Epidemiology 468

Complications of DILI 469

Classification of hepatotoxicity 469

Drug metabolism and pharmacokinetics 469

Hepatic drug metabolism 471

Molecular mechanisms in drug-induced liver injury 472

Non-genetic risk factors for DILI 473

Diagnosis of DILI 474

Medical management 478

Pharmacogenetic risk factors 478

Potential immunological mechanisms in idiosyncratic DILI 479

Liver injury from specific drugs 479

References 486

**25 Alcohol and the Liver 494***Stephen Stewart and Ewan Forrest*

Introduction 494

Alcohol metabolism 494

Pathogenesis 496

Susceptibility 497

Histological features 498

Clinical features 501

Clinical syndromes 503

Prognosis 504

Treatment 506

Conclusions 507

References 508

**26 Iron Overload States 511***Paul Adams and Heinz Zoller*

Normal iron physiology 511

Iron overload and liver damage 515

Genetic haemochromatosis 516

Other iron storage diseases 521

References 523

**27 Wilson Disease 526***Eve A. Roberts and Karl Heinz Weiss*

Molecular genetics: pathogenesis 527

Pathology 528

Clinical picture 529

Laboratory tests 532

Genetic strategies 533

Diagnostic difficulties 533

Treatment 533

Prognosis 536

Non-Wilsonian copper-related cirrhosis 536

References 536

**28 Non-Alcoholic Fatty Liver Disease 540***Timothy Hardy and Christopher P. Day*

Introduction 540

Further definitions, terminology, and diagnosis 541

Liver biopsy, classification of NAFLD, and non-invasive markers of NASH and fibrosis 541

- Clinical features 543  
 Laboratory testing 544  
 Epidemiology 545  
 Ethnic variation in NAFLD 545  
 Pathogenesis of NASH 545  
 Natural history of NAFLD 550  
 NAFLD and hepatocellular carcinoma (HCC) 551  
 Therapy for non-alcoholic fatty liver disease 552  
 Other forms of NAFLD 554  
 References 555
- 29 Nutrition and Chronic Liver Disease 561**  
*Manuela Merli*  
 Introduction 561  
 Epidemiology and general characteristics 562  
 Causes of malnutrition 562  
 Consequences of malnutrition 564  
 Diagnosis and assessment 565  
 Treatment and management 568  
 References 570
- 30 Pregnancy and the Liver 572**  
*Rachel H. Westbrook and Catherine Williamson*  
 Introduction 572  
 Normal physiology in pregnancy 572  
 Pregnancy-related liver diseases 573  
 Pre-existing liver diseases and pregnancy 578  
 Liver transplantation and pregnancy 580  
 Liver disease coincidentally arising with pregnancy 581  
 Conclusion 582  
 References 582
- 31 The Liver in the Neonate, in Infancy, and Childhood 588**  
*Susan M. Siew and Deirdre A. Kelly*  
 Investigation of liver disease in children 588  
 Neonatal jaundice 589  
 Neonatal unconjugated hyperbilirubinaemia 589  
 Neonatal liver disease (conjugated hyperbilirubinaemia) 591  
 Neonatal hepatitis 594  
 Inherited disease in the neonate 596  
 Genetic cholestatic syndromes 598  
 Structural abnormalities: biliary atresia and choledochal cyst 600  
 Acute liver failure in infancy 602  
 Liver disease in older children 605  
 Metabolic disease in older children 607  
 Cirrhosis and portal hypertension 613  
 Liver transplantation 613  
 Tumours of the liver 614  
 References 615
- 32 The Liver in Systemic Diseases 622**  
*James S. Dooley and Christopher McNamara*  
 Collagen-vascular and autoimmune disorders 622  
 Hepatic granulomas 624  
 Sarcoidosis 626  
 The liver in endocrine disorders 628  
 Amyloidosis 629  
 Porphyrias 632  
 The liver in haemolytic anaemias 634  
 The liver in myelo- and lymphoproliferative disease 638  
 Bone marrow transplantation 639  
 Lymphoma 640  
 Extramedullary haemopoiesis 642  
 Rare haematological disorders that may involve the liver 643  
 Lipid storage diseases 643  
 Non-metastatic complications of malignancy 646  
 References 646
- 33 The Liver in Infections 652**  
*Sanjay Bhagani and Ian Cropley*  
 Introduction 652  
 Jaundice of infections 652  
 Pyogenic liver abscess 652  
 Hepatic amoebiasis 655  
 Tuberculosis of the liver 657  
 Hepatic actinomycosis 659  
 Syphilis of the liver 659  
 Perihepatitis 660  
 Leptospirosis 660  
 Relapsing fever 663  
 Lyme disease 663  
 Rickettsial infections 663  
 Fungal infections 664  
 Schistosomiasis (bilharzia) 665  
 Malaria 667  
 Kala-azar (visceral leishmaniasis) 668  
 Echinococcosis (hydatid disease) 668  
 Ascariasis 673  
 Strongyloides stercoralis 674  
 Trichinosis 674  
 Toxocara canis (visceral larva migrans) 674  
 Liver flukes 675  
 References 676
- 34 Imaging of the Liver and Diagnostic Approach of Space-Occupying Lesions 682**  
*Neil H. Davies and Dominic Yu*  
 Ultrasound 682  
 Computed tomography 683  
 Magnetic resonance imaging 685  
 Radioisotope scanning 688  
 Positron emission tomography 691

MR spectroscopy 691  
Conclusions and choice of imaging technique 691  
References 691

### 35 Benign Liver Tumours 693

*Ian R. Wanless*

Diagnosis of focal liver lesions 693  
Hepatocellular lesions 693  
Biliary and cystic lesions 699  
Mesenchymal tumours 700  
References 701

### 36 Primary Malignant Neoplasms of the Liver 705

*Adam Doyle and Morris Sherman*

Hepatocellular carcinoma 705  
Intrahepatic cholangiocarcinoma 718  
Other malignant neoplasms of the liver 721  
Other sarcomas 722  
References 722

### 37 Hepatic Transplantation 730

*Lindsay Y. King and Carl L. Berg*

Selection of patients 730  
Candidates 732

Absolute and relative contraindications 737  
General preparation of the patient 738  
Donor selection and operation 738  
The recipient operation 739  
Immunosuppression 742  
Postoperative course 743  
Post-transplantation complications 744  
Conclusion 751  
References 752

### 38 Hepatic Transplantation and HBV, HCV, and HIV

#### Infections 758

*Norah A. Terrault*

Introduction 758  
Hepatitis B and liver transplantation 759  
Hepatitis C and liver transplantation 763  
HIV and liver transplantation 770  
References 773

#### Index 781

## List of Contributors

### **Paul Adams MD**

Professor of Medicine  
Chief of Gastroenterology  
University Hospital  
University of Western Ontario  
London, ON, Canada

### **Graeme Alexander MA, MD, FRCP**

UCL Professor  
Institute for Liver and Digestive Health  
UCL Medical School  
London, UK

### **Meena B. Bansal MD**

Associate Professor of Medicine  
Division of Liver Diseases  
Icahn School of Medicine at Mount Sinai  
New York, NY, USA

### **Carl L. Berg MD**

Professor of Medicine  
Medical Director of Abdominal Transplantation  
Duke University Health System  
Durham, NC, USA

### **Annalisa Berzigotti MD, PhD**

Swiss Liver Center, Hepatology  
University Clinic for Visceral Surgery and Medicine  
Inselspital  
University of Bern  
Bern, Switzerland

### **Sanjay Bhagani BSc, MB BCh, FRCP**

Consultant Physician and Honorary Senior Lecturer  
Department of Infectious Diseases/HIV Medicine  
Royal Free Hospital  
Research Department of Infection, UCL  
London, UK

### **Kirsten Muri Boberg MD, PhD**

Professor of Hepatology  
Department of Transplantation Medicine  
Oslo University Hospital Rikshospitalet  
Oslo, Norway

### **Jaime Bosch MD, PhD, FRCP, FAASLD**

Hepatic Hemodynamic Laboratory, Liver Unit,  
Hospital Clinic, IDIBAPS, University of Barcelona  
Barcelona, Spain;  
CIBERehd, Instituto de Salud Carlos III, Madrid, Spain;  
Swiss Liver Center, Hepatology, University Clinic for  
Visceral Surgery and Medicine, Inselspital, University  
of Bern  
Bern, Switzerland

### **Rinjal D. Brahmabhatt MD**

Division of Gastroenterology and Hepatology  
Michigan Medicine, University of Michigan  
Ann Arbor, MI, USA

### **John Bridgewater MA, FRCP, PhD, MB BS**

Professor and Consultant in Medical Oncology  
University College London Medical School and Cancer  
Institute  
London, UK

### **Stephen H. Caldwell MD**

Professor, Director of Hepatology  
Division of Gastroenterology and Hepatology  
University of Virginia  
Charlottesville, VA, USA

### **Ian Cropley MA, MB BS, FRCP, DTM&H**

Consultant Physician and Honorary Senior Lecturer  
Department of Infectious Diseases/HIV Medicine  
Royal Free Hospital  
London, UK

### **Brian R. Davidson MB BCh, MD, FRCS (Glas), FRCS (Eng)**

Consultant HPB and Liver Transplant Surgeon  
HPB and Liver Transplant Unit  
Royal Free Hospital, London  
Professor of Surgery  
Head of HBP and Liver Transplant Research  
University College London Medical School, Royal Free  
Campus,  
London, UK

**Neil H. Davies MB BS, FRCS, FRCR**  
Consultant Interventional Radiologist  
Department of Radiology  
Royal Free Hospital  
London, UK

**Christopher P. Day FMedSci**  
Professor of Liver Medicine  
Institute of Cellular Medicine, Newcastle University  
Newcastle upon Tyne, UK

**Frank W. DiPaola MD**  
Department of Pediatrics  
University of Michigan Medical School  
Ann Arbor, MI, USA

**James S. Dooley MD, FRCP**  
Emeritus Reader in Medicine, UCL Institute for Liver  
and Digestive Health, and Honorary Consultant  
Hepatologist, Sheila Sherlock Liver Centre,  
Royal Free Hospital  
London, UK

**Adam Doyle MBBS, BMedSc, FRACP**  
Department of Gastroenterology and Hepatology  
Royal Perth Hospital  
Perth, WA, Australia

**Geoffrey Dusheiko FCP(SA), FRCP, FRCP(Edin)**  
Emeritus Professor of Medicine, UCL Institute  
for Liver and Digestive Health, and Kings College  
Hospital  
London, UK

**Patrizia Farci MD**  
Chief, Hepatic Pathogenesis Section  
Laboratory of Infectious Diseases  
National Institute of Allergy and Infectious Diseases  
National Institutes of Health  
Bethesda, MD, USA

**Robert J. Fontana, MD**  
Professor of Medicine  
Department of Internal Medicine, University of  
Michigan Medical School  
Ann Arbor, MI, USA

**Ewan Forrest MD, FRCPS (Glasgow), FRCP (Edin)**  
Consultant Hepatologist  
Liver Unit, Glasgow Royal Infirmary  
Glasgow, UK

**Scott L. Friedman MD**  
Fishberg Professor of Medicine  
Chief, Division of Liver Diseases  
Icahn School of Medicine at Mount Sinai  
New York, NY, USA

**Guadalupe Garcia-Tsao MD**  
Professor of Medicine  
Section of Digestive Diseases  
Yale School of Medicine  
New Haven, CT;  
Veterans Affairs Connecticut Healthcare System  
West Haven, CT, USA

**Kurinchi S. Gurusamy MB BS, MRCS, PhD**  
Reader in Surgery  
University College London Medical School, Royal Free  
Campus, and Royal Free Hospital, London, UK

**Nedim Hadžić MD, MSc, FRCPCH, FAALD**  
Professor and Consultant in Paediatric Hepatology  
Paediatric Centre for Hepatology, Gastroenterology and  
Nutrition  
King's College Hospital  
London, UK

**Timothy Hardy MB BS, BSc (Hons)**  
MRC Clinical Research Fellow  
Institute of Cellular Medicine, Newcastle University  
Newcastle upon Tyne, UK

**Gideon M. Hirschfield MA, MB BChir, PhD, FRCP**  
Professor and Honorary Consultant Hepatologist  
Centre for Liver Research, NIHR Biomedical Research  
Centre, University of Birmingham  
Birmingham, UK

**Nicolas M. Intagliata MD**  
Assistant Professor of Medicine, Gastroenterology and  
Hepatology  
University of Virginia  
Charlottesville, VA, USA

**Rajiv Jalan MBBS, MD, PhD, FRCP, FRCPE, FAASLD**  
Professor of Hepatology  
Liver Failure Group, Institute for Liver and Digestive  
Health, Division of Medicine, University College  
London  
London, UK

**Ashnila Janmohamed BSc, MBBS, MRCP**  
Clinical Research Fellow in Hepatology  
Centre for Liver Research, NIHR Biomedical Research  
Centre, University of Birmingham  
Birmingham, UK



**Peter L. M. Jansen MD, PhD**

Professor of Hepatology  
 Department of Gastroenterology and Hepatology  
 Academic Medical Center  
 University of Amsterdam  
 Amsterdam, The Netherlands

**David E. J. Jones BM, BCh, MA, PhD, FRCP**

Professor of Liver Immunology  
 Medical School, Newcastle University  
 Honorary Consultant Hepatologist  
 Freeman Hospital  
 Newcastle upon Tyne, UK

**Tom Hemming Karlsen MD, PhD**

Professor of Internal Medicine  
 Senior Consultant of Gastroenterology and Hepatology  
 Department of Transplantation Medicine  
 Oslo University Hospital Rikshospitalet  
 Oslo, Norway

**Deirdre A. Kelly MD, FRCP, FRCPI, FRCPC**

Professor of Paediatric Hepatology  
 Birmingham Children's Hospital and University of  
 Birmingham  
 Birmingham, UK

**Lindsay Y. King MD, MPH**

Assistant Professor of Medicine  
 Duke University Health System  
 Durham, NC, USA

**Rahul S. Koti MD, FRCS**

Honorary Senior Lecturer in Surgery  
 Royal Free Hospital and University College London  
 Medical School  
 London, UK

**William M. Lee MD, FACP**

Professor of Internal Medicine  
 University of Texas Southwestern Medical Center  
 Dallas, TX, USA

**Jay H. Lefkowitz MD**

Professor of Clinical Pathology  
 College of Physicians and Surgeons, Columbia University  
 New York, NY, USA

**Anna S. F. Lok MBBS, MD, FRCP**

Alice Lohrman Andrews Research Professor in  
 Hepatology  
 Director of Clinical Hepatology  
 Division of Gastroenterology and Hepatology  
 Michigan Medicine, University of Michigan  
 Ann Arbor, MI, USA

**Tu Vinh Luong MD**

Consultant Histopathologist  
 Department of Cellular Pathology, Royal Free Hospital;  
 Honorary Senior Lecturer,  
 UCL Institute for Liver and Digestive Health  
 London, UK

**Avik Majumdar MBBS(Hons), MPHTM, FRACP**

UCL Institute for Liver and Digestive Health and  
 Sheila Sherlock Liver Centre  
 Royal Free Hospital, London, UK;  
 AW Morrow Gastroenterology and Liver Centre  
 Australian National Liver Transplant Unit  
 Royal Prince Alfred Hospital,  
 Sydney, NSW, Australia

**Christopher McNamara FRACP, FRCPA, FRCPath**

Department of Haematology  
 University College London Hospitals  
 London, UK

**P. Aiden McCormick MD, FRCP, FRCPI, FEBGH, FAASLD**

Consultant Hepatologist and Newman  
 Clinical Research Professor  
 St Vincent's University Hospital and  
 University College Dublin  
 Dublin, Ireland

**George Mells MB BS, PhD, MRCP**

Consultant Hepatologist  
 Cambridge Liver Unit  
 Addenbrooke's Hospital  
 Cambridge, UK

**Manuela Merli MD**

Associate Professor, Gastroenterology  
 Department of Clinical Medicine, Sapienza  
 University of Rome  
 Rome, Italy

**Marsha Y. Morgan MB ChB, FRCP**

Principal Research Associate and Honorary  
 Consultant Physician  
 UCL Institute for Liver and Digestive Health  
 Division of Medicine  
 University College London  
 London, UK

**Grazia Anna Niro, MD**

Gastroenterology Unit  
 IRCCS "Casa Sollievo Sofferenza" Hospital  
 San Giovanni Rotondo  
 Foggia, Italy

**David Patch MB BS, FRCP**

Consultant Hepatologist  
Sheila Sherlock Liver Centre, Royal Free Hospital and  
UCL Institute for Liver and Digestive Health  
London, UK

**Massimo Pinzani MD, PhD, FRCP, FAASLD**

Professor of Medicine  
UCL Institute for Liver and Digestive Health and Sheila  
Sherlock Liver Centre  
Royal Free Hospital  
London, UK

**Eve A. Roberts MD, PhD, FRCPC**

Departments of Paediatrics, Medicine, and  
Pharmacology and Toxicology  
University of Toronto  
Toronto, ON, Canada

**Morris Sherman MB BCh, PhD, FRCP(C), FAASLD**

Professor of Medicine  
Department of Medicine,  
Division of Gastroenterology  
University of Toronto and  
University Health Network  
Toronto, ON, Canada

**Susan M. Siew MBBS (Hons.), FRACP, PhD**

Paediatric Gastroenterologist  
Department of Gastroenterology and James Fairfax  
Institute of Paediatric Nutrition  
Sydney Children's Hospital Network (Westmead)  
Sydney, NSW, Australia

**Stephen Stewart MBChB, PhD**

Consultant Hepatologist and Director of Centre for  
Liver Disease  
Mater Misericordiae University Hospital  
Dublin, Ireland

**Mario Strazzabosco MD, PhD**

Professor of Medicine;  
Director, Smilow Liver Cancer Program;  
Deputy Director, Yale Liver Center  
Yale School of Medicine  
New Haven, CT, USA

**Norah A. Terrault MD, MPH**

Professor of Medicine  
Division of Gastroenterology/Hepatology  
University of California San Francisco  
San Francisco, CA, USA

**Shannan R. Tujios MD**

Assistant Professor of Internal Medicine  
Division of Digestive and Liver Diseases  
University of Texas Southwestern Medical Center  
Dallas, TX, USA

**Dominique-Charles Valla MD**

Professor of Hepatology  
University Paris-Diderot and Inserm UMR-1149, Paris;  
Department of Hepatology, Hôpital Beaujon, APHP  
Clichy-la-Garenne, France

**Ian R. Wanless MD CM, FRCPC**

Professor of Pathology  
Department of Pathology  
Queen Elizabeth II Health Sciences Centre and  
Dalhousie University  
Halifax, NS, Canada

**Karl Heinz Weiss MD**

Head of Section of Transplant Hepatology  
Department of Internal Medicine IV  
University of Heidelberg  
Heidelberg, Germany

**Rachel H. Westbrook MBChB, MRCP, MD**

Consultant Hepatologist and Honorary Senior Lecturer  
Royal Free Hospital and UCL Institute for Liver and  
Digestive Health  
London, UK

**Catherine Williamson MD, FRCP**

Professor of Women's Health, Department of Women  
and Children's Health  
Faculty of Life Sciences & Medicine  
King's College London  
London, UK

**Dominic Yu MB BS, MRCPI, FRCR**

Consultant Radiologist  
Department of Radiology  
Royal Free Hospital  
London, UK

**Heinz Zoller MD**

Associate Professor of Medicine  
Consultant in Gastroenterology and Hepatology  
Department of Internal Medicine 1  
Medical University of Innsbruck  
Innsbruck, Austria



## Preface to the Thirteenth Edition

---

Since 2011 important new data have contributed to all areas of hepatobiliary disease, and revision of the 12th edition of *Sherlock's Diseases of the Liver and Biliary System*, published then, is timely. Many clinical challenges remain. However, advances in the understanding of pathogenesis and prognostic staging are leading to more individualized patient care and providing improved outcomes in many conditions. Studies of the basic cellular mechanisms involved are leading to the investigation of new therapeutic approaches.

A particular advance with important implications is in the treatment of hepatitis C, which can now be cured in more than 95% of patients with 8 to 16 weeks of oral anti-viral therapy.

The current hepatological epidemic in the Western world is non-alcoholic fatty liver disease and much research is published and on-going to dissect and understand the mechanisms and predisposing factors related to progression to cirrhosis. New agents are being studied for their potential to prevent or reverse such progression.

The drive of clinical hepatologists and basic scientists for greater understanding is a credit to the worldwide community of those involved. International collaborations to gather data on large cohorts of patients are playing an important role. Viral hepatitis has been mentioned, but there has been much new work in cholestatic liver diseases. Molecular genetic techniques are more accessible, for example in the diagnosis of conditions such as haemochromatosis and Wilson disease. Gene therapy may be on the horizon for some genetic diseases. Genome-wide studies are becoming almost routine to dissect the predisposing factors, for example in immune-related and alcoholic liver disease. Liver imaging, already strides ahead of what was available in earlier days, has greatly reduced the need for biopsies. Liver transplantation is widely available. The selection and management of this cohort of patients is constantly being assessed and refined to attain better outcomes.

Sheila Sherlock, an enthusiastic pioneer in the development of Hepatology worldwide, would have been

excited and we think stunned by the current state of her speciality. She herself used her textbook as a resource in which to annotate the most current work and knowledge. Her goal with each edition was to provide a textbook of manageable size, critical and current.

It is with this ethos that we have approached the 13th edition with specialist contributors from across the world. We hope that this edition will stimulate interest in hepatobiliary disease among students and young doctors, as well as provide a reference source for specialist hepatologists, surgeons, pathologists, radiologists, and clinical nurse specialists. The edition has over 100 new figures and more than 1500 new references.

The format is as before – designed to preserve clarity, with the text written as far as is possible with Sheila Sherlock's style in mind.

New chapters reflect current developments and interest with particular contributions on non-invasive assessment of hepatic fibrosis and cirrhosis, coagulation in cirrhosis, and nutrition in the patient with cirrhosis.

We are most grateful to the authors for their work updating, fully revising, or providing new chapters. We thank Pri Gibbons and Deirdre Barry at Wiley Blackwell for their contributions to making this project a success. We wish also to express our particular thanks to Gill Whitley for her unflinching commitment, expertise, and support during the production of this 13th edition. We are grateful to Jane Fallows for the new artwork and for the reworking where necessary of figures from the previous edition.

Finally, this textbook is the legacy of Sheila Sherlock's exceptional life and career, and we hope that her daughters and their families will take pleasure in seeing their mother's seminal contribution to Hepatology celebrated in another edition of *Diseases of the Liver and Biliary System*.

September 2017

James S. Dooley  
Anna S. F. Lok  
Guadalupe Garcia-Tsao  
Massimo Pinzani

## Preface to the First Edition

---

My aim in writing this book has been to present a comprehensive and up-to-date account of diseases of the liver and biliary system, which I hope will be of value to physicians, surgeons, and pathologists and also a reference book for the clinical student. The modern literature has been reviewed with special reference to articles of general interest. Many older more specialized classical contributions have therefore inevitably been excluded.

Disorders of the liver and biliary system may be classified under the traditional concept of individual diseases. Alternatively, as I have endeavoured in this book, they may be described by the functional and morphological changes which they produce. In the clinical management of a patient with liver disease, it is important to assess the degree of disturbance of four functional and morphological components of the liver: hepatic cells, vascular system (portal vein, hepatic artery, and hepatic veins), bile ducts, and reticulo-endothelial system. The typical reaction pattern is thus sought and recognized before attempting to diagnose the causative insult. Clinical and laboratory methods of assessing each of these components are therefore considered early in the book. Descriptions of individual diseases follow as illustrative examples. It will be seen that the features of hepatocellular failure and portal hypertension are described in general terms as a foundation for subsequent discussion of virus hepatitis, nutrition liver disease, and the cirrhotoses. Similarly blood diseases and infections of the liver are included with the reticuloendothelial system, and disorders of the biliary tract follow descriptions of acute and chronic bile duct obstruction.

I would like to acknowledge my indebtedness to my teachers, the late Professor J. Henry Dible, the late Professor Sir James Learmonth and Professor Sir John McMichael, who stimulated my interest in hepatic disease, and to my colleagues at the Postgraduate Medical School and elsewhere who have generously invited me to see patients under their care. I am grateful to Dr A. G. Bearn for criticizing part of the typescript and to Dr A. Paton for his criticisms and careful proof reading. Miss D. F. Atkins gave much assistance with proof reading and

with the bibliography. Mr Per Saugman and Mrs J. M. Green of Blackwell Scientific Publications have co-operated enthusiastically in the production of this book.

The photomicrographs were taken by Mr E. V. Willmott, FRPS, and Mr C. A. P. Graham from sections prepared by Mr J. G. Griffin and the histology staff of the Postgraduate Medical School. Clinical photographs are the work of Mr C. R. Brecknell and his assistants. The black and white drawings were made by Mrs H. M. G. Wilson and Mr D. Simmonds. I am indebted to them all for their patience and skill.

The text includes part of unpublished material included in a thesis submitted in 1944 to the University of Edinburgh for the degree of MD, and part of an essay awarded the Buckston–Browne prize of the Harveian Society of London in 1953. Colleagues have allowed me to include published work of which they are jointly responsible. Dr Patricia P. Franklyn and Dr R. E. Steiner have kindly loaned me radiographs. Many authors have given me permission to reproduce illustrations and detailed acknowledgments are given in the text. I wish also to thank the editors of the following journals for permission to include illustrations: *American Journal of Medicine*, *Archives of Pathology*, *British Heart Journal*, *Circulation*, *Clinical Science*, *Edinburgh Medical Journal*, *Journal of Clinical Investigation*, *Journal of Laboratory and Clinical Investigation*, *Journal of Pathology and Bacteriology*, *Lancet*, *Postgraduate Medical Journal*, *Proceedings of the Staff Meetings of the Mayo Clinic*, *Quarterly Journal of Medicine*, *Thorax*, and also the following publishers: Butterworth's Medical Publications, J. & A. Churchill Ltd, The Josiah Macy Junior Foundation, and G. D. Searle & Co.

Finally I must thank my husband, Dr D. Geraint James, who, at considerable personal inconvenience, encouraged me to undertake the writing of this book and also criticized and rewrote most of it. He will not allow me to dedicate it to him.

SHEILA SHERLOCK  
1955

## Chapter 1

### Anatomy and Function

Jay H. Lefkowitz

College of Physicians and Surgeons, Columbia University, New York, NY, USA

#### LEARNING POINTS

- The liver is derived from a foregut endodermal bud which develops in the third week of gestation and divides into two parts: hepatic and biliary.
- The Couinaud classification subdivides the liver into eight segments (segments I–IV in the left lobe, segments V–VIII in the right lobe) based on vascular and biliary anatomical landmarks.
- The lobule described by Kiernan is the most widely used unit of liver microanatomy, consisting of a hexagon-like region of liver parenchyma with a central vein as its hub and portal tracts located in the periphery of the hexagon.
- Hepatocytes are functionally heterogeneous within the lobular parenchyma, whereby centrilobular cells subserve different functions (e.g. drug metabolism) from periportal cells (e.g. bile salt-dependent bile formation).
- Uncomplicated regeneration of hepatocytes and/or bile duct epithelium usually occurs by cell division of the indigenous cells; however, when normal regenerative capacity is overwhelmed there may be activation of progenitor cells located in the region of the canals of Hering.

#### Development of the liver and bile ducts

The liver begins as a hollow endodermal bud from the foregut (duodenum) during the third week of gestation. The bud separates into two parts: hepatic and biliary. The *hepatic* part contains bipotential progenitor cells that differentiate into hepatocytes or ductal cells, which form the early primitive bile duct structures (bile duct plates). Differentiation is accompanied by changes in cytokeratin type within the cell [1]. Normally, this collection of rapidly

proliferating cells penetrates adjacent mesodermal tissue (the septum transversum) and is met by ingrowing capillary plexuses from the vitelline and umbilical veins, which will form the sinusoids. The connection between this proliferating mass of cells and the foregut, the *biliary* part of the endodermal bud, will form the gallbladder and extrahepatic bile ducts. The intrahepatic bile ducts begin to develop at week 8 from the flattened epithelium of the ductal plates adjacent to portal tracts [2]. Bile begins to flow at about the 12th week. Connective tissue cells of portal tracts are derived from the mesoderm of the septum transversum. Kupffer cells derive from circulating monocytes and possibly yolk sac macrophages. Hepatic stellate cells appear to be mesodermal derivatives from submesothelial cells located beneath the surface of the developing liver [3]. The fetal liver is the main site of haemopoiesis by the 12th week; this subsides in the fifth month coincident with the onset of bone marrow haemopoietic activity, so that only a few haemopoietic cells remain at birth.

#### Anatomy of the liver

The liver, the largest organ in the body, weighs 1200–1500g and comprises one-fiftieth of the total adult body weight. It is relatively larger in infancy, comprising one-eighteenth of the birth weight. This is mainly due to a large left lobe.

Sheltered by the ribs in the right upper quadrant, the upper border lies approximately at the level of the nipples. There are two anatomical lobes, the right being about six times the size of the left (Fig. 1.1, Fig. 1.2, Fig. 1.3). Lesser segments of the right lobe are the *caudate lobe* on the posterior surface and the *quadrate lobe* on the inferior surface. The right and left lobes are separated anteriorly by a fold of peritoneum called the falciform ligament, posteriorly by the fissure for the ligamentum venosum, and inferiorly by the fissure for the ligamentum teres.

*Sherlock's Diseases of the Liver and Biliary System*, Thirteenth Edition. Edited by James S. Dooley, Anna S. F. Lok, Guadalupe Garcia-Tsao and Massimo Pinzani.

© 2018 John Wiley & Sons Ltd. Published 2018 by John Wiley & Sons Ltd.

Companion website: [www.wiley.com/go/sherlock/liver13e](http://www.wiley.com/go/sherlock/liver13e)

The liver has a double blood supply. The *portal vein* brings venous blood from the intestines and spleen and the *hepatic artery*, coming from the coeliac axis, supplies the liver with arterial blood. These vessels enter the liver through a fissure, the *porta hepatis*, which lies far back on the inferior surface of the right lobe. Inside the porta, the portal vein and hepatic artery divide into branches to the right and left lobes, and the right and left hepatic bile ducts

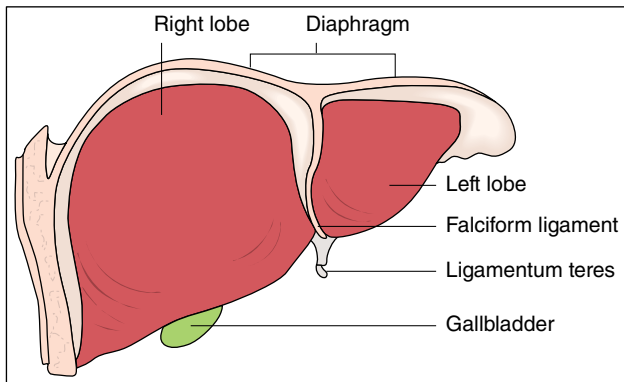


Fig. 1.1 Anterior view of the liver.

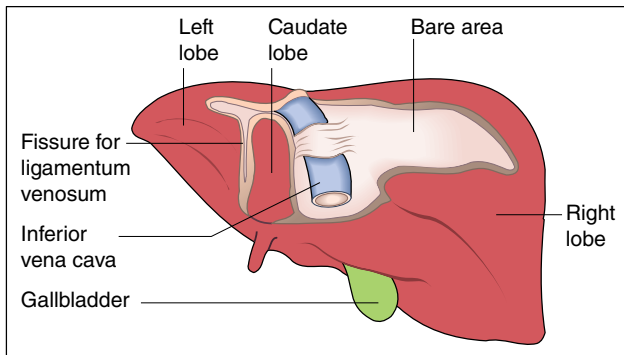


Fig. 1.2 Posterior view of the liver.

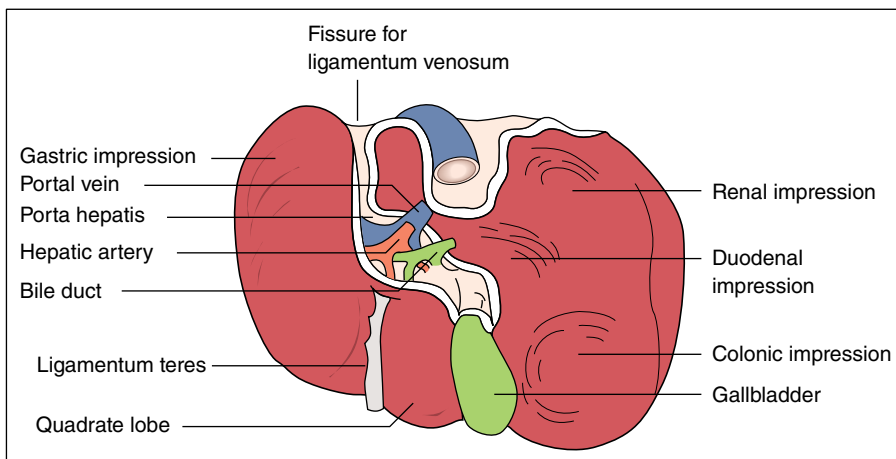


Fig. 1.3 Inferior view of the liver.

join to form the common hepatic duct. The *hepatic nerve plexus* contains fibres from the sympathetic ganglia T7–T10, which synapse in the coeliac plexus, the right and left vagi and the right phrenic nerve. It accompanies the hepatic artery and bile ducts into their finest ramifications, even to the portal tracts and hepatic parenchyma [4].

The *ligamentum venosum*, a slender remnant of the ductus venosus of the fetus, arises from the left branch of the portal vein and fuses with the inferior vena cava at the entrance of the left hepatic vein. The *ligamentum teres*, a remnant of the umbilical vein of the fetus, runs in the free edge of the falciform ligament from the umbilicus to the inferior border of the liver and joins the left branch of the portal vein. Small veins accompanying it connect the portal vein with veins around the umbilicus. These become prominent when the portal venous system is obstructed inside the liver.

The venous drainage from the liver is into the *right and left hepatic veins* which emerge from the back of the liver and at once enter the inferior vena cava very near its point of entry into the right atrium.

*Lymphatic vessels* terminate in small groups of glands around the porta hepatis. Efferent vessels drain into glands around the coeliac axis. Some superficial hepatic lymphatics pass through the diaphragm in the falciform ligament and finally reach the mediastinal glands. Another group accompanies the inferior vena cava into the thorax and ends in a few small glands around the intrathoracic portion of the inferior vena cava.

The *inferior vena cava* makes a deep groove to the right of the caudate lobe about 2 cm from the midline.

The *gallbladder* lies in a fossa extending from the inferior border of the liver to the right end of the porta hepatis.

The liver is completely covered with peritoneum, except in three places. It comes into direct contact with the diaphragm through the bare area which lies to the

right of the fossa for the inferior vena cava. The other areas without peritoneal covering are the fossae for the inferior vena cava and gallbladder.

The liver is kept in position by peritoneal ligaments and by the intra-abdominal pressure transmitted by the tone of the muscles of the abdominal wall.

## Functional liver anatomy: sectors and segments

Based on the external appearances described earlier, the liver has a right and left lobe separated along the line of insertion of the falciform ligament. This separation, however, does not correlate with blood supply or biliary drainage. A *functional anatomy* is now recognized based upon vascular and biliary anatomy. The *Couinaud* classification [5] defines eight segments (segments I–IV in the left lobe, V–VIII in the right lobe), while the *Bismuth* classification [6] divides the liver into four sectors. These can be correlated with results seen with imaging techniques.

The main portal vein divides into right and left branches and each of these supplies two further subunits (variously called sectors). The sectors on the right side are anterior and posterior and, in the left lobe, medial and lateral

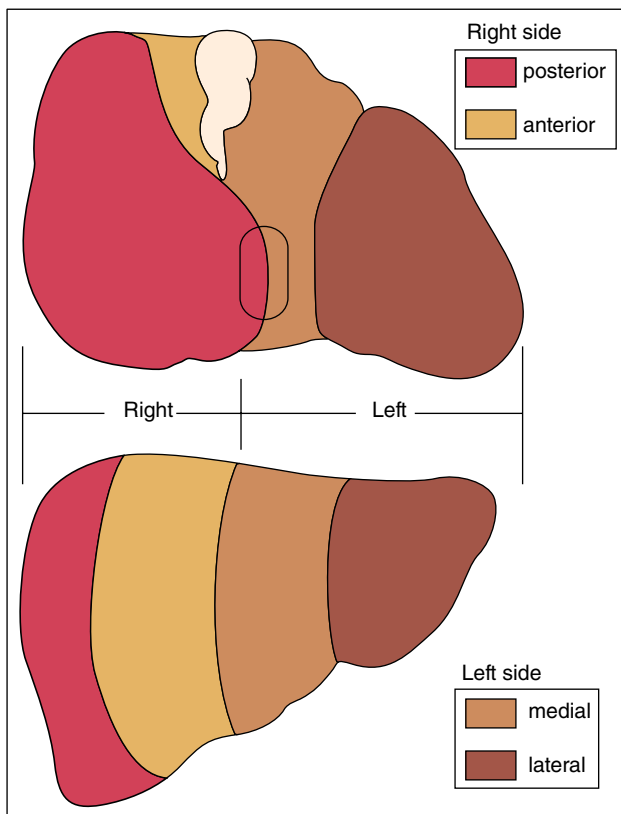


Fig. 1.4 The sectors of the human liver.

and lateral – giving a total of four sectors (Fig. 1.4). Using this definition, the right and left side of the liver are divided not along the line of the falciform ligament, but along a slightly oblique line to the right of this, drawn from the inferior vena cava above to the gallbladder bed below. The right and left side are independent with regard to portal and arterial blood supply, and bile drainage. Three planes separate the four sectors and contain the three major hepatic vein branches.

Closer analysis of these four hepatic sectors produces a further subdivision into segments (Fig. 1.5). The right anterior sector contains segments V and VIII; right posterior sector, VI and VII; left medial sector, IV; left lateral sector, II and III. There is no vascular anastomosis between the macroscopic vessels of the segments but communications exist at the sinusoidal level. Segment I, the equivalent of the caudate lobe, is separate from the other segments and does not derive blood directly from the major portal branches or drain by any of the three major hepatic veins.

This functional anatomical classification allows interpretation of radiological data and is of importance to the surgeon planning a liver resection. There are wide variations in portal and hepatic vessel anatomy which can be demonstrated by spiral computed tomography (CT) and magnetic resonance imaging (MRI) reconstruction [7].

## Anatomical abnormalities of the liver

These are being increasingly diagnosed with more widespread use of CT and ultrasound scanning.

*Accessory lobes.* The livers of the pig, dog, and camel are divided into distinct and separate lobes by strands of connective tissue. Occasionally, the human liver may

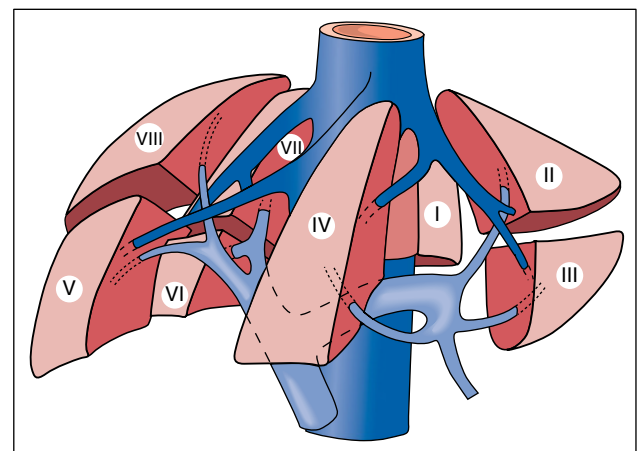


Fig. 1.5 Schematic representation of the functional anatomy of the liver. Three main hepatic veins (dark blue) divide the liver into four sectors, each of them receiving a portal pedicle; hepatic veins and portal veins are intertwined as the fingers of two hands [6].



show this reversion and up to 16 lobes have been reported. This abnormality is rare and without clinical significance. The lobes are small and usually on the undersurface of the liver so that they are not detected clinically but are noted incidentally at scanning, operation, or necropsy. Rarely, they are intrathoracic [8]. An accessory lobe may have its own mesentery containing hepatic artery, portal vein, bile duct, and hepatic vein. This may twist and demand surgical intervention.

*Ectopic liver.* Small nodules of normal liver derived from the embryologic hepatic bud may be found in less than 1% of laparoscopies and autopsies near the gallbladder, hepatic ligaments, gastrosplenic ligament, omentum, retroperitoneum, and thorax. These may give rise to hepatocellular carcinoma [9,10].

*Riedel's lobe.* This is fairly common and is a downward tongue-like projection of the right lobe of the liver [11]. It is a simple anatomical variation; it is not a true accessory lobe. The condition is more frequent in women. It is detected as a mobile tumour on the right side of the abdomen which descends with the diaphragm on inspiration. It may come down as low as the right iliac region. It is easily mistaken for other tumours in this area, especially a visceroperitoneal right kidney. It does not cause symptoms and treatment is not required. Rarely, it is a site for metastasis or primary hepatocellular carcinoma. Scanning may be used to identify Riedel's lobe and other anatomical abnormalities.

*Cough furrows on the liver.* These are vertical grooves on the convexity of the right lobe. They are one to six in number and run anteroposteriorly, being deeper posteriorly. These represent diaphragmatic sulci and fissures produced by pressure exerted by diaphragmatic muscle on peripheral structurally weak liver parenchymal zones associated with watershed vascular distribution [12]. Chronic cough produces such pressure.

*Corset liver.* This is a horizontal fibrotic furrow or pedicle on the anterior surface of one or both lobes of the liver just below the costal margin [13]. The mechanism is unknown, but it affects elderly women who have worn corsets for many years. It presents as an abdominal mass in front of and below the liver and is isodense with the liver. It may be confused with a hepatic tumour.

*Lobar atrophy.* Interference with the portal supply or biliary drainage of a lobe may cause atrophy. There is usually hypertrophy of the opposite lobe. Left lobe atrophy found at post-mortem or during scanning is not uncommon and is probably related to reduced blood supply via the left branch of the portal vein. The lobe is decreased in size with thickening of the capsule, fibrosis, and prominent biliary and vascular markings. The vascular problem may date from the time of birth. Loss of left lobe parenchyma in this instance develops by the process of ischaemic extinction due to impaired flow from the affected large portal vein branch. Replacement

fibrosis ensues. This large vessel extinction process should be distinguished from cirrhosis in which the entire liver is affected by numerous intrahepatic and discrete extinction lesions, which affect small hepatic veins and portal vein branches during the course of inflammation and fibrosis. Hence, in cirrhosis the entire liver surface is diffusely converted to regenerative parenchymal nodules surrounded by fibrosis.

Obstruction to the right or left hepatic bile duct by benign stricture or cholangiocarcinoma is now the most common cause of lobar atrophy [14]. The alkaline phosphatase is usually elevated. The bile duct may not be dilated within the atrophied lobe. Relief of obstruction may reverse the changes if cirrhosis has not developed. Distinction between a biliary and portal venous aetiology may be made using technetium-labelled iminodiacetic acid (IDA) and colloid scintiscans. A small lobe with normal uptake of IDA and colloid is compatible with a portal aetiology. Reduced or absent uptake of both isotopes favours biliary disease.

*Agensis of the right lobe* [15]. This rare lesion may be an incidental finding associated, probably coincidentally, with biliary tract disease and also with other congenital abnormalities. It can cause presinusoidal portal hypertension. The other liver segments undergo compensatory hypertrophy. It must be distinguished from lobar atrophy due to cirrhosis or hilar cholangiocarcinoma.

*Situs inversus (SI).* In the exceedingly rare *SI totalis* or *abdominalis* the liver is located in the left hypochondrium and may be associated with other anomalies including biliary atresia, polysplenia syndrome, aberrant hepatic artery anatomy, and absent portal vein. Hepatic surgery (partial hepatectomy, liver transplantation) is feasible, but complex. Other conditions associated with displacement of the liver from its location in the right upper quadrant include *congenital diaphragmatic hernias*, *diaphragmatic eventration*, and *omphalocele*.

Anatomical abnormalities of the gallbladder and biliary tract are discussed in Chapter 14.

## Anatomy of the biliary tract (Fig. 1.6)

The *right* and *left hepatic ducts* emerge from the liver and unite in the porta hepatis to form the *common hepatic duct*. This is soon joined by the *cystic duct* from the gallbladder to form the common bile duct.

The *common bile duct* runs between the layers of the lesser omentum, lying anterior to the portal vein and to the right of the hepatic artery. Passing behind the first part of the duodenum in a groove on the back of the head of the pancreas, it enters the second part of the duodenum. The duct runs obliquely through the posteromedial wall, usually joining the main pancreatic duct to form the *ampulla of Vater* (c. 1720). The ampulla makes the

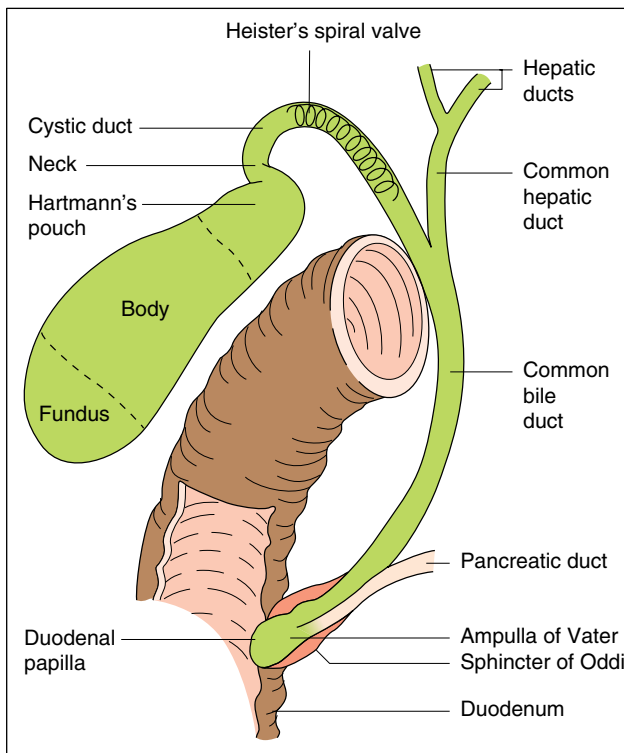


Fig. 1.6 Gallbladder and biliary tract.

mucous membrane bulge inwards to form an eminence, the *duodenal papilla*. In about 10–15% of subjects the bile and pancreatic ducts open separately into the duodenum.

The dimensions of the common bile duct depend on the technique used. At operation it is about 0.5–1.5 cm in diameter. Using ultrasound the values are less, the common bile duct being 2–7 mm, with values greater than 7 mm being regarded as abnormal. Using endoscopic cholangiography, the duct diameter is usually less than 11 mm, although after cholecystectomy it may be more in the absence of obstruction.

The duodenal portion of the common bile duct is surrounded by a thickening of both longitudinal and circular muscle fibres derived from the intestine. This is called the *sphincter of Oddi* (c. 1887).

The *gallbladder* is a pear-shaped bag 9 cm long with a capacity of about 50 mL. It always lies above the transverse colon, and is usually next to the duodenal cap overlying, but well anterior to, the right renal shadow. The fundus is the wider end and is directed anteriorly; this is the part palpated when the abdomen is examined. The body extends into a narrow neck which continues into the cystic duct. The *valves of Heister* are spiral folds of mucous membrane in the wall of the cystic duct and neck of the gallbladder. *Hartmann's pouch* is a sacculatation at the neck of the gallbladder; this is a common site for a gallstone to lodge.

The mucosa is in delicate, closely woven folds; instead of glands there are indentations of mucosa which usually lie superficial to the muscle layer. Increased intraluminal pressure in chronic cholecystitis results in formation of branched, diverticula-like invaginations of the mucosa which reach into the muscular layer, termed *Rokitansky–Aschoff sinuses*. There is no submucosa or muscularis mucosae. The gallbladder wall consists of a loose connective tissue lamina propria and muscular layer containing circular, longitudinal, and oblique muscle bundles without definite layers, the muscle being particularly well developed in the neck and fundus. The outer layers are the subserosa and serosa. The distensible normal gallbladder fills with bile and bile acids secreted by the liver, concentrates the bile through absorption of water and electrolytes and with meals contracts under the influence of cholecystikinin (acting through preganglionic cholinergic nerves) to empty bile into the duodenum.

**Blood supply.** The gallbladder receives blood from the *cystic artery*. This branch of the hepatic artery is large, tortuous, and variable in its anatomical relationships. Smaller blood vessels enter from the liver through the gallbladder fossa. The venous drainage is into the *cystic vein* and thence into the portal venous system. Attention to the vascular-biliary anatomy in the reference area known as *Calot's triangle* (bordered by the cystic duct, common hepatic duct, and lower edge of the liver) reduces the risk of vascular injuries and potential biliary strictures. Most bile duct injuries occur at cholecystectomy (incidence of <1.3% for either open or laparoscopic cholecystectomy). After liver transplantation 10–33% of patients may develop biliary complications, of which biliary stricture is the most important.

The arterial blood supply to the supraduodenal bile duct is generally by two main (axial) vessels which run beside the bile duct. These are supplied predominantly by the retroduodenal artery from below, and the right hepatic artery from above, although many other vessels contribute. This pattern of arterial supply would explain why vascular damage results in bile duct stricturing [16].

**Lymphatics.** There are many lymphatic vessels in the submucous and subperitoneal layers. These drain through the cystic gland at the neck of the gallbladder to glands along the common bile duct, where they anastomose with lymphatics from the head of the pancreas.

**Nerve supply.** The gallbladder and bile ducts are liberally supplied with nerves, from both the parasympathetic and the sympathetic system.

### Surface marking (Fig. 1.7, Fig. 1.8)

**Liver.** The upper border of the right lobe is on a level with the 5th rib at a point 2 cm medial to the right midclavicular line (1 cm below the right nipple). The upper border

of the left lobe corresponds to the upper border of the 6th rib at a point in the left midclavicular line (2 cm below the left nipple). Here only the diaphragm separates the liver from the apex of the heart.

The lower border passes obliquely upwards from the 9th right to the 8th left costal cartilage. In the right nipple line it lies between a point just under to 2 cm below the costal margin. It crosses the midline about midway between the base of the xiphoid and the umbilicus and the left lobe extends only 5 cm to the left of the sternum.

**Gallbladder.** Usually the fundus lies at the outer border of the right rectus abdominis muscle at its junction with the right costal margin (9th costal cartilage) (Fig. 1.8). In an obese subject it may be difficult to identify the outer border of the rectus sheath and the gallbladder may then be located by the Grey–Turner method. A line is drawn from the left anterior superior iliac spine through the umbilicus; its intersection with

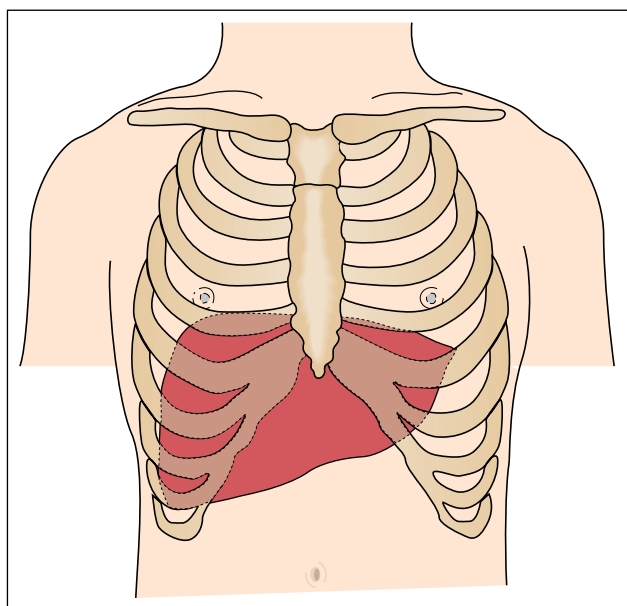


Fig. 1.7 The surface marking of the liver.

the right costal margin indicates the position of the gallbladder. These guidelines depend upon the individual's build. The fundus may occasionally be found below the iliac crest.

## Methods of examination

**Liver.** The lower edge should be determined by palpation just lateral to the right rectus muscle. This avoids mistaking the upper intersection of the rectus sheath for the liver edge.

The liver edge moves 1–3 cm downwards with deep inspiration. It is usually palpable in normal subjects inspiring deeply. The edge may be tender, regular or irregular, firm or soft, thickened or sharp. The lower edge may be displaced downwards by a low diaphragm, for instance in emphysema. Movements may be particularly great in athletes or singers. Some patients with practice become very efficient at 'pushing down' the liver. The normal spleen can become palpable in similar fashion. Common causes of a liver palpable below the umbilicus are malignant deposits, polycystic or Hodgkin disease, amyloidosis, congestive cardiac failure, and gross fatty change. Rapid change in liver size may occur when congestive cardiac failure is corrected, cholestatic jaundice relieved, or when severe diabetes is controlled. The surface can be palpated in the epigastrium and any irregularity or tenderness noted. An enlarged caudate lobe, as in the Budd–Chiari syndrome or with some cases of cirrhosis, may be palpated as an epigastric mass.

Pulsation of the liver, usually associated with tricuspid valvular incompetence, is felt by manual palpation with one hand behind the right lower ribs posteriorly and the other anteriorly on the abdominal wall.

The upper edge is determined by fairly heavy percussion passing downwards from the nipple line. The lower edge is recognized by very light percussion passing upwards from the umbilicus towards the costal margin. Percussion is a

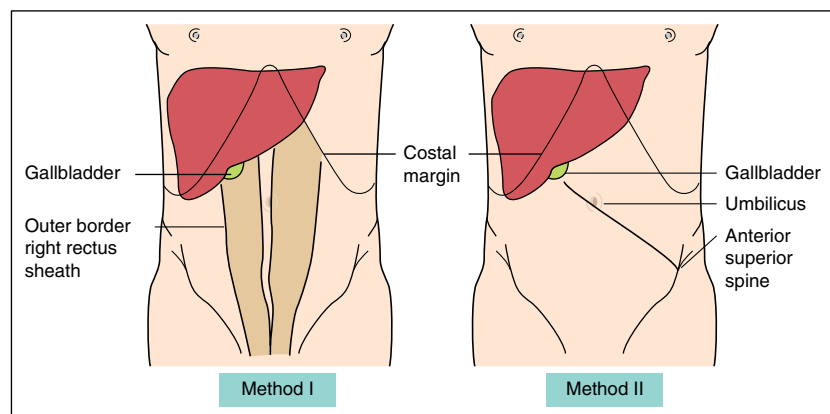


Fig. 1.8 Surface markings of the gallbladder. Method I: the gallbladder is found where the outer border of the right rectus abdominis muscle intersects the 9th costal cartilage. Method II: a line drawn from the left anterior superior iliac spine through the umbilicus intersects the costal margin at the site of the gallbladder.



valuable method of determining liver size and is the only clinical method of determining a small liver.

The anterior liver span is obtained by measuring the vertical distance between the uppermost and lowermost points of hepatic dullness by percussion in the right midclavicular line. This is usually 12–15 cm. Direct percussion is as accurate as ultrasound in estimating liver span [17].

Friction may be palpable and audible, usually due to recent biopsy, tumour, or perihepatitis. The venous hum of portal hypertension is audible between the umbilicus and the xiphisternum. An arterial murmur over the liver may indicate a primary liver cancer or acute alcoholic hepatitis.

**Gallbladder.** The gallbladder is palpable only when it is distended. It is felt as a pear-shaped cystic mass usually about 7 cm long. In a thin person, the swelling can sometimes be seen through the anterior abdominal wall. It moves downwards on inspiration and is mobile laterally but not downwards. The swelling is dull to percussion and directly impinges on the parietal peritoneum, so that the colon is rarely in front of it. Gallbladder dullness is continuous with that of the liver.

Abdominal tenderness should be noted. Inflammation of the gallbladder causes a positive *Murphy's sign*. This is the inability to take a deep breath when the examining fingers are hooked up below the liver edge. The inflamed gallbladder is then driven against the fingers and the pain causes the patient to catch their breath.

The enlarged gallbladder must be distinguished from a *viscerototic right kidney*. This, however, is more mobile, can be displaced towards the pelvis and has the resonant colon anteriorly. A *regenerative* or *malignant nodule* feels much firmer.

**Imaging.** A plain film of the abdomen, including the diaphragms, may be used to assess liver size and in particular to decide whether a palpable liver is due to actual enlargement or to downward displacement. On moderate inspiration the normal level of the diaphragm, on the right side, is opposite the 11th rib posteriorly and the 6th rib anteriorly.

Ultrasound, CT, or MRI can be used to study liver size, shape, and content.

## Microanatomy of the liver

For over a century, many models of liver substructure have been proposed [18]. The most popular of these is the *lobule* introduced by Kiernan in 1833 as the basic architectural unit, based on pig dissections [19]. He described circumscribed, hexagonal lobules consisting of a central tributary of the hepatic vein (central vein) and at the periphery a portal tract containing the bile

duct, portal vein radicle, and hepatic artery branch. Cords (plates) of liver cells and blood-containing sinusoids extend between these two systems. The lobule has foundations in pig, camel, raccoon, and polar bear livers, in which such hexagonal units are surrounded by interlobular connective tissue septa [20]. Such septa have no counterparts in human liver.

Stereoscopic reconstructions and scanning electron microscopy have shown the human liver as cords of liver cells radiating from a central vein, and interlaced in orderly fashion by sinusoids (Figs 1.9, 1.10). The terminal branches of the portal vein discharge their blood into the sinusoids and the direction of flow is determined by the higher pressure in the portal vein than in the central vein (or terminal hepatic venule) – see later.

The *portal tracts* are small connective tissue islands containing triads composed of the portal vein radicle, the hepatic arteriole, and bile duct (Fig. 1.11). Portal tracts are surrounded by a limiting plate of liver cells. Histological sections of normal liver show portal tracts containing dyads as frequently as triads, with the portal vein being the most frequently absent element. Within each linear centimetre of liver tissue obtained at biopsy there are usually two interlobular bile ducts, two hepatic arteries and one portal vein per portal tract, with six full portal triads [21].

The liver has to be divided *functionally*. Traditionally, the unit is based on a central hepatic vein and its surrounding liver cells. However, Rappaport [22] envisages a series of functional *acini*, each centred on the portal tract with its terminal branch of portal vein, hepatic artery, and bile duct (zone 1) (Fig. 1.12, Fig. 1.13). These interdigitate, mainly perpendicularly, with terminal hepatic veins of adjacent acini. The circulatory peripheries of acini (adjacent to terminal hepatic veins) (zone 3) suffer most from injury, whether viral, toxic, or anoxic. Bridging necrosis may extend from the periphery (acinar zone 1) to zone 3. The regions closer to the axis formed by afferent vessels and bile ducts survive longer and may later form the core from which regeneration will proceed. The contribution of each acinar zone to liver cell regeneration depends on the acinar location of damage [22].

The liver cells (*hepatocytes*) comprise about 60% of the liver. They are polygonal and approximately 30 µm in diameter. The nucleus is single or, less often, multiple and divides by mitosis. The lifespan of liver cells is about 150 days in experimental animals. The hepatocyte has three surfaces: one facing the sinusoid and space of Disse, the second facing the canaliculus, and the third facing neighbouring hepatocytes (Fig. 1.14). There is no basement membrane.

The sinusoids are lined by endothelial cells with small pores (fenestrae) for macromolecule diffusion from

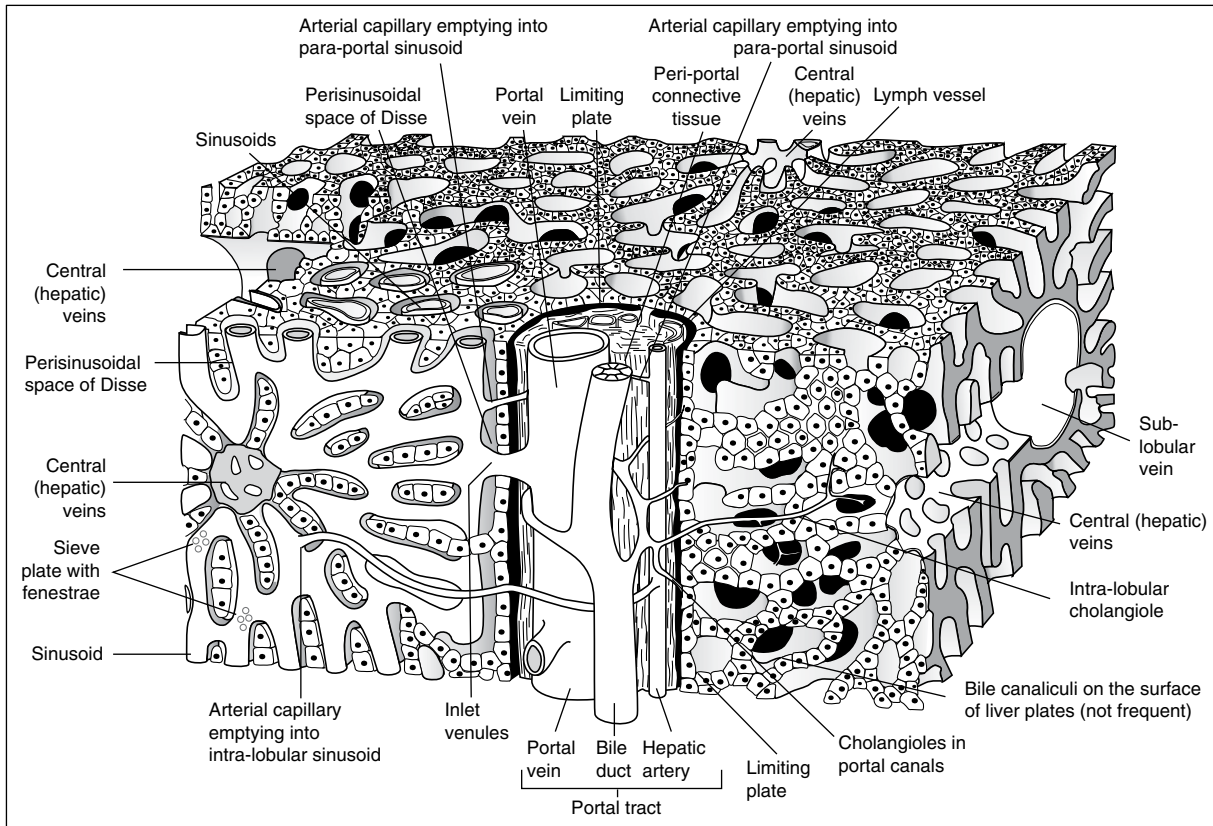


Fig. 1.9 The structure of the normal human liver.

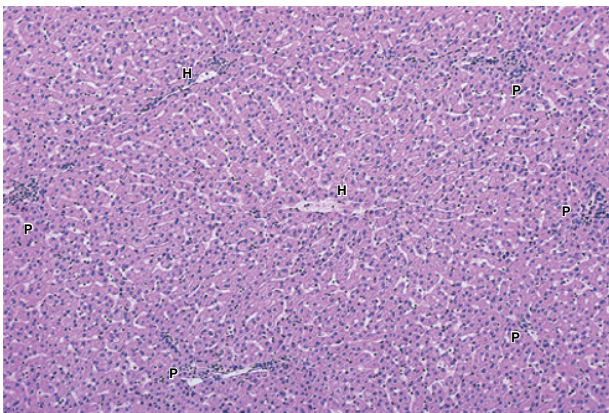


Fig. 1.10 Normal hepatic histology. H, terminal hepatic vein; P, portal tract. (H & E,  $\times 60$ .)

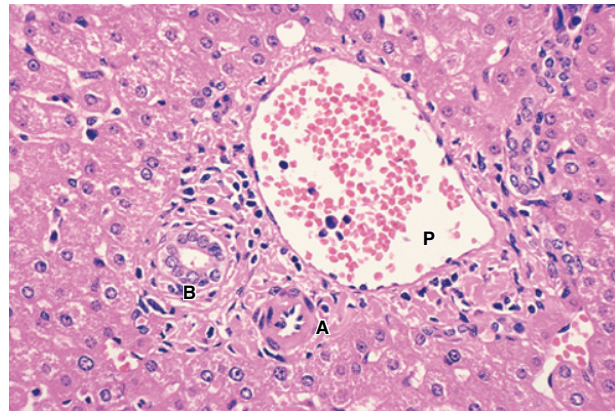
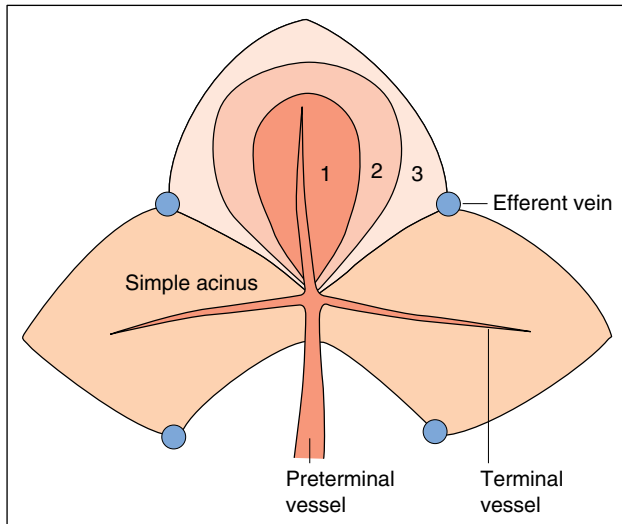


Fig. 1.11 Normal portal tract. A, hepatic artery; B, bile duct; P, portal vein. (H & E.)

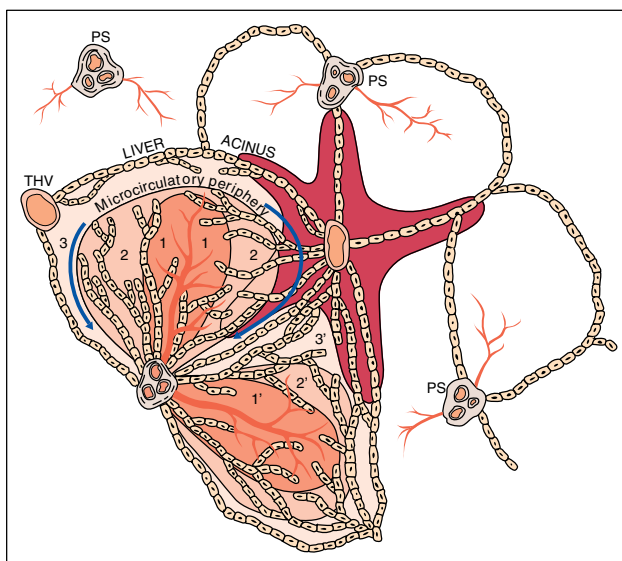
blood to hepatocytes. On the vascular side of the sinusoids are the phagocytic cells of the reticulo-endothelial system (Kupffer cells) and pit cells (NK or natural killer cells) which are cytotoxic lymphoid cells involved in surveillance for tumour cells and viral infections [23,24].

There are approximately  $202 \times 10^3$  cells in each milligram of normal human liver, of which  $171 \times 10^3$  are parenchymal and  $31 \times 10^3$  littoral (sinusoidal, including Kupffer cells).

The *space of Disse* between hepatocytes and sinusoidal endothelial cells contains a few collagen fibrils and the hepatic stellate cells, which have also been called fat-storing cells, Ito cells, and lipocytes. These cells store vitamin A and when activated in disease become collagen-synthesizing myofibroblasts. The *hepatic lymphatics* are found in the periportal connective tissue and are lined throughout by endothelium. Tissue fluid seeps through the endothelium into the lymph vessels.



**Fig. 1.12** The complex acinus according to Rappaport. Zone 1 is adjacent to the entry (portal venous) system. Zone 3 is adjacent to the exit (hepatic venous) system.



**Fig. 1.13** Blood supply of the simple liver acinus, zonal arrangements of cells and the microcirculatory periphery. The acinus occupies adjacent sectors of the neighbouring hexagonal fields. Zones 1, 2, and 3, respectively, represent areas supplied with blood of first, second, and third quality with regard to oxygen and nutrient content. These zones centre on the terminal afferent vascular branches, bile ductules, lymph vessels, and nerves (PS) and extend into the triangular portal field from which these branches crop out. Zone 3 is the microcirculatory periphery of the acinus since its cells are as remote from their own afferent vessels as from those of adjacent acini. The *perivenular* area is formed by the most peripheral portions of zone 3 of several adjacent acini. In injury progressing along this zone, the damaged area assumes the shape of a starfish (darker tint around a terminal hepatic venule [THV] in the centre). 1–3, microcirculatory zones; 1'–3', zones of neighbouring acinus [22].

The branch of the *hepatic arteriole* forms a plexus around the bile ducts and supplies the structures in the portal tracts. It empties into the sinusoidal network at different levels. There are no direct hepatic arteriolar–portal venous anastomoses.

The excretory system of the liver begins with the *bile canaliculi* (Fig. 1.14, Fig. 1.15). These are formed by modifications of the contact surfaces of liver cells and are covered by microvilli. The plasma membrane is reinforced by microfilaments forming a supportive cytoskeleton. The canalicular surface is sealed from the rest of the intercellular surface by junctional complexes including tight junctions, gap junctions, and desmosomes. The intralobular canalicular network drains into the canals of Hering lined by low cuboidal epithelium which connect via short bile ductules to the larger terminal bile ducts within the portal tracts. Bile ducts are classified into small (less than 100  $\mu\text{m}$  in diameter), medium (about 100  $\mu\text{m}$ ), and large (more than 100  $\mu\text{m}$ ) calibre types.

## Hepatic ultrastructure (electron microscopy) and organelle functions

**Hepatocytes** (Fig. 1.14, Fig. 1.15, Fig. 1.16, Fig. 1.17)

The liver cell margin is straight except for a few anchoring pegs (desmosomes). From it, equally sized and spaced microvilli project into the lumen of the bile canaliculi. Along the sinusoidal border, irregularly sized and spaced microvilli project into the perisinusoidal tissue space. The microvillous structure indicates active secretion or absorption, mainly of fluid.

The *nucleus* has a double contour with pores allowing interchange with the surrounding cytoplasm. Human liver after puberty contains tetraploid nuclei and, at about age 20, in addition, octoploid nuclei are found. Increased polyploidy has been regarded as precancerous. In the chromatin network one or more nucleoli are embedded.

The *mitochondria* also have a double membrane, the inner being invaginated to form grooves or cristae. An enormous number of energy-providing processes take place within them, particularly those involving oxidative phosphorylation. They contain many enzymes, particularly those of the citric acid cycle and those involved in  $\beta$ -oxidation of fatty acids. They can transform energy so released into adenosine diphosphate (ADP). Haem synthesis occurs here.

The *rough endoplasmic reticulum* (RER) is seen as lamellar structures lined by ribosomes. These are responsible for basophilia under light microscopy. They synthesize specific proteins, particularly albumin, those



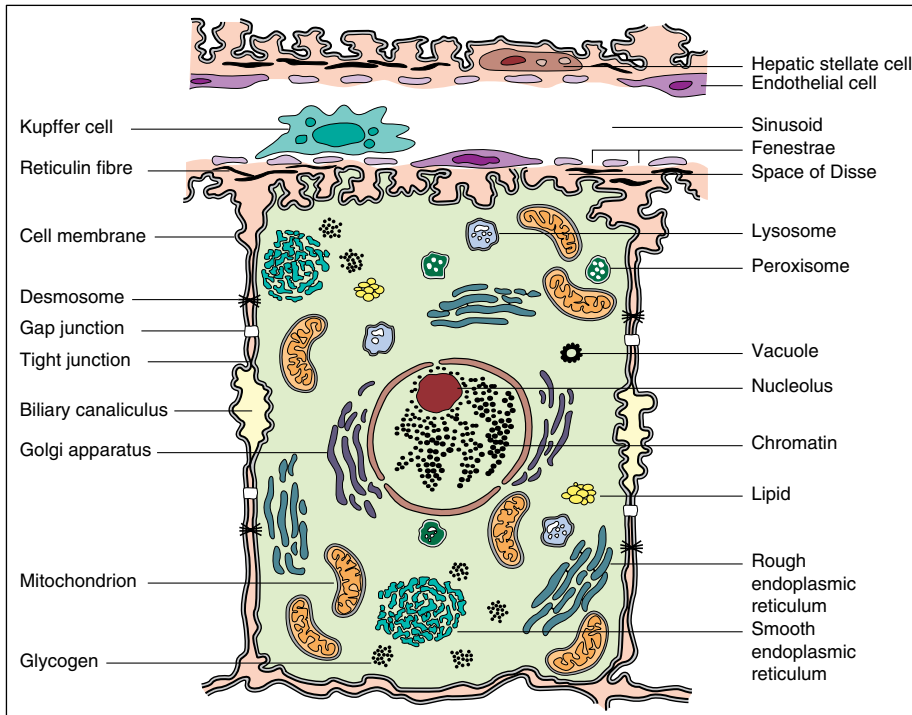


Fig. 1.14 The organelles of the liver cell.

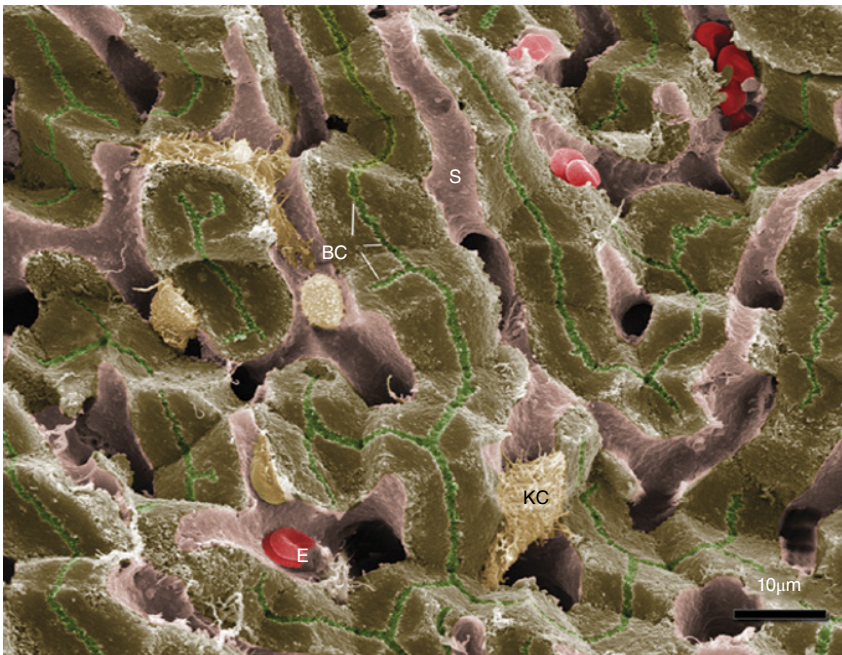
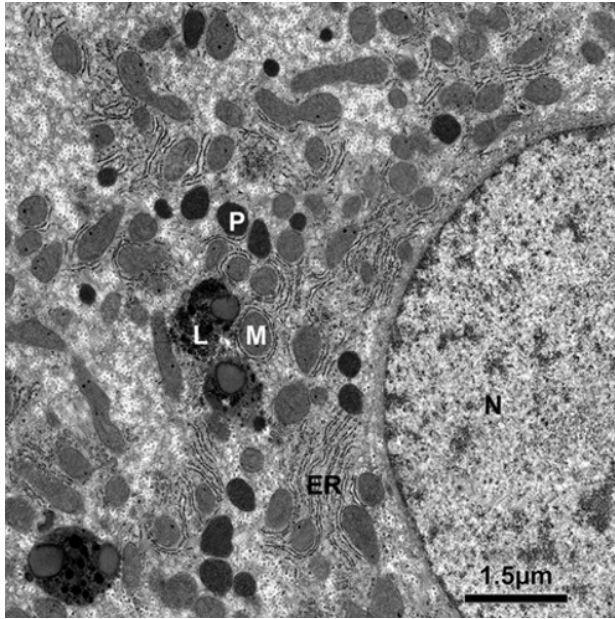


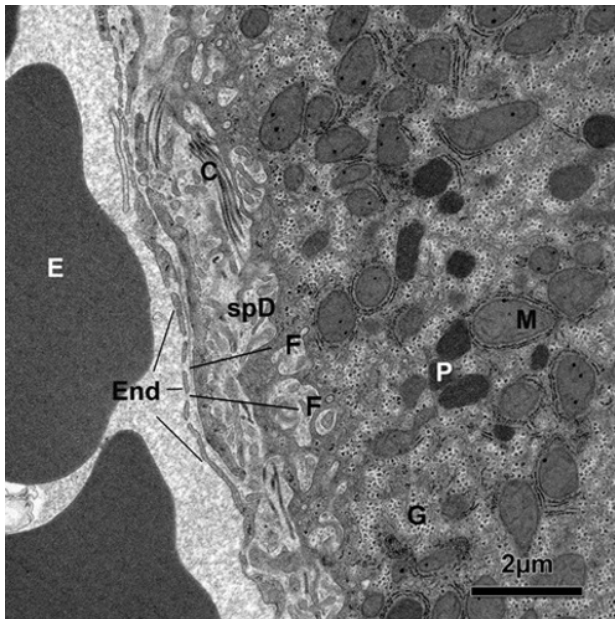
Fig. 1.15 Colourized scanning electron micrograph of liver showing hepatocytes in green, sinusoids (S) in light pink, erythrocytes (E), Kupffer cells (K), and bile canaliculi (BC). Courtesy of Ms Jackie Lewin, UCL Medical School, London.

used in blood coagulation and enzymes. They may adopt a helix arrangement, as polysomes, for coordination of this function. Glucose-6-phosphatase is synthesized. Triglycerides are synthesized from free fatty acids and complexed with protein to be secreted by exocytosis as lipoprotein. The RER may participate in glycogenesis.

The *smooth endoplasmic reticulum* (SER) forms tubules and vesicles. It contains the microsomes. It is the site of bilirubin conjugation and the detoxification of many drugs and other foreign compounds (P450 systems). Steroids are synthesized, including cholesterol and the primary bile acids, which are conjugated with the



**Fig. 1.16** Electron microscopic appearances of part of a normal human liver cell. N, nucleus; M, mitochondrion; P, peroxisome; L, lysosome; ER, rough endoplasmic reticulum. Courtesy of Ms Jackie Lewin, UCL Medical School, London.



**Fig. 1.17** Transmission electron micrograph showing an hepatocyte (right) with its microvillus membrane surface facing onto the space of Disse (spD) and the overlying endothelium (End). The endothelium has fenestrations (F) and there are a few collagen bundles (C) in the space of Disse. Erythrocytes (E) are present within the sinusoidal lumen. M, mitochondrion; P, peroxisome; G, glycogen granules. Courtesy of Ms Jackie Lewin, UCL Medical School, London.

amino acids glycine and taurine. The SER is increased by enzyme inducers such as phenobarbital.

*Peroxisomes* are versatile organelles, which have complex catabolic and biosynthetic roles, and are distributed near the SER and glycogen granules. Peroxisomal enzymes include simple oxidases,  $\beta$ -oxidation cycles, the glyoxalate cycle, ether lipid synthesis, and cholesterol and dolichol biosynthesis. Several disorders of peroxisomal function are recognized of which Zellweger syndrome is one [25]. Endotoxin severely damages peroxisomes [26].

The *lysosomes* are membrane-bound, electron-dense bodies adjacent to the bile canaliculi. They contain many hydrolytic enzymes which, if released, could destroy the cell. They are the site of deposition of ferritin, lipofuscin, bile pigment, copper, and senescent organelles.

The *Golgi apparatus* consists of a system of particles and vesicles, again lying near the canaliculus. It may be regarded as a 'packaging' site before excretion into the bile. This entire group of lysosomes, microbodies, and Golgi apparatus is a means of sequestering any material that is ingested and has to be excreted, secreted, or stored for metabolic processes in the cytoplasm. The Golgi apparatus, lysosomes, and canaliculi are concerned in cholestasis (Chapter 13).

The intervening cytoplasm contains granules of glycogen, lipid, and ferritin.

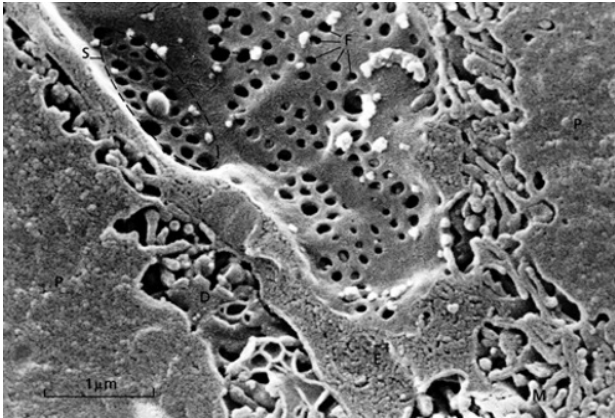
The *cytoskeleton* supporting the hepatocyte consists of microtubules, microfilaments, and intermediate filaments [27]. Microtubules contain tubulin and control subcellular mobility, vesicle movement, and plasma protein secretion. Microfilaments are made up of actin, are contractile and are important for the integrity and motility of the canaliculus and for bile flow. Intermediate filaments are elongated branched filaments comprising cytokeratins [1]. They extend from the plasma membrane to the perinuclear area and are fundamental for the stability and spatial organization of the hepatocyte. They become disrupted or lost with hepatocellular injury by alcohol, lipid peroxidation by-products, and ischaemia [28].

### Sinusoidal cells

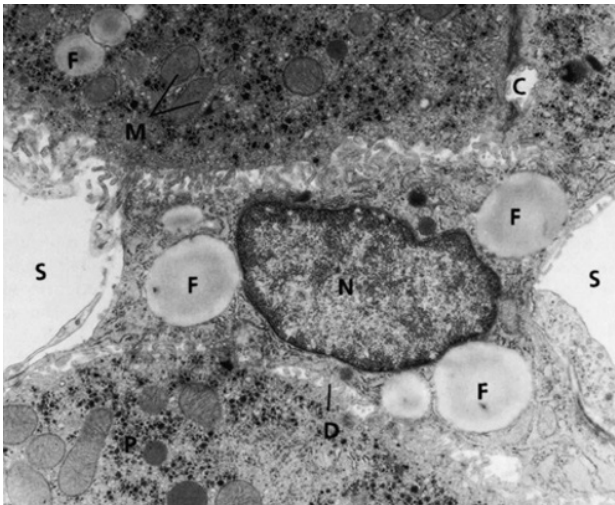
The sinusoidal cells (endothelial cells, Kupffer cells, hepatic stellate cells, and pit cells) form a functional and histological unit together with the sinusoidal aspect of the hepatocyte [29]. These cells interact via cytokines and other signalling mechanisms [30,31]. The close structural relationship of sinusoidal cells to hepatic cords is evident on transmission (Fig. 1.17) and scanning electron microscopy (Fig. 1.15).

Endothelial cells line the sinusoids and have fenestrae, which provide a graded barrier between the sinusoid and space of Disse (Fig. 1.18). The Kupffer cells anchor on the endothelium by their cytoplasmic projections.





**Fig. 1.18** Scanning electron micrograph of sinusoid showing fenestrae (F) grouped into sieve plates (S). D, space of Disse; E, endothelial cell; M, microvilli; P, parenchymal cell. Courtesy of Professor E. Wisse.



**Fig. 1.19** Transmission electron micrograph of an hepatic stellate cell. Note the characteristic fat droplets (F). C, bile canaliculus; D, space of Disse; M, mitochondria; N, nucleus; P, parenchymal cell; S, lumen of sinusoid. ( $\times 12\,000$ ) Courtesy of Professor E. Wisse.

The hepatic stellate cells lie in the space of Disse between the hepatocytes and the endothelial cells (Fig. 1.19). *Disse's space* contains tissue fluid which flows outwards into lymphatics in the portal zones. When sinusoidal pressure rises, lymph production in Disse's space increases and this plays a part in ascites formation where there is hepatic venous outflow obstruction.

**Endothelial cells.** These cells form a continuous lining to the sinusoids. They differ from endothelial cells elsewhere in not having a regular basement membrane. The endothelial cells act as a sieve between the sinusoid and space of Disse, have specific and non-specific endocytotic activity and have a variety of receptors. Their capacity to act as a sieve is due to fenestrae, around  $0.15\ \mu\text{m}$  in

diameter (Fig. 1.18). These make up 6–8% of the total endothelial cell surface, and there are more in the centrilobular zone of the sinusoid than the periportal area. Extracellular matrix affects their function.

Fenestrae are clustered into sieve plates, and act as bio-filters and transport pores between sinusoidal blood and the plasma within the space of Disse. They have a dynamic cytoskeleton [32]. This maintains and regulates their size, which can be changed by many influences including alcohol, nicotine, serotonin, endotoxin, and partial hepatectomy. The fenestrae filter macromolecules of differing size. Particles greater than  $0.2\ \mu\text{m}$  in diameter, which include large triglyceride-rich parent chylomicrons, will not pass. Smaller triglyceride-depleted, cholesterol-rich, and retinol-rich remnants can enter the space of Disse [33]. In this way the fenestrae have an important role in chylomicron and lipoprotein metabolism. Open fenestrae, which are located in the thin cytoplasmic periphery of the endothelial cells while close to the endothelial nuclei fenestrae, are multifolded and labyrinth-like [34].

Endothelial cells have a high capacity for endocytosis (accounting for 45% of all pinocytotic vesicles in the liver) and are active in clearing macromolecules and small particles from the circulation [35]. Coated and uncoated membrane-bound vesicles on endothelium are present near their nuclei or on non-fenestrated portions of their cytoplasm [36]; these are involved in various endocytic functions. There is receptor-mediated endocytosis for several molecules including transferrin, caeruloplasmin, modified high-density lipoprotein (HDL) and low-density lipoprotein (LDL), hepatic lipase and very low-density lipoprotein (VLDL). Hyaluronan (a major polysaccharide from connective tissue) is taken up and this provides a method for assessing hepatic endothelial cell capacity. Endothelial cells can also clear small particles ( $<0.1\ \mu\text{m}$ ) from the circulation, as well as denatured collagen. Scanning electron microscopy has shown a striking reduction in the number of fenestrae, particularly in zone 3 in alcoholic patients, with formation of a basal lamina, which is also termed capillarization of the sinusoid [37].

**Kupffer cells.** These are highly mobile macrophages attached to the endothelial lining of the sinusoid, in greater numbers in the periportal areas [38]. They have microvilli and intracytoplasmic-coated vesicles and dense bodies which make up the lysosomal apparatus. They proliferate locally but under certain circumstances macrophages can immigrate from an extrahepatic site. They are responsible for removing old and damaged blood cells or cellular debris, also bacteria, viruses, parasites, and tumour cells. They do this by endocytosis (phagocytosis, pinocytosis), including absorptive (receptor-mediated) and fluid phase (non-receptor-mediated)