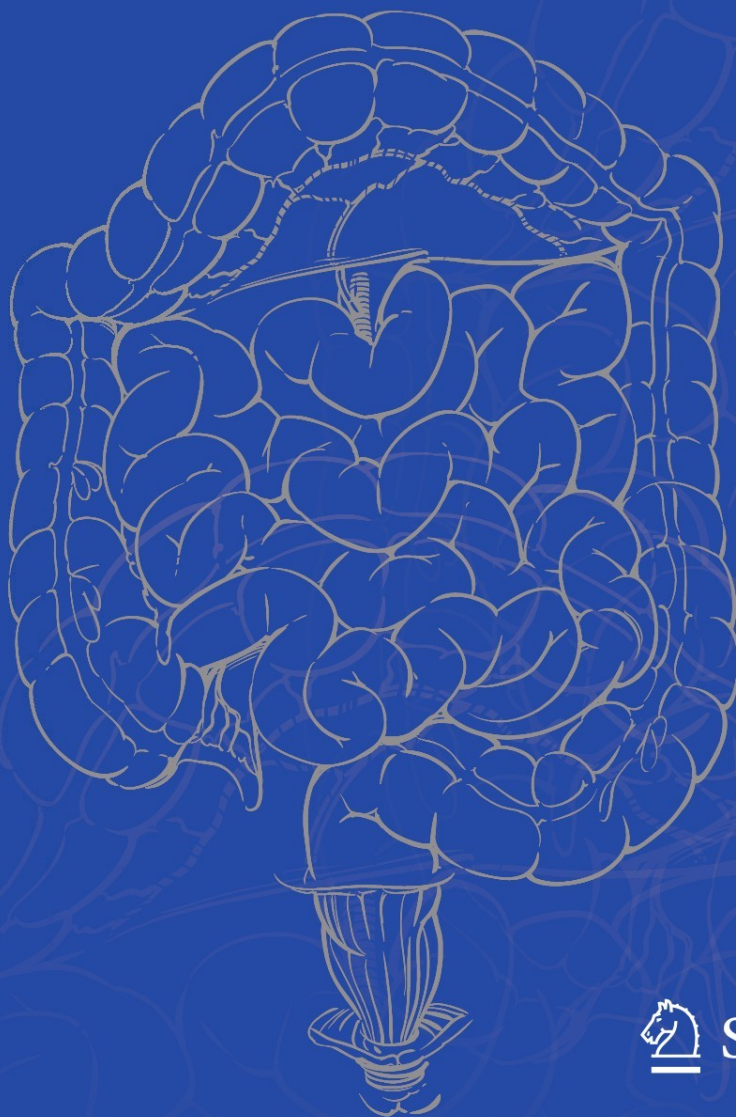


Victor W. Fazio
James M. Church
James S. Wu
Editors

Atlas of Intestinal Stomas



 Springer

Atlas of Intestinal Stomas

Victor W. Fazio • James M. Church • James S. Wu
Editors

Atlas of Intestinal Stomas

 Springer

Editors

Victor W. Fazio, A.O., M.B., B.S., M.S.,
F.R.A.C.S., F.R.A.C.S. (Hon), F.A.C.S., F.R.C.S
(E. Hon), F.R.C.S (Ed. Hon), M.D. (Pol. Hon),
F.R.C.S.I. (Hon)
Department of Colorectal Surgery
Digestive Diseases Institute
Cleveland Clinic Lerner College
of Medicine of Case Western
Reserve University
Cleveland Clinic Foundation
Cleveland, OH
USA
faziov@ccf.org

James S. Wu, Ph.D., M.D.
Department of Colorectal Surgery
Digestive Disease Institute
Cleveland Clinic Foundation
Cleveland, OH
USA
wuj@ccf.org

James M. Church, B.Sc. (Hum Bio), M.B. Ch.B.,
M.Med. Sci. (Anatomy), F.R.A.C.S.
Department of Colorectal Surgery
Digestive Disease Institute
Cleveland Clinic Foundation
Cleveland, OH
USA
churchj@ccf.org

ISBN 978-0-387-78850-0 e-ISBN 978-0-387-78851-7

DOI 10.1007/978-0-387-78851-7

Springer New York Dordrecht Heidelberg London

Library of Congress Control Number: 2011933843

© Springer Science+Business Media, LLC 2012

All rights reserved. This work may not be translated or copied in whole or in part without the written permission of the publisher (Springer Science+Business Media, LLC, 233 Spring Street, New York, NY 10013, USA), except for brief excerpts in connection with reviews or scholarly analysis. Use in connection with any form of information storage and retrieval, electronic adaptation, computer software, or by similar or dissimilar methodology now known or hereafter developed is forbidden.

The use in this publication of trade names, trademarks, service marks, and similar terms, even if they are not identified as such, is not to be taken as an expression of opinion as to whether or not they are subject to proprietary rights.

While the advice and information in this book are believed to be true and accurate at the date of going to press, neither the authors nor the editors nor the publisher can accept any legal responsibility for any errors or omissions that may be made. The publisher makes no warranty, express or implied, with respect to the material contained herein.

Printed on acid-free paper

Springer is part of Springer Science+Business Media (www.springer.com)

*This book is dedicated first and foremost to our late mentors,
Dr. Rupert B. Turnbull, Jr., M.D. and Frank L. Weakley, M.D.
And to Dr. Fazio's grandchildren, Halle, Kisandra, Griffin, James
Hunter and Talon, to Dr. Church's grandchildren, James and Olivia;
and to Dr. Wu's family, Margaret and Michelle.*




Fig. 1 Rupert B. Turnbull, Jr.



Fig. 2 Frank L. Weakley



Fig. 3 Norma N. Gill, the first director of the Cleveland Clinic Foundation School of Enterostomal Therapy

Preface

The first edition of the *Atlas of Intestinal Stomas* by Rupert B. Turnbull (Fig. 1) and Frank L. Weakley (Fig. 2) was published in 1967 specifically to provide the practicing intestinal surgeon access to the techniques of ostomy construction. The principles leading to methods that worked were products of centuries-old experiences of surgeons around the world. Many of the techniques selected for illustration by Turnbull and Weakley are still standard in clinical practice. However, in the 43 years since the publication of the first edition, new procedures and new techniques have emerged. These advances stimulated us to update the Turnbull/Weakley Atlas with the *Atlas of Intestinal Stomas*. Additions include chapters on anatomy and physiology, biliary stomas, pediatric ostomies, the continent ileostomy, urostomy, laparoscopic stoma construction, stomas in trauma surgery, stomas for antegrade continence enema, percutaneous ostomies, and quality of life. There are also updated sections on ileostomy, colostomy, enterostomal therapy (Fig. 3), and on the management of complications of stomas such as management of the high output ostomy, enterocutaneous fistula, parastomal hernia, prolapse, and skin conditions. We also have included a chapter on particularly challenging stomas that we hope will be particularly helpful for surgeons faced with difficult circumstances.

This new edition differs from the first in that it is multi-authored. However, each chapter is written with a clarity and directness that is similar to the original.

The Turnbull/Weakley Atlas was illustrated by a single artist, Robert M. Reed, former head of the Cleveland Clinic Medical Illustration Department. *Atlas of Intestinal Stomas* is illustrated entirely by Joe Pangrace and his staff of the same department. Pangrace, mentored by Reed early in his career, has developed his own style of illustration that we describe as accurate, crisp, and beautiful.

Few of the contributing authors to the *Atlas of Intestinal Stomas* had the privilege of working closely with our “well diggers,” Drs. Turnbull and Weakley. Those of us who did believe that they would be pleased with our work.

Victor W. Fazio, M.D.
James M. Church, M.D.
James S. Wu, M.D.

Acknowledgments

The editors acknowledge first the Cleveland Clinic Foundation for its enthusiastic support of this work. In particular, we acknowledge Ann Paladino, Director of the Cleveland Clinic Center for Medical Art and Photography and members of her team whose talent, skill, and efforts made this project possible. We thank Joe Pangrace, CMI; William Garriott; Elizabeth Halasz, CMI; and Wendy Knapp for their ability to clearly convey, through illustration, the surgical and medical concepts of this surgical atlas. We extend our appreciation to Kathleen Miller for digitalizing the quality of photographic slides and historical photos. We thank Jeffrey Loerch for processing licenses for hundreds of Cleveland Clinic illustrations and photographic works. We thank Joyce Balliet of the Department of Colorectal Surgery for her extensive photographic contributions to the book. We thank Marty Hodgson of the Department of Colorectal Surgery for her tireless support of this work over many years. We thank the Staff of the Cleveland Clinic Library for providing superlative access to the literature. We acknowledge each of the authors to this work who have selflessly given their knowledge, experience, and time. We thank Mr. Sreejith Viswanathan, Ms. Sajeni Ravindranathadas, and Ms. Vinitha Vipin our Project Managers at SPi Global for constructing the book. We gratefully thank our editors at Springer, Maureen Pierce, Paula Callaghan, Andy Kwan, Susan Westendorf, and Richard Hruska, who, with limitless patience and gentle nudging, guided us from drawing table to a completed work. Without the contributions of these individuals and their offices, this Atlas would not have been possible.



Fig. 4 Joseph A. Pangrace, CMI

For the past 28 years, Joseph Pangrace (Fig. 4) has applied his knowledge and skill as a medical illustrator for the Cleveland Clinic. Upon graduating in 1983 from the Cleveland Institute of Art's Medical Illustration program, he immediately began working at the Clinic, creating illustrations for use in publications, presentations, and videos. Over the course of his career, Pangrace's works have been published in major medical journals, textbooks, and atlases. In 2001, Pangrace assumed the responsibilities of Senior Medical Illustrator and Art Director for the *Cleveland Clinic Journal of Medicine*. In 2005, he was awarded the Association of Medical Illustrators' Max Bröedel award for continuous tone illustration. Pangrace currently acts as the Medical Illustration section leader for the Center for Medical Art and Photography. His artwork and that of his staff consistently reach the highest standards. We are indebted to Pangrace for his monumental contribution to the *Atlas of Intestinal Stomas*.

Victor W. Fazio, M.D.
James M. Church, M.D.
James S. Wu, M.D.

Contents

1 Intestinal Stomas: Historical Overview	1
James S. Wu	
2 Gastrointestinal Anatomy	39
Richard L. Drake and Jennifer M. McBride	
3 Structure and Function of the Large Bowel	47
Ann E. Brannigan and James M. Church	
4 Physiologic and Metabolic Effects of Intestinal Stomas	59
John Rombeau	
5 Quality of Life of the Ostomate	69
Meagan M. Costedio and James I. Merlino	
6 Wound, Ostomy, and Continence/Enterostomal Therapy (WOC/ET) Nursing	75
Paula Erwin-Toth, Barbara Hocevar, and Linda J. Stricker	
7 Ileostomy	85
Luca Stocchi	
8 Medical Management of the High-Output Enterostomy and Enterocutaneous Fistula	97
Neha Parekh and Douglas L. Seidner	
9 Intestinal Stomas and the Biliary Tree	111
Michael D. Johnson and John Fung	
10 Continent Ileostomy	113
Ravi Pokala Kiran and Victor W. Fazio	
11 Colostomy: Types, Indications, Formation, and Reversal	127
Thomas Garofalo	
12 Laparoscopic Ostomy Surgery	147
Daniel P. Geisler and Hermann Kessler	
13 Ostomies in Trauma	151
Matthew C. Byrnes and Greg J. Beilman	
14 CCF Color Photo Gallery	159
Victor W. Fazio, Paula Erwin-Toth, James M. Church, and James S. Wu	
15 Stomas Via Percutaneous Endoscopy	177
Michelle D. Inkster and John J. Vargo II	

16	Gastrointestinal Stomas in Infants and Children	191
	David K. Magnuson and Oliver S. Soldes	
17	Antegrade Colonic Enema (ACE)	207
	Brooke Gurland, Crina V. Floruta, and Ian C. Lavery	
18	Urinary Stomas	213
	Amit R. Patel and Amr F. Fergany	
19	Enterocutaneous Fistula	231
	Hasan T. Kirat and Feza H. Remzi	
20	Parastomal Hernia	237
	Matthew F. Kalady and Ian C. Lavery	
21	Surgical Treatment of Peristomal Skin Conditions	245
	Eoghan Condon and David Dietz	
22	Stoma Prolapse	249
	Ursula M. Szmulowicz and Tracy A. Hull	
23	Challenging Stomas	273
	Ryan S. Williams and Victor W. Fazio	
Index	285

Contributors

Greg J. Beilman, M.D. Department of Surgery, University of Minnesota, Minneapolis, MN, USA

Ann E. Brannigan, M.Ch., F.R.C.S.I., F.R.C.S. Mater Misericordiae University Hospital, Dublin, Ireland

Matthew C. Byrnes, M.D. Department of Surgery, University of Minnesota, Minneapolis, MN, USA

James M. Church, B.Sc. (Hum Bio), M.B. Ch.B., M.Med. Sci. (Anatomy), F.R.A.C.S. Department of Colorectal Surgery, Digestive Diseases Institute, Cleveland Clinic Foundation, Cleveland, OH, USA

Eoghan Condon, M.B., B.Ch., B.A.O., F.R.C.S.I., M.D. Department of Surgery, Limerick University Hospital, Limerick, Ireland

Meagan M. Costedio, M.D. Department of Colorectal Surgery, Digestive Disease Institute, Cleveland Clinic Foundation, Cleveland, OH, USA

David Dietz, M.D., F.A.C.S., F.A.S.C.R.S. Department of Colorectal Surgery, Digestive Disease Institute, Cleveland Clinic Foundation, Cleveland, OH, USA

Richard L. Drake, Ph.D. Cleveland Clinic Lerner College of Medicine of Case Western Reserve University, Cleveland, OH, USA

Paula Erwin-Toth, M.S.N., R.N., E.T., C.W.O.C.N., C.N.S. The Rupert B. Turnbull School of WOC/ET, Cleveland Clinic/ET, Cleveland, OH, USA

Victor W. Fazio, A.O., M.B., B.S., M.S., F.R.A.C.S., F.R.A.C.S. (Hon), F.A.C.S., F.R.C.S (E. Hon), F.R.C.S (Ed. Hon), M.D. (Pol. Hon), F.R.C.S.I. (Hon) Department of Colorectal Surgery, Digestive Diseases Institute, Cleveland Clinic Lerner College of Medicine of Case Western Reserve University, Cleveland Clinic Foundation, Cleveland, OH, USA

Amr F. Fergany, M.D., Ph.D. Glickman Urological and Kidney Institute, Cleveland Clinic Foundation, Cleveland, OH, USA

Crina V. Floruta, M.S.N., C.N.P., C.W.O.C.N. Department of Colorectal Surgery, Digestive Disease Institute, Cleveland Clinic Foundation, Cleveland, OH, USA

John Fung, M.D., Ph.D. Digestive Disease Institute, Transplant Center, Cleveland Clinic Lerner College of Medicine, Cleveland Clinic Foundation, Cleveland, OH, USA

Thomas Garofalo, M.D., F.A.C.S. Department of Colorectal Surgery, Digestive Disease Institute, Cleveland Clinic Foundation, Cleveland, OH, USA

Daniel P. Geisler, M.D. West Penn Allegheny Health System, Pittsburgh, PA, USA

Brooke Gurland, M.D. Department of Colorectal Surgery, Digestive Disease Institute, Cleveland Clinic Foundation, Cleveland, OH, USA

Barbara Hocevar, B.S.N., R.N., C.W.O.C.N. Nursing Institute/Digestive Disease Institute, Cleveland Clinic/ET, Cleveland, OH, USA

Tracy A. Hull, M.D. Department of Colon and Rectal Surgery, Digestive Disease Institute, Cleveland Clinic Foundation, Cleveland, OH, USA

Michelle D. Inkster, M.D., Ph.D. Digestive Disease Institute, Cleveland Clinic Foundation, Cleveland, OH, USA

Michael D. Johnson, M.D. The Nebraska Medical Center, Surgical Services of the Great Plains, P.C., Omaha, NE, USA

Matthew F. Kalady, M.D., F.A.C.S., F.A.S.C.R.S. Department of Colorectal Surgery, Cleveland Clinic, Cleveland, OH, USA

Hermann Kessler, M.D., Ph.D. Department of Surgery, University of Erlangen, Erlangen, Germany

Ravi Pokala Kiran, M.B.B.S., M.S., F.R.C.S. (Eng), F.R.C.S. (Glas), F.A.C.S., F.A.S.C.R.S. Department of Colorectal Surgery, Digestive Disease Institute, Cleveland Clinic Foundation, Cleveland, OH, USA

Hasan T. Kirat, M.D. Department of Colorectal Surgery, Digestive Disease Institute, Cleveland Clinic Foundation, Cleveland, OH, USA

Ian C. Lavery, M.B.B.S., F.A.C.S. Department of Colorectal Surgery, Digestive Disease Institute, Cleveland Clinic Foundation, Cleveland, OH, USA

David K. Magnuson, M.D. Department of Pediatric Surgery, Cleveland Clinic Foundation, Cleveland, OH, USA

Jennifer M. McBride, Ph.D. Cleveland Clinic Lerner College of Medicine of Case Western Reserve University, Cleveland, OH, USA

James I. Merlino, M.D., F.A.C.S., F.A.S.C.R.S. Department of Colorectal Surgery, Digestive Disease Institute, Cleveland Clinic Foundation, Cleveland, OH, USA

Neha Parekh, M.S., R.D., L.D., C.N.S.D. Intestinal Rehabilitation and Transplant Nutrition, Digestive Disease Institute, Cleveland Clinic Foundation, Cleveland, OH, USA

Amit R. Patel, M.D. Urologic Oncology, University of Chicago Medical Center, Chicago, IL, USA

Feza H. Remzi, M.D., F.A.C.S., F.A.S.C.R.S. Department of Colorectal Surgery, Digestive Disease Institute, Cleveland Clinic Foundation, Cleveland, OH, USA

John Rombeau, M.D. Department of Veterans Affairs, Palo Alto Health Care System, Palo Alto, CA, USA

Douglas L. Seidner, M.D., F.A.C.G., C.N.S.P. Division of Gastroenterology, Hepatology and Nutrition, Vanderbilt Center for Human Nutrition, Vanderbilt University Medical Center, Nashville, TN, USA

Oliver S. Soldes, M.D., F.A.C.S., F.A.A.P. Department of Pediatric Surgery, Cleveland Clinic Foundation, Cleveland, OH, USA

Luca Stocchi, M.D., F.A.C.S., F.A.S.C.R.S. Department of Colorectal Surgery, Digestive Disease Institute, Cleveland Clinic Foundation, Cleveland, OH, USA

Linda J. Stricker, M.S.N/E.D., R.N., C.W.O.C.N., L.N.C. WOC Nursing Education, Cleveland Clinic/ET, Cleveland, OH, USA

Ursula M. Szmulowicz, M.D. Department of Colorectal Surgery, Cleveland Clinic Foundation, Cleveland, OH, USA

John J. Vargo II, M.D., M.P.H: A.G.A.F., F.A.C.P., F.A.C.G., F.A.S.G.E. Department of Gastroenterology and Hepatology, Digestive Disease Institute, Cleveland Clinic Foundation, Cleveland, OH, USA

Ryan S. Williams, M.D. Department of Colorectal Surgery, Digestive Diseases Institute, Cleveland Clinic Lerner College of Medicine of Case Western Reserve University, Cleveland Clinic Foundation, Cleveland, OH, USA

James S. Wu, Ph.D., M.D. Department of Colorectal Surgery, Digestive Disease Institute, Cleveland Clinic Foundation, Cleveland, OH, USA

James S. Wu

Introduction

The word “stoma” is derived from the Greek, *stomat*, for mouth [1]. Gastrointestinal stomas are artificial connections of the gut to the skin. Reports of colostomies designed to relieve obstruction appear in the eighteenth century (Table 1.1) [1–21]. Small intestinal stomas are associated most closely with the twentieth century operations devised to treat inflammatory bowel, urologic, pediatric, and hepatobiliary conditions.

Ostomies of the stomach were introduced to decompress the gut or to instill nutrition. This chapter recognizes contributions of pioneers from many disciplines whose work improved the lives of gastrointestinal stoma patients.

Anus Praeternaturalis, Künstlichen Afters, Anus Artificiel, Abdominal Anus [18]

Caelii Aureliani

Celerum Vel Acutarum Passionum [19]

De Acuto Tormento, Quod Graeci Ileon Appellant [20]

Tormentum dictum est quod existiment aegrotantes convolvi atque torqueri suorum intestinorum verticula, vel quod spiritus ob abstinentiam clausus sese involvens vinctiones atque tormenta efficiat, vel quod vehementia dolorum supra eas partes quae patiuntur aegrotantes arcuati convolutique plicentur.

Caelius Aurelianus

On Swift or Acute Diseases [21]

Acute Intestinal Obstruction (Greek ILEOS) [22]

Intestinal obstruction (*tormentum*, “ileus”) gets its name either because the patient has a feeling that the folds of his intestines are tied up and twisted; or because the pneuma is blocked and shut off, the resulting involution of the flow producing cramps and twisting pains; or else because the violent pains over the parts affected cause the patient to be bent over, twisted, and doubled up.

The agony of intestinal obstruction has been recognized since antiquity. Treatments described by Caelius Aurelianus [23] were predominantly supportive and included: rest, fasting, wine, venesection, the application of mild heat to relieve the pain, clysters (enemas), hernia reduction, emetics, and

the ingestion of a lead pill to drive out the obstructing matter [24]. Caelius attributes a surgical solution for intestinal obstruction to Praxagorus of Cos, a surgeon who reportedly lived in the fourth century BC [25].

Praxagoras tertio libro Curationum clysterem iubet adhiberi, dans medicamina purgativae virtutis, atque per vomitum corpora dissecari [26].

Item confectis quibusdam supradictis adiutoriis dividendum probat pubetenus, dividendum etiam intestinum rectum atque detracto stercore consuendum dicit, in protervam veniens chirurgiam [28].

In Book III of his work *On Treatments*, Praxagorus prescribes a clyster, purgative drugs, and emetics to dry out the body [27].

And in some cases, after the procedures already described have been carried out, Praxagorus recommends making an incision in the pubic region, then cutting open the rectum, removing the excrement, and sewing up [the rectum and the abdomen] [29].

J.S. Wu

Department of Colorectal Surgery, Digestive Disease Institute,
Cleveland Clinic Foundation, Cleveland, OH, USA
e-mail: wuj@ccf.org

Surgical ostomies to divert feces away from a point of intestinal blockage appear in the European literature in the eighteenth century [30]. Causes of intestinal obstruction included hernia and colorectal cancer in adults and congenital anorectal malformation in infants. The surgeon's impulse to intervene, however, would have been tempered by uncertainty with respect to outcome. Patients presenting with

obstruction would have been dehydrated and malnourished. Coexisting medical illness would have been untreated. Operation would have been undertaken without the benefit of the anesthesia, mechanical ventilation, intravenous fluid resuscitation, blood transfusion, radiology, antibiotics, parenteral nutritional supplementation, or ostomy care-adjuncts that now are taken for granted (Table 1.1).

Table 1.1 Timeline of advances in intestinal stoma surgery and related areas

Surgical advances		Nonsurgical advances
	1700	
1710: Littre introduces the concept of ventral colostomy		
1757: Heister recommends suturing the wounded intestine to the abdominal wall		
1776: Pillore treats obstructing rectal cancer by cecostomy		
1783: Dubois performs the operation of Littre on an infant with imperforate anus		
1793: Duret reports iliac colostomy to treat an infant with imperforate anus.		
1797: Fine treats obstructing rectal cancer by transverse colostomy		
	1800	
1800 Callisen describes lumbar colostomy to treat imperforate anus		
1839 Amussat performs lumbar colostomy to treat obstructing rectal carcinoma		
		1842: Long performs surgery with ether inhalation anesthesia [2]
		1847-Simpson describes chloroform inhalation anesthesia [3]
		1880 Macewen introduces endotracheal intubation [4]
1876: Verneuil describes gastrostomy to treat esophageal stricture		
1879: Schede adds proximal diverting colostomy after transsacral rectal resection		
1884: Madelung recommends complete division of the colon during colostomy creation to achieve complete diversion		
1885: Knie emphasizes the importance of the spur to achieve diversion in colostomy creation		
1885: Davies-Colley suggests colon exteriorization followed by delayed resection to decrease the risk of suppuration after colotomy		
1887: Reclus performs colonic exteriorization with delayed opening of the colon to treat rectal cancer		
1888: Madyl describes loop colostomy		
1892: Smith recommends enterostomy to treat peritonitis		
1894: Bloch described staged extraperitoneal resection of the left colon for cancer		
1895: Keetley suggests appendicostomy as a treatment for ulcerative colitis		1895: Röntgen reports X-rays [5, 6]
1895: Paul performs exteriorization/resection for cancer with tube colostomy		
1893: Henrotin relieves distension caused by appendicitis by cecostomy		
		1899: Bier describes spinal anesthesia with cocaine [7]

Table 1.1 (continued)

Surgical advances	Nonsurgical advances
	1900
1902: Weir: Appendicostomy as a treatment for ulcerative colitis	1901: Landsteiner reports on blood groups [8]
1903: Mikulicz – Three step treatment of colon cancer: exteriorization, resection, delayed reconstitution of bowel continuity	
1908: Mayo – left iliac colostomy following abdominoperineal resection for cancer	1909: Meltzer and Auer – Continuous respiration without respiratory movements [9]
1913: Brown – Ileostomy and cecostomy for colitis	
1921: Hartmann – Sigmoid resection with colostomy and rectal stump	1923: Fischer – Barium enema [10]
	1929: Fleming – Penicillin [11]
1931: Rankin – Ileostomy and total colectomy for polyposis coli and ulcerative colitis	
1935: Koenig–Rutzen ostomy appliance	
1941: Dragstedt – Skin grafted ileostomy	
	1942: Griffith and Johnson – Curare [12]
1946: Butler-Primary colostomy maturation	1940s: World War II – Blood banking
	1950: Thorn – ACTH treatment for ulcerative colitis [13]
1950: Bricker – Bladder substitution using segments of intestine	
1950: Mt Sinai Hospital – First organized support group for ostomates	
1951: Brooke – Primary maturation of the ileostomy	
1951: Waren and McKittrick – Ileostomy dysfunction	
1952: Turnbull – mucosal grafted ileostomy	
1954: Lemmer and Mehnert – Maintenance of alignment of all layers of the abdominal wall during colostomy creation	1954: Trulove and Witts – Cortisone in ulcerative colitis [14]
1950s: Elise Sorensen – Plastic disposable ostomy appliances	
1957: Bishop and Koop – Roux Y Ileostomy to treat meconium ileus	
1958: Sames and Golligher independently describe retroperitoneal colostomy	
1961: First School of Enterostomal Therapy	
	1966: Dudrick, Wilmore, Vars, and Rhoads – Total intravenous feeding and growth in puppies [15]
1969: Kock introduces the continent ileostomy	
1972: Seruga describes Hepaticojejunostomy with jejunostomy for biliary access	
	References: [16, 17]

In his text, *The Anatomy of the Human Body*, published in 1750, Cheselden [31] described the case of Margaret White of Newington in Surry who acquired a colostomy at the site of a ruptured umbilical hernia:

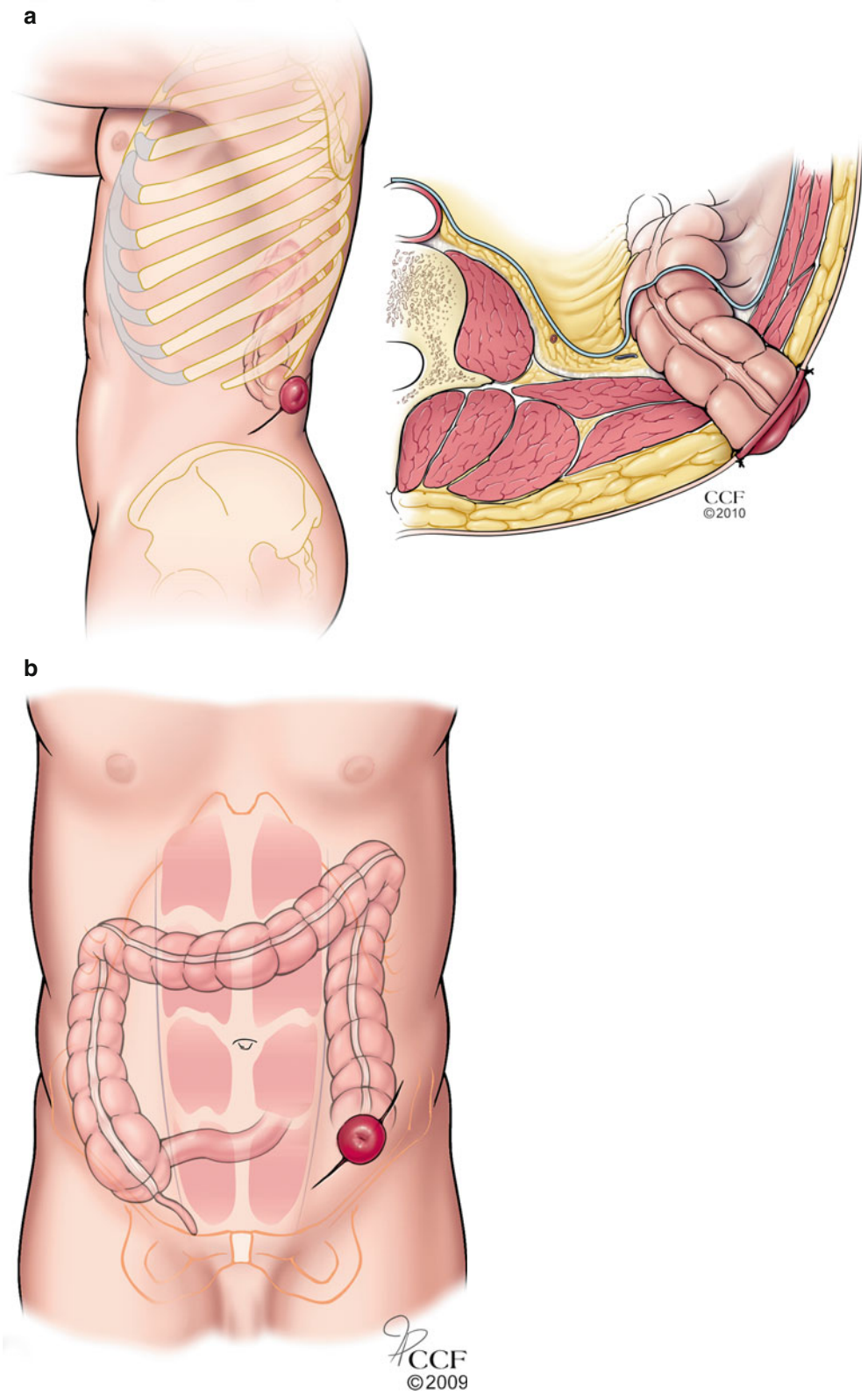
In the fiftieth year of her age, she had a rupture at her navel, which continued till her seventy third year, when after a fit of cholick, it mortified, and she being presently after taken with a vomiting, it burst. I went to her and found her in this condition, with about six and twenty inches and a half of the gut hanging out mortified. I took away what was mortified, and left the end

of the sound gut hanging out at the navel, to which it afterwards adhered; she recovered, and lived many years after, voiding the excrements through the intestine at the navel...

In 1839, Amussat [32] published a comprehensive treatise on the subject of the *anus artificiel*. He reviewed two major approaches that had emerged to achieve decompression of the obstructed large intestine: ventral and lumbar colostomy (Fig. 1.1a, b).

Fecal diversion by ventral colostomy had been proposed in 1710 by Littre [33].

Fig. 1.1 Lumbar and ventral colostomy: **(a)** lumbar colostomy was made using a retroperitoneal approach; **(b)** ventral colostomy originally was created by an iliac or inguinal incision (Illustration © CCF)



Diverses Observations Anatomiques

“Dans le cadavre d’un Enfant mort à 6. jours, M. Littre a vû le Rectum divisé en deux parties, qui ne tenoient l’une à l’autre que par quelques petits filets, longs environ d’un pouce.

M. Littre qui a voulu rendre son observation utile, a imaginé & proposé une opération chirurgique fort délicate pour les cas où l’on auroit reconnu une semblable conformation. Il faudroit faire une incision au Ventre, & recoudre ensemble les deux parties d’Intestin après les avoir rouvertes, ou du moins faire venir la partie superieure de l’Intestin à la playe du Ventre, que l’on ne refermeroit jamais, & qui feroit la fonction d’anus.”

In 1776, Pillore of Rouen was the first to apply the ideas of Littre [35, 36]. His surgery, however, was not sufficiently brought to light in the contemporary literature of the time. In 1839, Pillore’s achievement was documented by Amussat [37]. The patient, Monsieur Morel, presented with a totally

Opération d’anus artificiel, par la méthode de LITTRE [38]

“Eh, bien! leur répondit-il, il faut bien avoir recours à l’opération, puisqu’elle seule peut me sauver, vous en convenez, et qu’il est de fait que ma maladie est mortelle.”

Pillore continues his recollection of the procedure as follows:

Encouragé par des raisons aussi fortes, je fis l’opération en présence de messieurs mes confrères, et de six élèves pensionnaires que j’avais alors. J’avais choisi le coecum comme celui des intestins qui était le plus propre à remplir mes vues tant par sa situation que parce qu’il nous fournissait un réservoir...

Je commençai par une incision transversale des tégumens un peu au-dessus du pli de l’aîne; je la continuai obliquement de bas en haut; à la faveur du tissu cellulaire en sous-œuvre, j’arrivai à l’aponévrose du muscle grand oblique du bas-ventre; je l’incisai un peu au-dessus du ligament de Fallope dans la même proportion pour avoir au moins un bon pouce de canal depuis le réservoir jusqu’à l’ouverture des tégumens; je fis aux muscles et au péritoine une ouverture transversale à peu près de la même étendue; le fonds de cœcum, facile à reconnaître par son appendice, se présenta, je n’eus pas la peine de le chercher; je l’amenai sans effort le plus en avant possible; là, soutenu par un aide et par moi, je l’ouvris transversalement et l’assujettis aux deux lèvres de la plaie par le moyen d’un point de suture que je fis à l’une et à l’autre avec deux aiguilles enfilées du même fil; je les passai de dedans en dehors et je coupai le fil par le milieu pour obtenir deux anses que je nouai tant supérieurement qu’inférieurement sur deux compresses pour empêcher le froncement des lèvres. Les matières sortirent abondamment...

Pillore successfully decompressed the obstructed large intestine by cecostomy created through a right lower quadrant incision. M. Morel survived 28 days. At autopsy, Pillore found a totally obstructed scirrhus tumor at the junction between the end of the colon and the beginning of the rectum.

“Antoine Dubois a fait, en 1783 l’essai du procédé de Littre, sur un enfant né depuis trois jours sans apparence d’anus. Cet enfant est mort dix jours après l’opération. A l’ouverture du petit cadavre, on trouva les bords de l’intestin consolidés à la circonférence de la plaie de l’abdomen.”

Diverse Anatomic Observations

“In the cadaver of an infant who died at the age of 6 days, M. Littre saw that the rectum was divided into two parts which did not touch each other except by several strands about an inch long.

M. Littre, who wished to make his observation useful, imagined and proposed a very delicate surgical operation in case a similar situation should present itself again. It would be necessary to make a ventral incision and sew together the two parts of the intestine after they have been reopened or at least bring the superior part of the intestine to the ventral abdomen, which would never be closed and which would function as an anus.” [34].

obstructing scirrhus tumor of the rectum. Among the methods used to try to open bowel passage was the ingestion of mercury. None of the ingested metal was evacuated even after 1 month. Pillore recommended surgery to create an artificial anus to which M. Morel replied:

Operation to Create an Artificial Anus, by the method of LITTRE [34]

“Well then,” he answered, “the operation will have to be performed, since it is the only thing that can save me, you’ll agree, and the fact is that my illness is fatal.”

Encouraged by such strong reasons, I performed the operation in the presence of my colleagues and six resident students whom I had at that time. I had chosen the coecum as the intestine that was the most likely to serve my ideas, both because of its location and because it provided us with a reservoir...

I began with a transverse incision of the teguments slightly above the fold of the groin; continuing it obliquely from bottom to top, with the help of the cellular tissue underpinning, I reached the aponeurosis of the large oblique muscle of the lower part of the abdomen; I made an incision slightly above the fallopian ligament in the same proportion, in order to have at least a good inch of channel from the reservoir to the opening of the teguments; I made a transverse opening in the muscles and the peritoneum of approximately the same extent; the coecum bottom, easily recognizable by its appendix, appeared, I did not have to look for it; effortlessly, I drew it as far forward as possible; there, with an assistant and I supporting it, I opened it transversely and fastened it to the two lips of the wound by means of a suture that I made in the lips with two needles threaded with the same thread; I passed them from inside to outside and cut the thread in the middle in order to obtain two loops that I knotted at top and bottom on two compresses to prevent the lips from puckering. An abundance of material came out...

The mercury that the patient had been given was found in a gangrenous segment of jejunum.

Amussat quotes Allan who recorded that Dubois performed Littre’s operation in a case of anal atresia in 1783 [39].

In 1783, Antoine Dubois, performed Littre’s procedure on a child born 3 days earlier without any appearance of an anus. This child died 10 days after the operation. On opening the small corpse, the edges of the intestines were found to be circumferentially healed to the abdominal wound [34].

In 1793, Duret [40] of Brest successfully performed an iliac colostomy on an infant with imperforate anus.

Observation sur un enfant né sans anus, et auquel il a été fait une ouverture pour y suppléer; par le C. Duret, professeur d'anatomie et de chirurgie, à l'hôpital militaire de la marine à Brest

“J’ouvris le ventre du petit malade au-dessus de la région iliaque, dans l’endroit où l’S du colon formoit une tumeur, à la vérité peu apparente, et où le méconium sembloit imprimer une couleur plus foncée à la peau; je donnai à cette ouverture à-peu-près un pouce et demi d’étendue; elle servit à introduire mon doigt index dans l’abdomen, avec lequel j’attirai au dehors l’S du colon; et dans la crainte qu’il ne rentrât par la suite dans le ventre, je passai dans le mezo-colon deux fils cirés; ensuite j’incisai l’intestin en long; l’air et le méconium sortirent en abondance par cette ouverture...”

Dinnick records that this child survived and lived to the age of 45 years [41]. In praise, Verneuil and Reclus wrote that Duret developed his technique by experimentation on cadavers, practiced his technique many times with success, and passed his knowledge on to pupils [42]. A year later, in

Observations et réflexions sur une imperforation de l’anus. C. L. Dumas, professeur de l’École de Santé de Montpellier

En examinant l’enfant, je trouvai l’anus absolument clos... Je fis appeler Estor, chirurgien, pour qu’il m’aidât de ses conseils et de son ministère...

Je proposai à Estor de pratiquer un anus artificiel vers l’extrémité gauche du colon. Il approuva mon idée, mais il n’eut pas le courage de l’exécuter, parce que les parents sembloient y répugner: il craignait de compromettre sa réputation par les suites d’une opération aussi importante, dont le succès sembloit fort incertain. L’enfant mourut le troisième jour de sa naissance. Nous procédâmes à l’ouverture du cadavre. Après avoir fait une incision dans la région iliaque gauche, nous mîmes à découvert la partie inférieure du colon qui se présenta la première, et qui, par conséquent, étoit contigue à la lame interne du péritoine. Cet intestin étoit boursofflé par l’air, et plein de matières liquides et gazeuses. Il occupoit un espace considérable, et faisoit saillie vers les muscles abdominaux. Il eût été dès-lors bien facile d’établir un anus artificiel, qui auroit au moins prolongé la vie du sujet, en même tems qu’il eût fourni à la science une observation intéressante et rare

In 1797, Fine, chief surgeon of the hospital of Geneva, published two papers on the subject of artificial anus in the *Annals of the Society of Medicine of Montpellier* [45]. Noting

Mémoire et observation sur l’entérotomie, par M. Pierre Fine, chirurgien en chef de l’hôpital de Genève, et correspondant de la Société de médecine pratique de Montpellier.

Ad extremos morbos, extrema remedia exquisitè optima.

Hipp. APH. 6, sect. I

Opération d’anus artificiel, par la méthode de Littre, sur une femme âgée de 63 ans, qui a vécu trois mois et demi.

Depuis que j’exerce l’art de guérir, j’ai eu à soigner plusieurs cas de tympanite, soit essentielle, soit le plus souvent symptomatique; frappé depuis longtemps de l’insuffisance des moyens que la médecine prescrit contre cette terrible maladie, affligé de la perte que je venais de faire tout récemment d’un malade atteint de cet état morbide pour lequel j’avis inutilement conseillé l’entérotomie, je me promis bien qu’à l’avenir j’insisterais fortement sur l’emploi de ce moyen, lorsque le cas dont je vais présenter le journal s’offrit peu de temps après [46].

Observations on an infant born without an anus, for which an opening was made to provide one; by C. Duret, Professor of Anatomie and Surgery, the Military Hospital, Brest

“I opened the belly of the little sick child over the iliac region, in the place where the sigmoid colon formed a mass, visible from the skin, and where the meconium appeared to impart a dark color to the skin; I made an opening at that site that was extended a one and a half inches; it served to introduce my index finger into the abdomen, with which I pulled out the sigmoid colon; and out of fear that the colon would retreat back into the belly, I passed two waxed threads though the mesocolon; then I incised the intestine longitudinally; gas and meconium ran out in abundance through this opening...”

1794, Desault reported another case of artificial anus by the method of Littre on an infant with imperforate anus [43]. The child lived for 4 days. In 1797, Dumas [44] described an infant with imperforate anus in whom surgery was suggested but not done.

Observations and reflexions on a case of imperforate anus. C.L. Dumas, professor, School of Health, of Montpellier

On examination, I found that the anus was completely closed... I asked Estor, a surgeon, to aid me with his counsel and ministries...

I proposed to Estor to place an artificial anus toward the left end of the colon. He approved of my idea, but he did not have the courage to carry it out, because the parents seemed to be reluctant to have it done: he was afraid of compromising his reputation with the consequences of such an important surgery, whose success seemed quite uncertain. The child died 3 days after his birth. We undertook the opening up of the corpse. After having made an incision in the left iliac region, we uncovered the lower part of the colon, which came first, and which, consequently, was next to the internal strip of the peritoneum. This intestine was swollen by air, and full of liquid and gaseous matters. It was occupying considerable space and bulging towards the abdominal muscles. It would have been, therefore, easy to insert an artificial anus, which would at least have prolonged the life of the patient, and at the same time would have provided an interesting and rare observation to science [34].

that Fine’s work had been “complètement ignores,” Amussat reproduced the papers in their entirety.

Memoir and observation on enterotomy, by M. Pierre Fine, surgeon in chief, Hospital of Geneva, and correspondent of the Society of practical medicine of Montpellier.

For extreme illness, extreme remedies.

Hipp. APH. 6, sect. I

Operation of artificial anus by the method of Littre on a woman aged 63 years who lived three and half months.

Since I began practicing the healing art, I have had to treat several cases of tympanites, sometimes idiopathic but more often symptomatic. I had long been struck by the inadequacy of the measures prescribed by medical science for this terrible illness, and was afflicted by my very recent loss of a patient suffering from this morbid condition, and for whom I had in vain advised enterotomy, I promised myself that in the future I would strongly insist on using this method, when the case on which I am going to report occurred a short time later [47].

Fine's patient suffered from an obstructed rectal cancer. Through an incision between the navel and the pubis, he created a decompressing ostomy. His patient lived three and a half months. Postmortem examination revealed that he had created a transverse colostomy [48].

A second method of colonic decompression using a retroperitoneal approach was introduced because of concern

that peritonitis might occur from intra-abdominal intestinal injury using a ventral incision. In 1800, Callisen [49], professor of surgery at Copenhagen, recommended lumbar access to the descending colon in order to create an artificial anus.

Henrici Callisen. Systema Chirurgiae Hodiernae in usum publicum et privatum adornatum pars posterior editio nova auctior et emendatio

“MLXXII: *Chirurgia imperforationis ani*

Quae proposita sub hoc rerum statu fuit incisio intestini coeci vel coli descendentes, sectione in regione lumbari sinistra ad marginem musculi quadrati lumborum facta, ut anus pareretur artificialis, remedium praebet omnino incertum, atque hac operatione vix vita miselli seruari poterit. Quamquam intestinum in hoc loco facilius attingatur, quam supra regionem inguinalem.”

Callisen performed the operation on a cadaver [51]. The greatest advocate of the retroperitoneal approach to the colon was Amussat [52, 53]. Amussat developed his surgical technique studying the surgical and pathologic anatomy of

Henrich Callisen. A System of Contemporary Surgery Prepared for Public and Private Use. A new enlarged and corrected later edition

“1072: Surgery on an imperforation of the anus.

Under these circumstances an incision has been suggested in the cecum or the descending colon, with a section made in the left lumbar region near the edge of the quadratus lumborum muscle, so that an artificial anus may be made ready. This offers a very doubtful remedy, and it will only be possible with difficulty to save the life of the wretched sufferer by this operation. And yet the intestine may be more easily reached in this place than above the region of the groin.” [50]

the colon in the lumbar regions using cadavers [54] and, in 1839, reported the particulars of his first case to treat obstructing carcinoma of the rectum in a 48-year-old woman, Madame D., born in Nantes.

Mémoire sur la possibilité d'établir un anus artificiel dans la région lombaire sans pénétrer dans le péritoine.

J. Z. Amussat

Introduction.

“L'idée d'ouvrir le colon lombaire gauche sans intéresser le péritoine est assez ancienne; mais elle avait paru inexécutable jusqu'à présent, comme je vais le prouver par quelques citations.” [55]

CHAPITRE IV.

FAITS PARTICULIERS.

1re OBSERVATION.

Obstruction complète de la fin de l'S iliaque par des tumeurs, chez une femme âgée de quarante-huit ans; constipation datant de vingt-six jours; tympanite stercorale des plus violentes. Anus artificiel établi avec succès, en ouvrant le colon lombaire gauche *sans pénétrer dans le péritoine* [56].

Modestly, he referred to his approach as the “Callisen modification.” [57] In the follow-up, 4 months after surgery, Amussat records that Madame D's health was as satisfactory as possible [58]. In a passage preceding this case description,

j'étais bien préparé à ne plus rester spectateur passif de la mort par obstruction du rectum [56].

In 1841, Erichsen [59] introduced Amussat's work to the English medical public. Subsequently, in 1844, Amussat [54] published a memoir on “enterotomia,” successfully performed without opening the peritoneum, in the *Medical Times*. Concerning the application of this operation to cases of obstruction, Amussat concluded:

Finally, this case confirms all that I have asserted in the different memoirs, already published on the subject, and it emboldens me, and ought likewise to embolden other practitioners, to perform this operation, instead of, as is often the case, allowing their patients to die unrelieved.

Treatise on the possibility of establishing an artificial anus in the lumbar region without penetrating the peritoneum.

J.Z. Amussat

Introduction.

“The idea of opening the left colon from a lumbar approach without concerning the peritoneum is rather old, but it has not been carried out until the present as I shall prove by several citations.”

CHAPTER IV.

PARTICULAR FACTS

1st OBSERVATION.

Complete obstruction of the end of the sigmoid colon by tumor, in a 48-year-old woman; constipated for 26 days; a most violent distention of the bowels. Artificial anus created successfully by opening the lumbar aspect of the left colon *without opening the peritoneum* [34].

Amussat explained his motivation for undertaking this work. Affected by the painful death caused by stercoral obstruction, he acted.

I was well prepared to no longer remain a passive spectator of death by obstruction of the rectum.

Decompression proximal to the site of obstruction was not always achieved by lumbar colostomy. In 1850, Avery [60] at Charing-cross Hospital described a case of intestinal obstruction in which an operation for artificial anus in the left lumbar region was performed. Unfortunately, the patient succumbed; and autopsy revealed “twisting of the caecum and ascending colon, producing obstruction of the bowels.” In 1873, Mason [61] in New York described 6 cases of lumbar colostomy and presented a summary of 80 cases.

In 1821, Pring reported [62] the case of Mrs. White who had an obstruction in the lower bowels detected by a rectal-bougie. The formation of an artificial anus was proposed. Pring recorded his course of action as follows:

The patient was desirous of living upon any terms, and agreed to submit to the operation. Accordingly, having placed her on a table, I made an incision on the left side of the abdomen, beginning about two inches above, and one inch on the inside, of the anterior superior spinous process of the ilium. This incision was extended obliquely downwards and inwards to within three-quarters of an inch of the edge of Poupart's ligament: the fascia covering the abdominal muscles was thus exposed to the extent of between three and four inches. An opening was then made through the external and internal oblique, and the transversalis, muscles; which opening was enlarged, with a bistoury conducted by my finger, to the extent of the external incision. The peritoneum being now laid bare, a small opening was made in this membrane... The colon was thus freely exposed a little above its sigmoid flexure, at which place I made an incision into it... The contents of the bowels were immediately expelled with great force to a considerable distance: as the feces escaped, the gut collapsed, and began to subside from its place: a ligature was therefore passed through it at the lower part of the opening, the apposition of which to the external wound was then preserved until the bowels were copiously evacuated.

At follow-up between 5 and 6 months, Pring reported that his patient's general health was apparently good and that "the object of the operation has been completely attained." An account of "an analogous Operation" by Freer in the same article [62] described a case of artificial anus made through "the parietes of the abdomen, in the left iliac region, so as to expose the colon near its sigmoid flexure" on an infant born without an anus. Freer recalled:

I accordingly performed the operation: a considerable quantity of meconium was evacuated; and during the three weeks that the child lived, the feces passed freely at the wound. The child

sucked and slept well, and seemed free from suffering, but died apparently from marasmus.

In this case, though ultimately unsuccessful, the operation had undoubtedly prolonged the life of the child, and seemed to justify us in recommending it in the present instance.

In 1851, Luke [63] in London reported a case of colonic obstruction situated about the "sigmoid flexure." The site of blockage was determined by the fact that insertion of an esophagus tube into the rectum met with obstruction about 12 in. distant from the anus and water injected into the tube also immediately returned. In pondering his surgical options, Luke wrote:

Assuming the correctness of our conclusion, that operation which passes under the name of Amussat, appeared to recommend itself by the circumstance of its avoiding the necessity of peritoneal section... Yet, as I thought it not prudent to assume that our conclusion respecting the seat of obstruction was certainly correct, I determined to adopt that operation which would at least give me some opportunity of extending my search, provided I did not find the obstruction at the point where it was supposed to be, thinking that the increased probability thus afforded, of finding the obstruction, would be more than an adequate compensation for the little increased danger from peritoneal section. I therefore opened the abdominal parietes near the groin.

The colon proximal to a stricture was exteriorized and opened immediately. Luke recorded that: "Through the aperture thus made, half a chamber-utensil full of fluid faeculent matter made its escape, after which the patient expressed himself much relieved." This person recovered and was able to return to work.

In 1881, Richter reported the presentation of Schinzinger [64] in Salzburg who described two cases of inoperable sigmoid colon cancer treated by colostomy in which the colon is divided.

Redner theilt vor Allem 2 Fälle von inoperablem Krebs der Flex. sigm. mit, in welchen er zur Erleichterung der Kranken einen künstlichen After oberhalb der Leistenbeuge anlegte. Er empfiehlt, in solchen Fällen den Darm ganz zu durchtrennen, das obere Ende desselben in die Wunde einzunähen, das untere aber ganz zu schliessen und zu versenken.

The speaker reports in particular on 2 cases of inoperable cancer of the sigmoid flexure, in which he created an artificial anus above the groin to ease the discomfort of the patients. He recommends in such cases that the intestine should be cut through completely, the upper end sutured into the wound, and the lower end closed off completely and buried [34].

In a larger study, published in 1884, Madelung [65] in Rostock described totally diverting colostomy to treat rectal carcinoma in which the bowel is completely divided, the

proximal end is secured in the abdominal wall, and the distal end is closed and returned to the abdominal cavity.

Madelung (Rostock). Über eine Modifikation der Colotomie wegen Carcinoma recti

"Es soll in das Colon nicht nur ein Fenster eingeschnitten, sondern der Darm vollständig durchschnitten werden. Sein centrales Ende wird zur Bildung des künstlichen Afters in die Bauchwandungen eingepflanzt, das periphere wird nach Verschluss seines Lumen in die Bauchhöhle versenkt. Diese Operation ist schwieriger als die gewöhnliche Colotomie. Vor Allem muss natürlich genau bestimmt werden, welches der zuführende, welches der abführende Darmtheil ist."

Madelung (Rostock). Concerning a modification for colostomy for rectal carcinoma

"Not only should a window be cut into the intestine, but also the colon should be completely divided. The proximal end used to create the artificial anus is implanted into the abdominal wall while the lumen of the distal end is closed and buried in the abdominal cavity. This operation is more difficult than the usual colostomy. Above all, of course, it is necessary to determine very precisely which is the incoming, which the outgoing part of the intestine." [34]

In 1885, Knie [66], in Moscow, looked for an alternative technique to create a two-sided colostomy that would be totally diverting. He proposed that the spur connecting the

limbs of a two-sided colostomy should effectively make the distal end of the colostomy impassable (*undurchgängig*). He tested his ideas through animal experiments.

Zur Technik der Kolotomie

Von Dr. A Knie

(Aus dem Laboratorium für experimentelle Pathologie in Moskau)

“Ausgehend davon, dass bei spontan entstandenem Anus praeternaturalis der Darminhalt durch den Sporn nach außen geleitet wird, und in vielen Fällen von Spornbildung es gar nicht mehr zur Entleerung per Rectum kommt, unternahm ich eine Versuchsreihe, die die Bedingungen feststellen sollte, unter welchen es möglich wäre, bei noch nicht eröffnetem Darmrohr einen Sporn zu bilden.”

In 1887, Allingham [67] reported the results of six inguinal colostomies. He argued for inguinal colostomy over lumbar colostomy for artificial anus applied to obstruction in the rectum or sigmoid flexure.

Now that surgery, through perfect cleanliness, has made such gigantic strides, and the peritoneum is no longer held in awe as in former days, the opening of that serous cavity, if due care be taken, does not to any great extent increase the dangers of the operation, and is certainly not more harmful to the patient than the disturbance of cellular tissue and parts around, so frequently incurred when there is difficulty in finding the bowel in lumbar colotomy.

Anus artificiel iliaque

Par M. le Dr. Paul Reclus

J’ai pratiqué, il y a sept mois, un anus artificiel iliaque pour obvier aux accidents que provoquait, chez une femme de 59 ans, un cancer volumineux de la partie moyenne du rectum.

Et d’abord, un mot sur le manuel opératoire, car le mode d’intervention auquel j’ai eu recours, n’est pas usité en France, et c’est peut-être la première opération de ce genre qui ait été faite chez nous.

...nous retirons une anse bosselée, grisâtre, à bandes longitudinales visibles et hérissée d’appendices épiploïques; c’est bien la partie que nous cherchons, et nous nous apprêtons à la faire au dehors.

Au lieu de pratiquer des points de suture, temps long et délicat, nous avons maintenu l’anse en passant au-dessous d’elle et au travers du mésentère une mèche aseptique, une lanière de tarlatane iodoformée saisie par une pince à forcipressure... Puis, avec du collodion, les deux extrémités libres de la lanière ont été collées sur la peau; l’anse se trouvait ainsi solidement fixée et ne pouvait plus rentrer dans le ventre.

Le sixième jour seulement, l’appareil a été levé et nous avons incisé au thermocautère la convexité de l’anus; le huitième jour, comptant sur des adhérences péritonéales suffisantes, nous avons enlevé la lanière de tarlatane iodoformée; l’intestin n’a pas bougé; le douzième jour, la malade est allée abondamment à la garde-robe par son anus artificiel...

In 1888, Maydl [69, 70] in Vienna reported on diversion of the fecal stream in cases of malignancy. In his operation, a mobile loop of large or small intestine is exteriorized and

On the Technique of the Colotomy

By Dr. A Knie

(Laboratory for Experimental Pathology, Moscow)

“Proceeding on the basis that, in cases of spontaneously formed anus praeternaturalis, the intestinal content is conducted to the outside through the spur and that, in many cases where a spur is formed, the content is no longer emptied via the rectum at all, I conducted a series of experiments to determine the conditions under which it would be possible to form a spur before the intestinal tube is opened.” [34]

In Allingham’s technique, a loop of gut was exteriorized and stitched to the abdominal wall with thread passed through the mesentery close to the intestine and then through the abdominal wall on both sides. In the same year, Reclus [68] described a patient with a large cancer of the rectum treated by iliac artificial anus. He used a staged technique involving support of the exteriorized sigmoid colon by a wick of iodoform gauze and delayed intestinal decompression.

Iliac artificial anus

By Dr. Paul Reclus

Seven months ago, I created an iliac artificial anus in a 59-year-old woman to prevent problems caused by a voluminous cancer in the middle part of the rectum.

First of all, a word about the operating manual, because the surgical procedure I used is not in common use in France, and may be the first operation of this kind done in our country.

...we pulled out a lumpy, grayish loop with visible longitudinal bands and covered with appendices epiploica. It was in fact the part we were looking for, and we prepared to bring it out.

Rather than making sutures, a long and delicate procedure, we held the loop by passing aseptic packing, a strip of iodoform gauze, under it and through the mesentery grasped by forcipressure clamps...

The two free ends of the strip were then adhered to the skin with collodion. Thus, the loop was solidly attached, so that it could not slip back into the abdomen.

Only on the sixth day was the device removed, and we made an incision in the convexity of the anus using thermocautery. On the eighth day, counting on the peritoneum being sufficiently healed, we removed the iodoform gauze strip. The intestine did not move. On the 12th day, the patient had a copious bowel movement through her artificial anus [34].

then suspended outside the abdominal wall by a transmesenteric rubber (vulcanite) rod. In emergencies, he used a goose feather.

Zur Technik der Kolotomie

Von Dr. Karl Maydl

“Und nun will ich das Verfahren kurz schildern, wie ich es in der letzten Zeit zu üben pflege.

On the Technique of Colotomy

By Dr. Karl Maydl

“And now I want to describe briefly the procedure which I have been using recently.

Nach Eröffnung der Bauchhöhle ziehe ich einen beweglichen Darmabschnitt (Col. transv., Flexura rom. oder Ileum) so weit vor, dass der Mesenterialansatz der vorgezogenen Darmschlinge vor die Bauchwunde zu liegen kommt; durch einen Schlitz des Mesenteriums knapp am Darm stecke ich einen mit Jodoformgaze umwickelten Hartkautschukbolzen (im Nothfall Gänsefederkiel) durch...

Soll der Anus praeternaturalis persistiren, so eröffnet man bei einseitiger Operation gleich, bei zweizeitiger in 4–6 Tagen den Darm quer, auf ein Drittel seiner Peripherie...

Für gewöhnlich genügt die Eröffnung allein, die den Gasen einen Ausweg schafft; die flüssigen oder festen Darminhaltsmassen können später entleert werden; die Möglichkeit der Gasentweichung bietet den Pat. eine genügende Linderung ihres bisherigen Zustandes. Die Eröffnung des Darmes mache ich, um alle Blutung zu vermeiden, mit dem Thermokauter. Hat der Kranke alle Operationsfolgen gut überstanden, so wird nach 14 Tagen bis 3 Wochen die übrige Darmperipherie auf dem Kautschukbolzen getrennt, wobei dieser sehr gut als Unterlage und Marke verwendet wird. Zum Überfluss kann man den Rand der Darmlumina mit einigen Nähten an die Haut befestigen, da sie stets eine Tendenz zur Retraktion haben;...

In 1889, Kelsey [71] in New York described an “improvement in the technique of inguinal colostomy” that involved supporting the exteriorized colon by means of a hare-lip pin passed through the abdominal wall and through the intestinal mesentery.

The incision is that of Crips—across a line from the anterior-superior spinous process to the umbilicus. After getting the sigmoid flexure outside the body, a hair-lip pin is passed under it in the following manner: It is entered through the skin on the side of the wound toward the median line, and at the junction of the lower with the middle third of the incision. It perforates first the skin, next the parietal peritoneum, next the mesentery of the gut close to the bowel, and at the junction of the lower and middle thirds of the exposed loop, next the parietal peritoneum on the other side of the incision, and finally the skin. By this means the gut is so firmly held in position that it cannot be dislodged by any vomiting, and a perfectly satisfactory spur is formed, which will prevent any passing of fecal matter beyond the opening.

In 1892, Reeves [72] described sigmoid loop colostomy suspended outside of the abdominal wall by means of a transmesenteric rod. At the end of a week, the bowel was opened

After opening the abdominal cavity, I pull a movable section of the intestine (transverse colon, flexura rom. or ileum) so far forward that the mesenterial attachment of the pulled-out loop of intestine comes to rest in front of the abdominal wound; through a slit cut in the mesentery right at the intestine, I insert a hard rubber pin wrapped with iodoform gauze (in an emergency, a goosefeather quill)...

If the artificial anus is intended to last, open the intestine transversely around one third of its periphery – this is done right away if this is a one-time operation, or after 4–6 days, if the operation is performed in two phases...

The process of opening is usually enough in itself to create an escape route for the gases; the liquid or solid intestinal contents can be emptied out later; the ability of the gases to escape gives the patient sufficient relief from his current state. To avoid any bleeding, I open the intestine with a thermocauterizer. If the patient has survived all of the consequences of the operation in good shape, then after 14 days to 3 weeks, the rest of the periphery of the intestine is cut through on the rubber pin – the pin serves very effectively as a support surface and as a marker. It is not strictly necessary, but one can fasten the edge of the intestinal lumen to the skin with a few sutures, because it always has a tendency to retract...” [34]

longitudinally and the gut edges stitched to the skin (Fig. 1.2a). In 1900, Hartmann [73] illustrated the use of iodoform gauze to suspend the loop iliac colostomy (Fig. 1.2b).

Extraperitoneal Resection of Colon Cancer

In 1885, Davies-Colley [74] in London described three cases of colostomy with delayed opening of the intestine. He found that delayed opening is accompanied by less suppuration. By extension, he suggested exteriorization with delayed resection:

...in the case of a tumour of the colon, it might be better to draw out the loop of intestine containing the growth with the investing peritoneum and wait for a few days before excising the loop by the knife, the cautery, or some caustic agent.

In 1894, Bloch [75, 76] of Copenhagen described extraperitoneal resection of the left colon for cancer in a 24-year-old woman. The freely movable tumor was exteriorized and incised above the tumor. This was followed by extraperitoneal resection and delayed closure of the artificial anus.

Extraabdominal Resektion af hele Colon descendens og et Stykke af Colon transversum for Cancer.

Af Oscar Bloch

Den 6/5 94 foretoges Laparotomi; den stærkt angrebne Colon descendens med det tilgrænsende Stykke af Flexura coli lienalis blev trukket frem, saa at det laa udenfor Abdominalsaarets Hudrande, frit ovenpaa Bugvæggen; det blev holdt i dette Leje ved Hjælp af tre med Jodoformgaze omviklede Glasstænger, der bleve stukne gennem Mesocolon...

15de Dag efter Operationen reseceres det syge Tarmstykke i sundt Væv. Et Par Uger senere kom Patienten op, og lidt over to Maaneder efter Laparotomien med Fremlægningen var Saaret lægt; Anus praeternaturalis fungerede godt.

Som det vil ses af ovenstaaende Meddelelse er det muligt ved extraabdominal Fremlægning og senere Resektion at fjærne et meget stort Stykke Tarm, selv om dette ved Adhærencer er fast bundet til Bughulens bageste Væg; i det meddelte Tilfælde har Forløbet efter den store Operation været paafaldende roligt.

Extra-abdominal Resection of the whole descending colon and a piece of the transverse colon for cancer.

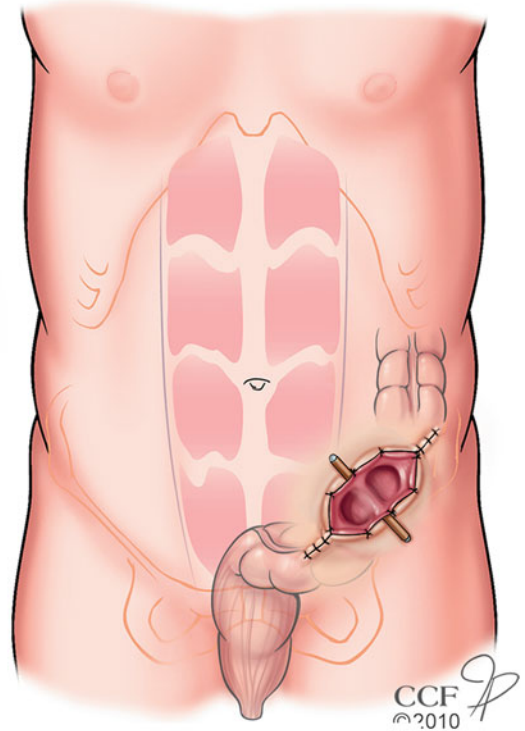
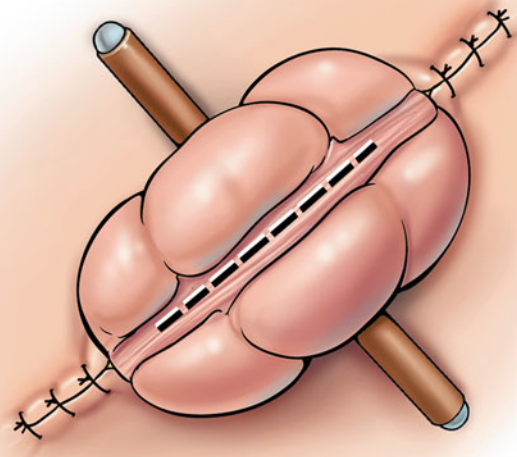
By Oscar Bloch

On 6/5 94, laparotomy was performed. The heavily attached descending colon with an adjacent piece of the splenic flexure was pulled forward such that it lay beyond the abdominal incision, exposed on top of the abdominal wall. It was kept in position with the help of three glass rods wrapped in iodoform gauze, which were inserted through the mesocolon...

On the 15th day after surgery the diseased piece of intestine is resected in healthy tissue. A couple of weeks later the patient is mobilized, and a little more than 2 months after the laparotomy, with the exposure the wound was healed. The anus praeternaturalis functioned well.

As it will be seen from the above message, it is possible to remove a rather large part of the intestine by extra-abdominal exposure and subsequent resection, even when this by adherence is firmly attached to the posterior abdominal wall. “In the case described, the course of events since the large operation has been strikingly uneventful.” [34]

a



b


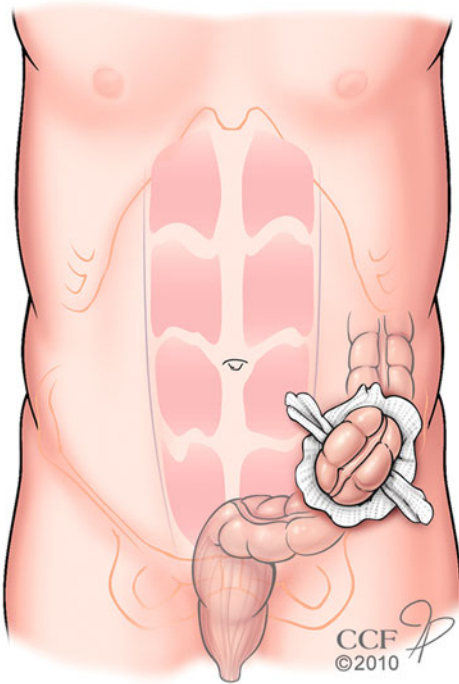


Fig. 1.2 Loop Colostomy: (a) Sigmoid loop colostomy (Reeves). The exteriorized sigmoid colon is secured above the skin by a transmesenteric rod; (b) Treatment of rectal cancer by proximal

diversion as illustrated by Hartmann. The bowel is exteriorized through a left iliac incision, supported using iodoform gauze and then opened several days later (Illustration © CCF)

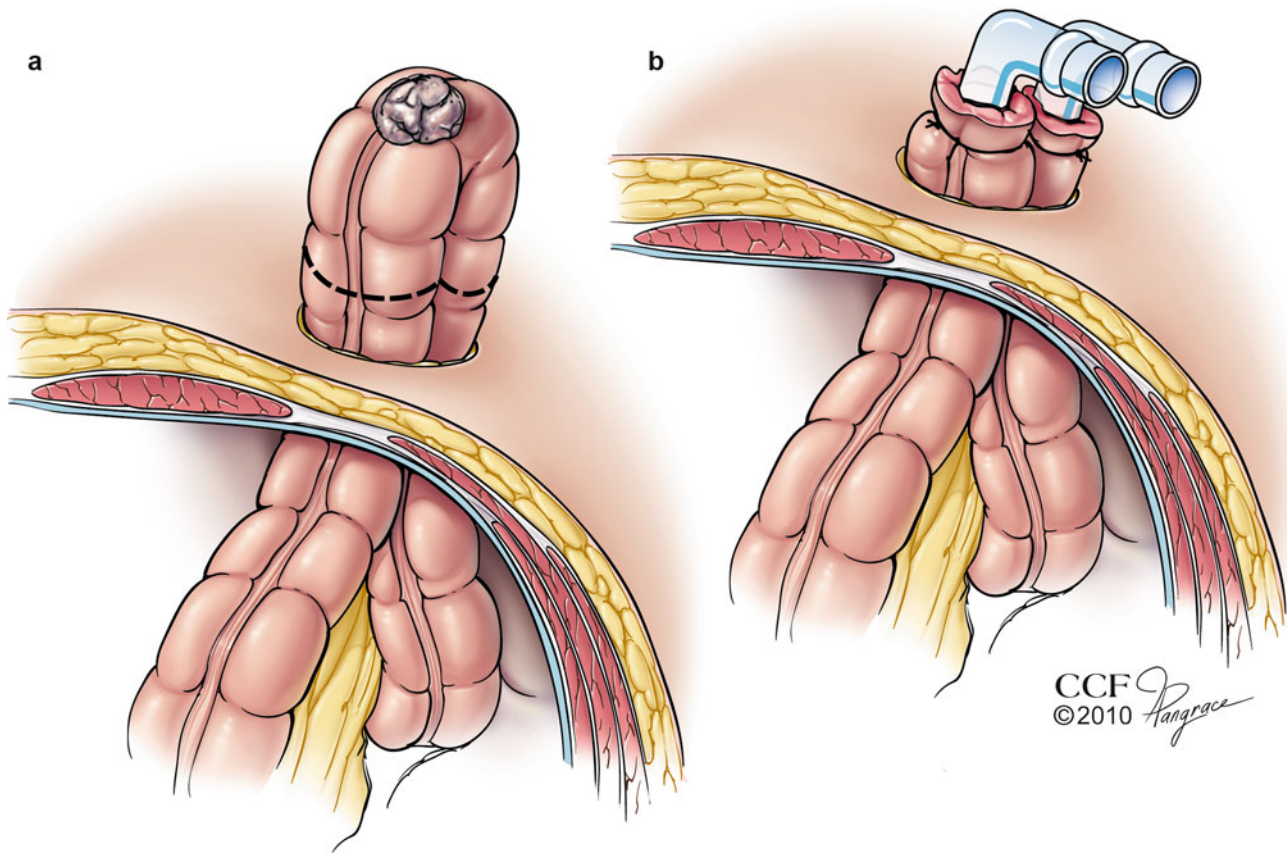


Fig. 1.3 Extrapertoneal resection of colon cancer. (a) The tumor bearing segment of colon is exteriorized. (b) Following resection of the tumor bearing segment, the remaining limbs of intestine are decompressed, in this case using Paul's glass tubes (Illustration © CCF)

In 1895, Paul [77] in Liverpool, wrote a treatise that began with a description of a patient with a malignant sigmoid stricture that was excised. A primary anastomosis unfortunately leaked, and the patient died. In retrospect, Paul wrote that had he been content with initial inguinal colostomy the patient “could scarcely have failed to survive.” In a subsequent case, he excised a sigmoid malignancy, but then made no attempt to restore bowel continuity. Instead, he sewed glass

intestinal tubes into the remaining ends of the intestine. Convalescence was rapid.

In 1903, Mikulicz, similarly dissatisfied with resection and primary anastomosis, described a three-step treatment of colon cancer: exteriorization, resection, followed by delayed restitution of bowel continuity (Fig. 1.3) [78].

Mikulicz discussed the relative advantages and disadvantages of extraperitoneal resection with colostomy as follows:

Chirurgische Erfahrungen über das Darmcarcinom Von J. von Mikulicz

Die Vortheile dieses Verfahrens sind ersichtlich. Die Hauptoperation ist kürzer als bei der einzeitigen Methode, die Infection des Peritoneums während der Operation wird absolut vermieden, man kann sie daher einem durch das Leiden heruntergekommenen Kranken viel eher zumuten.

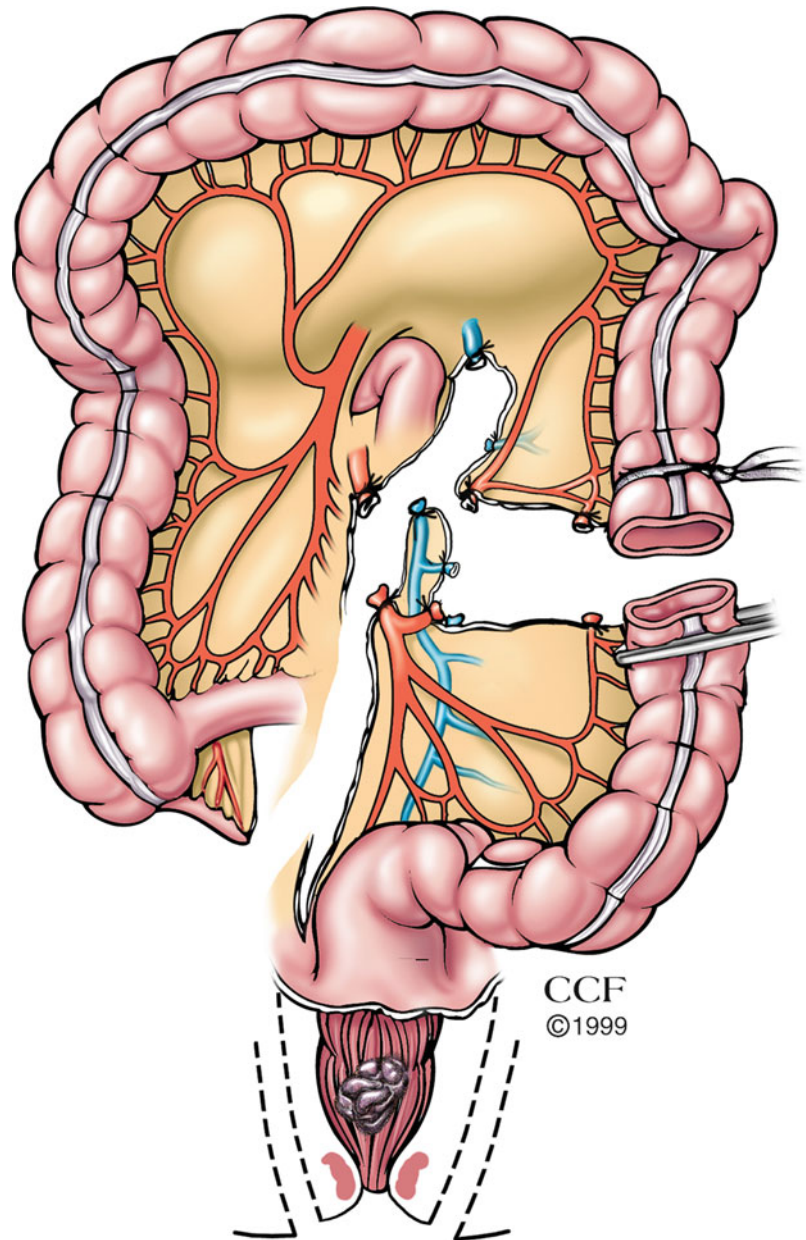
Die Methode ist also nicht nur ungefährlicher, sondern auch leistungsfähiger. Allerdings hat das Verfahren auch seine Schattenseiten. Die Behandlungsdauer ist eine viel längere und der Operirte muss eine Zeit lang die Unannehmlichkeiten eines widernatürlichen Afters über sich ergehen lassen. Aber das sind, denke ich, Nachtheile, die durch den Vortheil der grösseren Sicherheit und Leistungsfähigkeit reichlich aufgewogen werden.

Surgical Experiences with Intestinal Carcinoma by J. von Mikulicz

The advantages of this procedure are evident. The main operation is shorter than by the single stage method, the peritoneal infection during the operation is absolutely avoided, and one can thus attempt it much earlier on a patient debilitated by the disease.

The method is not only less dangerous but also more easily performed. Of course the procedure also has its drawbacks. The duration of treatment is longer and the patient operated on must bear with the unpleasantness of an artificial anus for a long time. But I think these disadvantages are greatly outweighed by the advantages of greater safety and increased ease of performance [79].

Fig. 1.4 Colostomy resulting from abdominoperineal resection of the rectum for cancer (Illustration © CCF)



In 1928, Sistrunk [80] in Rochester recommended proximal transverse colostomy as an initial step for Mikulicz resection of sigmoid cancers. Two and a half weeks later, a second operation was performed to remove the growth. This was followed by subsequent simultaneous closure of the two colostomies.

Rectal Cancer Resection with Proximal Diversion

In 1904, Mayo [81] described abdominoperineal resection of the rectum for carcinoma (Fig. 1.4) as follows:

The block removal of the rectum and glands where possible from below and in high location of the cancer, the combined

abdominal and perineal methods of removing rectum, glands, and all malignant tissue en masse, is the surgery for the cancer of this region. This method is merely the application of principles of the surgery of cancer, regardless of location, as exemplified by Halstead's operation for the removal of cancer of the breast.

The combined abdominal and perineal method is now advocated for high rectal carcinoma by the pioneers in rectal surgery, Kocher, Kraske, Gaudier, Quenu, Trendelenberg, Abbe, Weir, and numerous others.

In Mayo's technique, "colostomy, as usually performed, has been the lifting of a loop of sigmoid through an abdominal iliac incision."

In 1887, Schede [82] described rectal cancer excision according to the method of Kraske [83]. In one case, he added an abdominal colostomy, effectively diverting the feces away from the operative field.