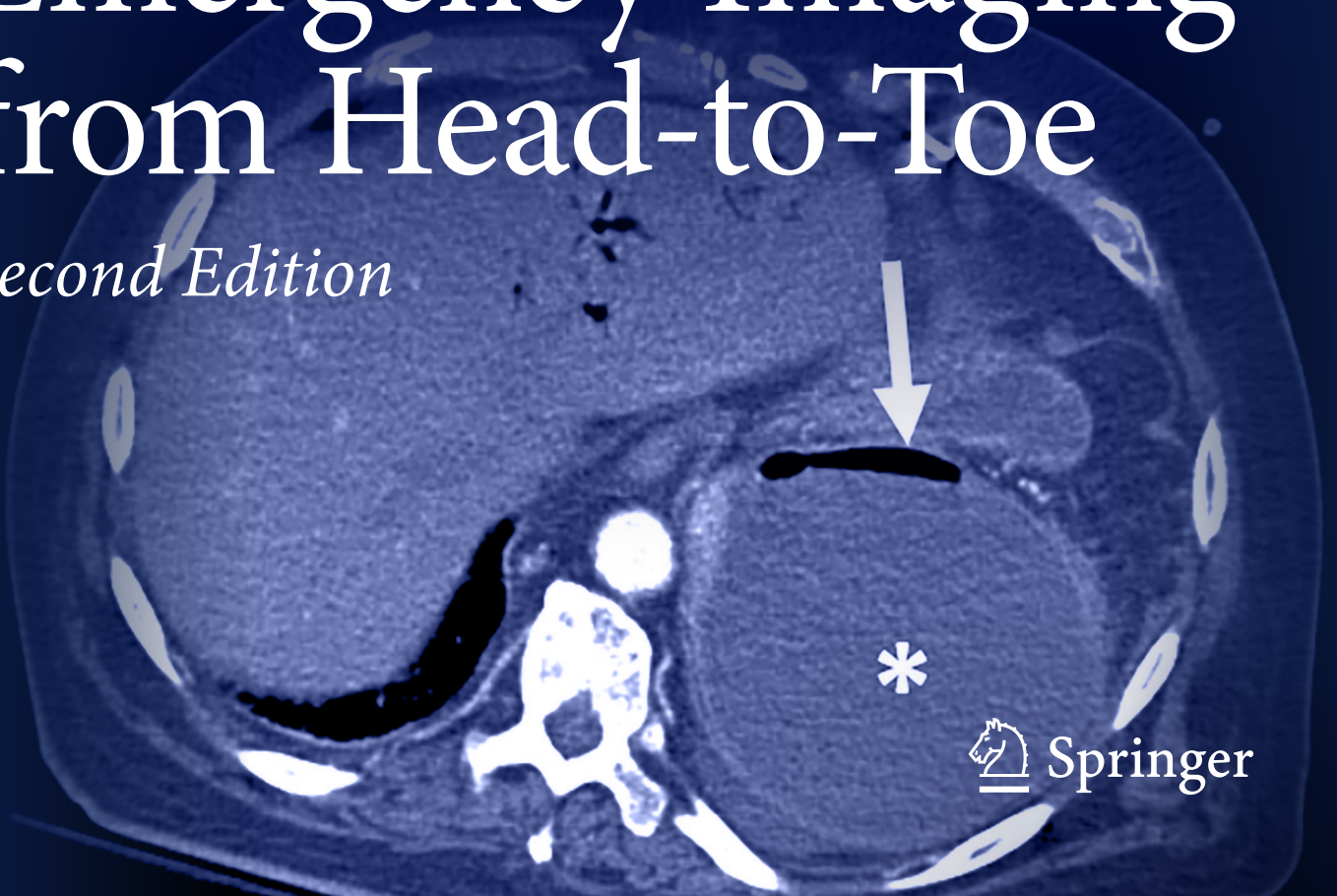


MICHAEL N. PATLAS  
DOUGLAS S. KATZ  
MARIANO SCAGLIONE  
*EDITORS*

# Atlas of Emergency Imaging from Head-to-Toe

*Second Edition*



---

# Atlas of Emergency Imaging from Head-to-Toe

---

Michael N. Patlas • Douglas S. Katz •  
Mariano Scaglione  
Editors

# Atlas of Emergency Imaging from Head-to-Toe

Second Edition

With 886 Figures and 53 Tables

 Springer

*Editors*

Michael N. Patlas  
Temerty Faculty of Medicine  
University of Toronto  
Toronto, ON, Canada

Douglas S. Katz  
NYU Langone Hospital - Long Island and the NYU Long  
Island School of Medicine  
Mineola, NY, USA

Mariano Scaglione  
Department of Medical, Surgical and Experimental Sciences  
University of Medicine and Surgery  
Sassari, Italy

ISBN 978-3-031-78915-1      ISBN 978-3-031-78916-8 (eBook)

<https://doi.org/10.1007/978-3-031-78916-8>

© Springer Nature Switzerland AG 2022, 2025

This work is subject to copyright. All rights are solely and exclusively licensed by the Publisher, whether the whole or part of the material is concerned, specifically the rights of translation, reprinting, reuse of illustrations, recitation, broadcasting, reproduction on microfilms or in any other physical way, and transmission or information storage and retrieval, electronic adaptation, computer software, or by similar or dissimilar methodology now known or hereafter developed.

The use of general descriptive names, registered names, trademarks, service marks, etc. in this publication does not imply, even in the absence of a specific statement, that such names are exempt from the relevant protective laws and regulations and therefore free for general use.

The publisher, the authors and the editors are safe to assume that the advice and information in this book are believed to be true and accurate at the date of publication. Neither the publisher nor the authors or the editors give a warranty, expressed or implied, with respect to the material contained herein or for any errors or omissions that may have been made. The publisher remains neutral with regard to jurisdictional claims in published maps and institutional affiliations.

This Springer imprint is published by the registered company Springer Nature Switzerland AG.  
The registered company address is: Gewerbestrasse 11, 6330 Cham, Switzerland

If disposing of this product, please recycle the paper.

*To Nataly Patlas, my wife, my best friend, my smartest adviser, and love of my life.*

*Michael N. Patlas*

*This book is dedicated to my Father, my Grandmother Sadie aka Bobby, and my Aunt Elinor. I hope that current and future advances in medicine, including in medical imaging and in emergency radiology, will prolong the lives of the loved ones of all who are reading this book, which was a team effort with numerous contributions from around the world.*

*The second edition of this book is also dedicated to the numerous trainees I have had the privilege to work with over the past 35 years, dating back to my own residency. I have probably learned as much if not more from them as they did from me, and the work which I participated in would not have been possible without their ideas, initiative, energy, and hard work. Many of them are now very accomplished in their own right, and are colleagues and friends.*

*Douglas S. Katz*

*To my parents, Pietro and Ida, and to my sons, Pietro and Ruben, my past, my present, my future...*

*Mariano Scaglione*

---

## Foreword

In this second edition of the *Atlas of Emergency Imaging from Head-to-Toe*, editors Drs. Michael Patlas, Douglas Katz, and Mariano Scaglione along with a team of international authors and experts in emergency imaging have provided an important update of their extensive atlas on imaging in the emergency setting. Given the progressive increase in the number and complexity of emergent imaging studies performed worldwide, this update and expansion of what already was a comprehensive review of the subject comes at an opportune time.

As in the first edition, Dr. Michael Patlas, Chair of the Department of Medical Imaging at the University of Toronto and the Editor-in-Chief of the *Canadian Association of Radiologists Journal*, edits an introductory part that begins with an overview of emergency and trauma imaging. This is followed by a chapter from Dr. Aaron Mintz and colleagues on the role of artificial intelligence in emergency radiology, which has tremendous potential in emergency imaging, from optimizing image acquisition to automated detection and grading of critical findings, critical study triage, and automated structured reporting. Chapters on interventional radiology and its role in managing the emergency patient, by Dr. Sebastian Mafeld and colleagues, review the spectrum of non-vascular and vascular procedures that are integral to both diagnosis and patient management in this setting.

What follows is a comprehensive review of emergency imaging topics organized by body section. Dr. Carlos Torres edits the part on neurologic emergencies by covering the spectrum of traumatic, vascular/hemorrhagic, and infectious entities encountered. These cases comprise a significant percentage of emergent studies performed at trauma and stroke centers and so this part should prove particularly useful to on-call radiology residents, emergency radiologists, and neuroradiologists. The five chapters on thoracic emergency imaging are again edited by Dr. Constantine Raptis. Of particular importance is the chapter on the imaging of acute aortic syndromes, in which a timely and accurate diagnosis can literally prove to be lifesaving. Following a revised chapter on the imaging of breast emergencies, the part on abdominal and pelvic imaging, edited by Dr. Vincent Mellnick, reviews the spectrum of solid organ, gastrointestinal, mesenteric, vascular, peritoneal, abdominal wall, and genitourinary and pelvic emergencies. Chapters addressing the emergency imaging of the bariatric and pregnant patient and abdominal and pelvic emergencies in oncologic patients cover important topics that typically receive scant coverage in other works on emergency imaging. The part on musculoskeletal emergency, edited by Drs. Kumaravel and Beckmann, reviews the imaging of traumatic injuries to the extremities and pelvis, with an additional chapter on nontraumatic musculoskeletal emergencies. The part on pediatric emergencies, edited by Dr. Elka Miller, provides a system-based review of emergent pediatric imaging, particularly useful to those that deal primarily with an adult population and may not be as familiar with the unique challenges encountered in the emergency pediatric setting.

This second edition of the *Atlas of Emergency Imaging from Head-to-Toe* offers the readers two new parts which nicely supplement those found in the original work. The first, edited by Dr. Iain Kirkpatrick, includes eight chapters providing a system-based approach to the emergency imaging of the geriatric patient, along with a chapter on the special considerations for interventional radiologic management in this growing population. The final part provides

guidance on several of the related administrative aspects of emergency radiology including perspectives on the finances and resources necessary to support a dedicated emergency radiology division, quality assurance issues, along with a chapter on the unique challenges of imaging the transplant patient. The final chapter reviews the issue of the imaging of intimate partner violence, defined as physical, sexual, or emotional violence between current or former partners, which is a subject championed by the author of this chapter, Dr. Bharti Khurana of Brigham and Women's Hospital in Boston, Massachusetts.

In a 2023 study reviewing trends in diagnostic imaging utilization in the emergency department in the United States, Poyiadji and colleagues [1] found that over a nearly 8-year period from 2014 to 2021 there were increases in imaging volumes for emergency department encounters of 35.5% and 56.3% for CT and MRI, respectively, at Level I trauma centers and more strikingly an increase of 74.6% in the use of CT at Level III trauma centers. The investigators found similarly that work RVUs (relative value units) increased by 34.9% and 76.6% for Level I and III trauma centers, respectively, primarily due to the increase in CT and MRI study volumes. As a result of these alarming trends in the utilization of emergency imaging which will almost certainly continue to increase, authoritative, up-to-date resources such as this updated atlas from Drs. Patlas, Katz, and Scaglione and their assembled group of internationally respected editors and authors take on greater importance in helping radiologists, emergency physicians, advanced practice providers, nurses, trainees, and allied healthcare professionals provide timely, accurate, and cost-effective care for the emergency patient.

Burlington, Vermont, USA

Jeffrey S. Klein

## References

1. Poyiadji N, Beauchamp N, Myers DT, Krupp S, Griffith B. Diagnostic imaging utilization in the emergency department: recent trends in volume and radiology work relative value units. *J Am Coll Radiol*. 2023;20(12):1207–14.

---

## Preface to the Second Edition

People choose careers in medicine in general and in radiology in particular to make a difference. Imaging has a tremendous role in all facets of modern medicine. However, there is no imaging subspecialty with so much immediate impact on the lives of acutely ill patients and also the potential for devastating consequences if errors are made, as does emergency and trauma imaging. Emergency imagers detect strokes in a timely fashion, effectively triage patients with acute chest pain, and advise surgeons and other ER personnel regarding the need for laparotomy or other procedures in trauma patients. Enormous technological advances and trust in the skills of emergency radiologists have caused continuous growth in emergency department (ED) imaging volumes in multiple countries around the world. Therefore, these critical decisions should be made quickly and quite often happen in the middle of the night or at the last hour of a 10- to 12-hour shift.

The co-editors-in-chief of this book have over 90 years of combined front lines imaging experience, and greatly enjoy teaching emergency and trauma imaging across the globe. During discussions with attendees at multiple conferences as well as at the weekly rounds with our own trainees and colleagues, we had been repeatedly asked whether there is a practical, updated, and comprehensive Emergency Radiology textbook for beginners as well as for seasoned professionals. The *Atlas of Emergency Imaging from Head-to-Toe* was conceived as a “one-stop source” for residents, fellows, and attendings in radiology dealing with challenging cases on call. The book also serves as a reference for our clinical colleagues. We have tried to avoid esoteric entities more suitable for a film panel at a national or international meeting and have focused on familiar conditions that can be encountered when one covers the ED as an emergency or general radiologist. According to the common expression, “a picture is worth a thousand words,” so this book is richly illustrated, and the chapters have been kept concise by the editors, to provide essential information which can be quickly digested in the stressful environments of the ED and the trauma suite.

We have used a classical head-to-toe approach, in keeping with the book title, with a few exceptions. The book starts with an overview of modalities used by emergency imagers, followed by a chapter describing the role of artificial intelligence in emergency imaging, and then two chapters defining the place of the interventional radiologist (IR) in the diagnosis and management of patients with vascular and non-vascular emergencies. Timely communication has particularly paramount importance in emergency imaging. For this reason, both interventional chapters describe when to call IR to avoid compromising the outcome of the emergency and/or trauma patient’s management. Imaging of acutely ill children is routinely performed by pediatric radiologists at major children’s hospitals. However, emergency radiologists are required to perform imaging interpretation in patients with pediatric emergencies in the community setting, and in some academic centers, with some degree of regularity. Therefore, the book contains a full part describing acute pediatric conditions pertinent to the practice of emergency imager. There are unique challenges facing radiologists interpreting images of older patients. Thus, for the Second Edition, we decided to add a new part on geriatric emergencies. We also added a part entitled “Special Considerations” to focus on quality assurance in Emergency Radiology (ER) and practical advice on building an ER section.

We are indebted to our outstanding Section Editors. Dr. Carlos Torres from the University of Ottawa served as the Section Editor for Neurological Emergencies. Dr. Constantine Raptis from the Mallinckrodt Institute of Radiology/Washington University in Saint Louis has edited the part on Thoracic Emergencies. Dr. Vincent Mellnick, also from Mallinckrodt, served as the Section Editor for Abdominal and Pelvic Emergencies. Drs. Manickam Kumaravel and Nicholas Beckmann from the University of Texas at Houston edited the part on Musculoskeletal Emergencies. Dr. Elka Miller from the University of Ottawa served as a Section Editor for Pediatric Emergencies. Dr. Iain Kirkpatrick from the University of Manitoba edited the part on Geriatric Emergencies. The book draws on the vast clinical experience of contributors from the largest medical centers across North America and Europe. It has been a privilege to work with our stellar team, and with all our contributing authors.

Toronto, Canada  
Mineola, USA  
Sassari, Italy  
July 2025

Michael N. Atlas  
Douglas S. Katz  
Mariano Scaglione

---

## Preface to the First Edition

People choose careers in medicine in general and in radiology in particular to make a difference. Imaging has a tremendous role in all facets of modern medicine. However, there is no imaging subspecialty with so much immediate impact on the lives of acutely ill patients and also the potential for devastating consequences if errors are made, as does emergency and trauma imaging. Emergency imagers detect strokes in a timely fashion, effectively triage patients with acute chest pain, and advise surgeons regarding the need for laparotomy in victims of major trauma. Enormous technological advances and trust in the skills of emergency radiologists have caused continuous growth in emergency department (ED) imaging volumes in multiple countries around the world. Therefore, these critical decisions should be made quickly and quite often happen in the middle of the night or at the last hour of a 12-h shift.

The coeditors-in-chief of this book have over 80 years of combined frontline imaging experience and enjoy teaching emergency and trauma imaging across the globe. During discussions with attendees at multiple conferences as well as at weekly rounds with our own trainees and colleagues, we had been repeatedly asked whether there is a practical, updated, and comprehensive emergency radiology textbook for beginners as well as for seasoned professionals. The *Atlas of Emergency Imaging from Head-to-Toe* was conceived as a “one-stop source” for residents, fellows, and junior attendings dealing with challenging cases on call, and also as a reference for experts looking for refreshers on challenging topics. We have tried to avoid esoteric entities more suitable for a film panel at a national or international meeting, and have focused on familiar conditions which can be encountered when you cover the ED as an emergency or general radiologist. According to the common expression, “a picture is worth a thousand words,” so this book is richly illustrated and the chapters have been kept concise by the editors, to provide essential information which can be quickly digested in the stressful environments of the ED and the trauma suite.

We have used a classical head-to-toe approach, with a few exceptions. The book starts with an overview of modalities used by emergency imagers, followed by a chapter describing the role of artificial intelligence in emergency imaging, and then two chapters defining the place of the interventional radiologist (IR) in the diagnosis and management of patients with vascular and non-vascular emergencies. Timely communication has particularly paramount importance in emergency imaging. For this reason, both interventional chapters describe when to call IR to avoid compromising the outcome of the emergency and/or trauma patient’s management. Imaging of acutely ill children is routinely performed by pediatric radiologists at major children’s hospitals. However, emergency radiologists are required to perform imaging interpretation in patients with pediatric emergencies in the community setting with some degree of regularity. Therefore, the book contains a full section describing acute pediatric conditions pertinent for the practice of emergency imager. In the editors’ opinion, there are two additional groups of patients with unique imaging presentations justifying dedicated chapters: pregnant patients and bariatric patients.

We are indebted to our outstanding Section Editors. Dr. Carlos Torres from the University of Ottawa served as the Section Editor for Neurological Emergencies. Dr. Constantine Raptis from the Mallinckrodt Institute of Radiology/Washington University in Saint Louis has edited the

Thoracic Emergencies Section. Dr. Vincent Mellnick, also from Mallinckrodt, served as the Section Editor for Abdominal and Pelvic Emergencies. Drs. Manickam Kumaravel and Nicholas Beckmann from the University of Texas at Houston edited the section on Musculoskeletal Emergencies. Dr. Elka Miller from the University of Ottawa served as a Section Editor for Pediatric Emergencies. The book draws on the vast clinical experience of contributors from the largest medical centers across North America and Europe. It has been a privilege to work with our stellar team and with all of our contributing authors.

Hamilton, Canada  
Long Island, USA  
Sassari, Italy  
June 2022

Michael N. Patlas  
Douglas S. Katz  
Mariano Scaglione

---

# Contents

<b>Part I General Considerations in Emergency Imaging</b> . . . . .	1
<b>Emergency and Trauma Imaging</b> . . . . .	3
Michael N. Patlas, Douglas S. Katz, and Devang Odedra	
<b>Role of Artificial Intelligence in Emergency Radiology</b> . . . . .	11
Karan Jani, Govind Mattay, and Aaron Mintz	
<b>Vascular Emergencies</b> . . . . .	21
B. Warren, E. Qazi, M. J. Tao, George Oreopoulos, G. Annamalai, and Sebastian Mafeld	
<b>Nonvascular Emergencies</b> . . . . .	41
Abdullah O. Alenezi, Neeral R. Patel, Arash Mir-Rahimi, Ali Helmi, Arash Jaber, and Sebastian Mafeld	
<b>Part II Neurological Emergencies</b> . . . . .	55
<b>Imaging of Traumatic Brain Injury</b> . . . . .	57
Walter F. Wiggins, Austin X. Dixon, and Peter G. Kranz	
<b>Imaging of Skull Base Fractures and Complications</b> . . . . .	75
Ngoc-Anh Tran, Diego B. Nunez, and Christopher A. Potter	
<b>Imaging of Midfacial and Orbital Trauma</b> . . . . .	93
Claudia F. E. Kirsch	
<b>Stroke Imaging</b> . . . . .	107
Johanna Maria Ospel, Petra Cimflova, and Mayank Goyal	
<b>Imaging of Brain Infections</b> . . . . .	121
Nader Zakhari, Shivaprakash Hiremath, Paulo Puac-Polanco, Angela Patricia Guarnizo, Francisco Rivas-Rodriguez, and Carlos Torres	
<b>Imaging of Spontaneous Intracranial Hemorrhage</b> . . . . .	135
Carlos Zamora and Mauricio Castillo	
<b>Imaging of Traumatic Vascular Neck Injuries</b> . . . . .	151
Daniel Furlanetto, Marc Jutras, Nicolas Murray, and Savvas Nicolaou	
<b>Imaging of Neck and Facial Infections</b> . . . . .	169
Prachi Dubey, Amy Juliano, and Gul Moonis	
<b>Imaging of Spinal Trauma with MRI: A Practical Guide</b> . . . . .	185
Jason F. Talbott, John F. Burke, Andrew Callen, Vinil Shah, Jared Narvid, and Sanjay S. Dhall	

<b>Imaging of Nontraumatic Spinal Emergencies . . . . .</b>	<b>205</b>
Shekhar D. Khanpara, F. Eymen Ucisik, and Roy F. Riascos	
<b>Part III Thoracic Emergencies . . . . .</b>	<b>223</b>
<b>Imaging of Nonvascular Thoracic Trauma . . . . .</b>	<b>225</b>
Kevin Neal and Muhammad Naeem	
<b>Imaging of Thoracic Vascular Trauma . . . . .</b>	<b>247</b>
Travis S. Henry, Brian M. Haas, and Scott A. Hamlin	
<b>Acute Aortic Syndrome Imaging . . . . .</b>	<b>269</b>
Kacie L. Steinbrecher, Sanjeev Bhalla, Kaitlin M. Marquis, and Constantine A. Raptis	
<b>Imaging of Pulmonary Infections . . . . .</b>	<b>285</b>
Suzanne C. Byrne, Mark M. Hammer, and Richard Thomas	
<b>Imaging of Breast Emergencies . . . . .</b>	<b>299</b>
Mostafa Alabousi, Abdullah Alabousi, Supriya Kulkarni, and Michael N. Patlas	
<b>Part IV Abdominal and Pelvic Emergencies . . . . .</b>	<b>311</b>
<b>Imaging of Blunt Hepatic and Biliary Injuries . . . . .</b>	<b>313</b>
Francesca Iacobellis, Tyler J. Fraum, Luigia Romano, Raffaella Niola, Vincent M. Mellnick, Salvatore Masala, and Mariano Scaglione	
<b>Imaging of Blunt Pancreatic Injuries . . . . .</b>	<b>327</b>
Daniel Oppenheimer and Kent Upham	
<b>Imaging of Blunt Splenic Injuries . . . . .</b>	<b>337</b>
Baher R. A. Guirguis, Jennifer F. True, and James T. Lee	
<b>Imaging of Blunt Bowel and Mesenteric Injuries . . . . .</b>	<b>353</b>
Raffaella Basilico, Andrea Delli Pizzi, Alessio Taraschi, Barbara Seccia, and Roberta Cianci	
<b>Imaging of Blunt Genitourinary Trauma . . . . .</b>	<b>365</b>
Gayatri Joshi, Charlotte Y. Chung, and Brittany T. Lewis	
<b>Imaging of Penetrating Abdominal and Pelvic Trauma . . . . .</b>	<b>383</b>
David H. Ballard, Muhammad Naeem, Mark J. Hoegger, Mohamed Z Rajput, and Vincent M. Mellnick	
<b>Imaging After Damage Control Surgery . . . . .</b>	<b>397</b>
Armonde Baghdanian, Arthur Baghdanian, Thuy-Huong Pham, and Scott D. Steenburg	
<b>Imaging of Nontraumatic Hepatobiliary Emergencies . . . . .</b>	<b>411</b>
HeiShun Yu and Jennifer W. Uyeda	
<b>Imaging of Nontraumatic Splenic Emergencies . . . . .</b>	<b>423</b>
Maria Zulfiqar and Vincent M. Mellnick	
<b>Imaging of Nontraumatic Gastrointestinal Emergencies . . . . .</b>	<b>435</b>
Varun Razdan and Meghan Lubner	
<b>Nontraumatic Emergent Genitourinary Conditions . . . . .</b>	<b>451</b>
Victoria Chernyak	

<b>Imaging of Pelvic Emergencies</b> . . . . .	465
Victoria Chernyak	
<b>Imaging of Nontraumatic Vascular Emergencies</b> . . . . .	485
Daniel R. Ludwig and Motoyo Yano	
<b>Imaging of Nontraumatic Abdominal Wall and Peritoneal Emergencies</b> . . . . .	503
Mohamed Zak Rajput and David H. Ballard	
<b>Emergency Imaging of the Bariatric Surgery Patient</b> . . . . .	519
Daniel R. Ludwig and Christine O. Menias	
<b>Emergency Imaging of Pregnant Patient</b> . . . . .	543
Donghoon Shin, John Lee, and Christina A. LeBedis	
<b>Oncologic Emergencies: Focus on the Abdomen and Pelvis</b> . . . . .	559
Pablo Palacios, Noah Gafen, and Jeffrey Levine	
<b>Part V Musculoskeletal Emergencies</b> . . . . .	573
<b>Imaging of Shoulder Trauma</b> . . . . .	575
Yunib H. Munir and Nicholas M. Beckmann	
<b>Imaging of Elbow Trauma</b> . . . . .	595
Nicholas M. Beckmann and Kimberley N. Brown	
<b>Imaging of Hand and Wrist Trauma</b> . . . . .	613
Jordan R. Pollock, Thomas Wong, Jeremiah Long, and Jonathan Flug	
<b>Imaging of Pelvis and Hip Trauma</b> . . . . .	631
Jake M. Adkins and Nicholas M. Beckmann	
<b>Imaging of Knee Injuries</b> . . . . .	651
Pritish Bawa and Vaeman Chintamaneni	
<b>Imaging of Ankle and Foot Injuries</b> . . . . .	671
Joshua Gu, Saagar Patel, and Manickam Kumaravel	
<b>Nontraumatic Musculoskeletal Emergencies</b> . . . . .	691
Muhayman Sadiq, Saagar Patel, Gregg W. Bean, and Manickam Kumaravel	
<b>Part VI Pediatric Emergencies</b> . . . . .	705
<b>Imaging of Pediatric Traumatic and Nontraumatic Brain Emergencies</b> . . . . .	707
Prakash Muthusami, Adam A. Dmytriw, and Manohar M. Shroff	
<b>Imaging of Pediatric Head and Neck Emergencies</b> . . . . .	721
Elka Miller, Claudia Martinez-Rios, Laura Acosta-Izquierdo, and Sara R. Teixeira	
<b>Imaging of Pediatric Traumatic and Nontraumatic Spinal Emergencies</b> . . . . .	739
Matthias W. Wagner and Birgit B. Ertl-Wagner	
<b>Imaging of Pediatric Musculoskeletal Emergencies</b> . . . . .	759
Colin Brown and Rebecca Stein-Wexler	
<b>Imaging of Pediatric Nontraumatic Musculoskeletal Emergencies</b> . . . . .	777
Kayla Cort and Rebecca Stein-Wexler	

<b>Imaging of Pediatric Traumatic and Non-traumatic Chest Emergencies</b> . . . . .	793
Katya Rozovsky, Martin Bunge, Hayley Moffatt, Jens Wrogemann, and Martin H. Reed	
<b>Imaging of Pediatric Traumatic and Nontraumatic Abdominal and Pelvic Emergencies</b> . . . . .	811
Margherita Trinci, Marco Di Maurizio, Enrica Rossi, Ginevra Danti, and Vittorio Miele	
<b>Pediatric Emergencies: Role of the Interventional Radiologist</b> . . . . .	823
Gali Shapira-Zaltsberg, Michael Temple, and Joao Amaral	
<b>Part VII Geriatric Emergencies</b> . . . . .	839
<b>Traumatic Brain Injury in Geriatric Patients</b> . . . . .	841
Maria Juliana Borja, Angela Patricia Guarnizo, Gaurav Saigal, and Kim Caban	
<b>Non-traumatic Brain Emergencies in Geriatric Patients</b> . . . . .	853
Bilal Battal and Carlos Zamora	
<b>Traumatic and Nontraumatic Spine Emergencies in Geriatric Patients</b> . . . . .	877
Paulo Puac-Polanco, Andres Rodriguez, Shivaprakash Hiremath, Roy F. Riascos, and Carlos Torres	
<b>Thoracic and Cardiac Emergencies in Geriatric Patients</b> . . . . .	893
Adam D. Naylor, Sanjeev Bhalla, Mohamed Zak Rajput, and Demetrios A. Raptis	
<b>Abdominal Emergencies in Geriatric Patients</b> . . . . .	905
Iain D. C. Kirkpatrick	
<b>Musculoskeletal Trauma in Elderly Patients</b> . . . . .	921
Saagar Patel, Muhayman Sadiq, Rohan Manickam, and Manickam Kumaravel	
<b>Geriatric Considerations in Emergency Interventional Radiology</b> . . . . .	937
Ali Helmi, Cathal O’Leary, Camilo Barragan Leal, Aly Fawzy, George Oreopoulos, Arash Jaber, and Sebastian Mafeld	
<b>Part VIII Special Considerations</b> . . . . .	949
<b>How to Run a Successful Emergency Radiology Division</b> . . . . .	951
Waqas Ahmad, Abu-Omar Ahmad, Adnan Sheikh, Ismail Ali, and Savvas Nicolaou	
<b>Peer Review, Peer Learning, and Quality Assurance in Emergency Radiology in Daily Practice</b> . . . . .	963
Miltiadis Tembelis, Selin Ocal, Jenny Lu, and Douglas S. Katz	
<b>Emergency Imaging of Transplant Patients</b> . . . . .	971
M. Hunter Lanier and Vincent M. Mellnick	
<b>Intimate Partner Violence</b> . . . . .	989
Irene Dixe de Oliveira Santo, Babina Gosangi, and Bharti Khurana	
<b>Index</b> . . . . .	1005

---

## About the Editors



**Michael N. Patlas, MD, FRCPC, FASER, FCAR, FSAR**, is a Professor and Chair, Department of Medical Imaging, Temerty Faculty of Medicine, University of Toronto. He leads the largest academic medical imaging department in Canada with over 550 talented faculty members and trainees. He is the Editor-in-Chief for *Canadian Association of Radiologists Journal* and five radiology books, and author of over 230 peer-reviewed papers, editorials, and book chapters. He has presented 262 invited lectures and scientific and educational abstracts. His Editorial Board memberships (past or current) include journals such as *AJR*, *Diagnostic & Interventional Imaging*, *La Radiologia Medica*, *Emergency Radiology*, *Current Problems in Diagnostic Radiology*, *Current Radiology Reports*, and *Annals of Clinical and Laboratory Science*. He is President of Canadian Emergency, Trauma and Acute Care Radiology Society. He is an honored fellow of the American Society of Emergency Radiology, the Canadian Association of Radiologists, and the Society of Abdominal Radiology. He received Gold Medal from the European Society of Emergency Radiology in 2022, and Medal of Excellence from the Canadian Emergency, Trauma and Acute Care Radiology Society in 2024. He is an Honored Member of the Association of Radiologists of Ukraine and the Society of Emergency Radiology, India.



**Douglas S. Katz** is Vice-Chair for Research at NYU (New York University) Langone Hospital—Long Island, and Professor of Radiology at the NYU Grossman Long Island School of Medicine (NYU GLISOM) (on the Scholar Track—Clinical). He has held essentially the same position since 1999 and has been attending what was formerly Winthrop-University Hospital since 1996. He has coauthored over 1000 peer-reviewed publications and abstracts, and multiple books, syllabi, book chapters, and other publications. He has held a variety of positions in organized academic radiology regionally, nationally, and internationally over his three-decade career; has been awarded top honors from his hospital and medical school; and has been Attending of the Year seven times, most recently in 2022, two of which for internal medicine (although he is board certified only in diagnostic radiology). Other recent major honors include Lifetime Honored Educator from the RSNA in 2023, and the Dean's Award for Excellence in Clinical Research and Scholarship from the NYU GLISOM in 2023 (the only recipient that year). With diverse interests and extensive

writing and reviewing and editorial experience, his focus since residency has been on various aspects of emergency radiology, as well as on cross-sectional imaging in general.



**Mariano Scaglione** is Professor of Radiology at the University of Sassari, IT and Consultant Radiologist at the James Cook University Hospital at Middleborough, UK.

He was the Chairman for the Emergency Radiology Subcommittee for ECR in 2012, President of the Italian College of Emergency Radiology SIRM (2010–2014), and ESER Founding President (2015–2017). He has been a member of the Emergency Radiology subcommittee of the Scientific Program for RSNA (2012–2018). He is a seasoned speaker having delivered more than 500 presentations at national and international meetings and published author, publishing more than 230 papers, editing 14 books, and primary author for 32 book chapters. He was also appointed Lead Editor for the Emergency Radiology Trilogy books for Springer. He is Editorial Board Member in many Radiology journals including *Emergency Radiology* the official journal of the ASER since 2005.

He was awarded the “Gold Medal” 2014 and Honorary Member 2019 for ESER.

---

## Section Editors

**Nicholas M. Beckmann** UTHealth-McGovern School of Medicine, Houston, TX, USA



**Iain D. C. Kirkpatrick**  
University of Manitoba  
Winnipeg, MB, Canada



**Manickam Kumaravel**  
Department of Diagnostic and Interventional Imaging  
McGovern Medical School at UTHealth Houston  
Houston, TX, USA



**Vincent M. Mellnick**  
Mallinckrodt Institute of Radiology  
Washington University School of Medicine  
St. Louis, MO, USA

**Elka Miller**

Department of Medical Imaging, Temerty Faculty of Medicine,  
The Hospital for Sick Children, Department of Diagnostic and  
Interventional Radiology  
University of Toronto  
Toronto, ON, Canada

**Constantine Raptis**

Mallinckrodt Institute of Radiology  
St. Louis, MO, USA

**Carlos Torres**

Department of Radiology, Radiation Oncology and  
Medical Physics  
University of Ottawa  
Ottawa, ON, Canada

---

## Contributors

**Laura Acosta-Izquierdo** Pediatric Radiologist, Department of Radiology, Children's Hospital Colorado, University of Colorado, Ottawa, ON, Canada

**Jake M. Adkins** UTHealth – McGovern School of Medicine, Houston, TX, USA

**Abu-Omar Ahmad** Department of Radiology, Vancouver General Hospital/University of British Columbia, Vancouver, BC, Canada

**Waqas Ahmad** Department of Radiology, Vancouver General Hospital/University of British Columbia, Vancouver, BC, Canada

**Abdullah Alabousi** Department of Radiology, McMaster University, St. Joseph's Healthcare Hamilton, Hamilton, ON, Canada

**Mostafa Alabousi** William Osler Health System, Toronto Metropolitan University, University of Toronto, Toronto, Canada

**Abdullah O. Alenezi** Faculty of Medicine, Kuwait University, Kuwait City, Kuwait

**Ismail Ali** Department of Radiology, Vancouver General Hospital/University of British Columbia, Vancouver, BC, Canada

**Joao Amaral** Division of Image-Guided Therapy (IGT), Department of Diagnostic Imaging, The Hospital for Sick Children, Medical Imaging Department, University of Toronto, Toronto, ON, Canada

**G. Annamalai** Division of Interventional Radiology, Department of Medical Imaging, University Health Network, Toronto, ON, Canada

**Armonde Baghdanian** Department of Radiology, Keck School of Medicine, University of Southern California, Los Angeles, CA, USA

**Arthur Baghdanian** Department of Radiology, Keck School of Medicine, University of Southern California, Los Angeles, CA, USA

**David H. Ballard** Mallinckrodt Institute of Radiology, Washington University School of Medicine, St. Louis, MO, USA

**Raffaella Basilico** Department of Medical, Oral and Biotechnological Sciences, G. D'Annunzio University of Chieti, Chieti, Italy

**Bilal Battal** Division of Neuroradiology, Department of Radiology, University of North Carolina School of Medicine, Chapel Hill, NC, USA

**Pritish Bawa** Department of Diagnostic & Interventional Imaging, McGovern Medical School at UT Health, Houston, TX, USA

**Gregg W. Bean** Department of Radiology, UTHealth San Antonio Long School of Medicine, San Antonio, TX, USA

- Nicholas M. Beckmann** UTHealth – McGovern School of Medicine, Houston, TX, USA
- Sanjeev Bhalla** Mallinckrodt Institute of Radiology, Washington University in St. Louis, St. Louis, MO, USA
- Maria Juliana Borja** Division of Neuroradiology, Department of Radiology, University of Miami, Miami, FL, USA
- Colin Brown** Department of Radiology, University of Chicago Medicine, Chicago, IL, USA
- Kimberley N. Brown** UTHealth – McGovern School of Medicine, Houston, TX, USA
- Martin Bunge** Section of Pediatric Radiology, Children’s Hospital, Department of Radiology, University of Manitoba, Winnipeg, MB, Canada
- John F. Burke** Brain and Spine Injury Center, Zuckerberg San Francisco General Hospital and Trauma Center, San Francisco, CA, USA  
Department of Neurological Surgery, University of California, San Francisco, CA, USA
- Suzanne C. Byrne** Division of Thoracic Imaging, Department of Radiology, Brigham and Women’s Hospital, Harvard Medical School, Boston, MA, USA
- Kim Caban** Division of Emergency Radiology, Department of Radiology, University of Miami, Miami, FL, USA
- Andrew Callen** Department of Radiology, University of Colorado Anschutz Medical Campus, Denver, CO, USA
- Mauricio Castillo** Division of Neuroradiology, Department of Radiology, University of North Carolina School of Medicine, Chapel Hill, NC, USA
- Victoria Chernyak** Beth Israel Deaconess Medical Center, Boston, MA, USA
- Vaeman Chintamaneni** Department of Diagnostic & Interventional Imaging, McGovern Medical School at UT Health, Houston, TX, USA
- Charlotte Y. Chung** Department of Radiology, New York University Grossman School of Medicine, New York, NY, USA
- Roberta Cianci** Department of Neuroscience, Imaging and Clinical Sciences, G. d’Annunzio University of Chieti, Chieti, Italy
- Petra Cimflova** Departments of Radiology and Clinical Neurosciences, University of Calgary, Foothills Medical Centre, Calgary, AB, Canada  
Department of Medical Imaging, St. Anne’s University Hospital Brno and Faculty of Medicine, Masaryk University, Brno, Czech Republic
- Kayla Cort** Benioff Children’s Hospitals, University of California, San Francisco and Oakland, CA, USA
- Ginevra Danti** Department of Radiology, Azienda Ospedaliero Universitaria Careggi, Florence, Italy
- Sanjay S. Dhall** Brain and Spine Injury Center, Zuckerberg San Francisco General Hospital and Trauma Center, San Francisco, CA, USA  
Department of Neurological Surgery, University of California, San Francisco, CA, USA
- Marco Di Maurizio** Department of Radiology, Azienda Ospedaliero Universitaria Meyer, Florence, Italy
- Irene Dixe de Oliveira Santo** Yale Radiology and Biomedical Imaging, New Haven, CT, USA

**Austin X. Dixon** Department of Radiology, Duke University Medical Center, Durham, NC, USA

**Adam A. Dmytriw** Neuroradiology and Image Guided Therapy, Diagnostic Imaging, The Hospital for Sick Children, and University of Toronto, Toronto, ON, Canada

**Prachi Dubey** Houston Methodist Hospital, Houston Radiology Associated, Houston, TX, USA

**Birgit B. Ertl-Wagner** Division of Neuroradiology, Department of Diagnostic & Interventional Radiology, The Hospital for Sick Children, Toronto, ON, Canada

Department of Medical Imaging, University of Toronto, Toronto, ON, Canada

**Aly Fawzy** Temerty Faculty of Medicine, University of Toronto, Toronto, ON, Canada

**Jonathan Flug** Mayo Clinic Arizona, Department of Radiology, Phoenix, AZ, USA

**Tyler J. Fraum** Department of Abdominal Imaging & Nuclear Medicine, Mallinckrodt Institute of Radiology, Washington University School of Medicine, Barnes-Jewish Hospital, St. Louis, MO, USA

**Daniel Furlanetto** Department of Radiology, Vancouver General Hospital/University of British Columbia, Vancouver, BC, Canada

**Noah Gafen** Department of Radiology, Lenox Hill Hospital/Northwell Health, New York, NY, USA

**Babina Gosangi** Yale Radiology and Biomedical Imaging, New Haven, CT, USA

**Mayank Goyal** Departments of Radiology and Clinical Neurosciences, University of Calgary, Foothills Medical Centre, Calgary, AB, Canada

**Joshua Gu** UTHealth – McGovern School of Medicine, Houston, TX, USA

**Angela Patricia Guarnizo** Division of Neuroradiology, Department of Radiology, Hospital Universitario Fundación Santa Fe de Bogotá, Bogotá, Colombia

**Baher R. A. Guirguis** Department of Radiology, University of Kentucky, Lexington, KY, USA

**Brian M. Haas** Zuckerberg San Francisco General Hospital and University of California San Francisco, San Francisco, CA, USA

**Scott A. Hamlin** Emory University School of Medicine, Atlanta, GA, USA

**Mark M. Hammer** Division of Thoracic Imaging, Department of Radiology, Brigham and Women's Hospital, Harvard Medical School, Boston, MA, USA

**Ali Helmi** Division of Interventional Radiology, University Health Network, Toronto General Hospital, Toronto, ON, Canada

**Travis S. Henry** Duke University School of Medicine, Durham, NC, USA

**Shivaprakash Hiremath** Department of Radiology, Division of Neuroradiology, University of Ottawa, Ottawa, ON, Canada

Department of Medical Imaging, Toronto Western Hospital, University of Toronto, Toronto, ON, Canada

**Mark J. Hoegger** Mallinckrodt Institute of Radiology, Washington University School of Medicine, St. Louis, MO, USA

**Francesca Iacobellis** Department of General and Emergency Radiology, “A. Cardarelli” Hospital, Naples, Italy

**Arash Jaberi** Division of Interventional Radiology, University Health Network, Toronto General Hospital, Toronto, ON, Canada

**Karan Jani** Mallinckrodt Institute of Radiology, Saint Louis, MO, USA

**Gayatri Joshi** Department of Radiology and Imaging Sciences, Emory University School of Medicine, Atlanta, GA, USA

**Amy Juliano** Massachusetts Eye and Ear, Harvard Medical School, Boston, USA

**Marc Jutras** Department of Radiology, Vancouver General Hospital/University of British Columbia, Vancouver, BC, Canada

**Douglas S. Katz** NYU Langone Hospital – Long Island and the NYU Long, Island School of Medicine, Mineola, NY, USA

**Shekhar D. Khanpara** Department of Diagnostic and Interventional Imaging, University of Texas Health Science Center at Houston, Houston, TX, USA

**Bharti Khurana** Trauma Imaging Research and Innovation Center, Brigham and Women's Hospital, Harvard Medical School, Boston, MA, USA

**Iain D. C. Kirkpatrick** University of Manitoba, Winnipeg, MB, Canada

**Claudia F. E. Kirsch** Department of Radiology and Biomedical Imaging, Yale University, New York City, USA

The School of Clinical Dentistry, University of Sheffield, New York City, USA

Molecular and Interventional Radiology Biomedical Engineering Imaging, Mount Sinai Hospital, New York City, USA

**Peter G. Kranz** Department of Radiology, Duke University Medical Center, Durham, NC, USA

**Supriya Kulkarni** Department of Medical Imaging, University of Toronto, Princess Margaret Hospital, Toronto, ON, Canada

**Manickam Kumaravel** Department of Diagnostic and Interventional Imaging, McGovern Medical School at UTHealth Houston, Houston, TX, USA

**M. Hunter Lanier** Mallinckrodt Institute of Radiology, Washington University School of Medicine St. Louis, St. Louis, MO, USA

**Camilo Barragan Leal** Division of Interventional Radiology, University Health Network, Toronto General Hospital, Toronto, ON, Canada

**Christina A. LeBedis** Department of Radiology, Boston Medical Center, Boston, MA, USA

**James T. Lee** Department of Radiology, University of Kentucky, Lexington, KY, USA

**John Lee** Department of Interventional Radiology, Brown Health Providence, RI, USA

**Jeffrey Levine** Department of Radiology, Lenox Hill Hospital/Northwell Health, New York, NY, USA

**Brittany T. Lewis** Emergency Radiology, Southwest Medical Imaging (SMIL), Radiology Partners, Scottsdale, AZ, USA

**Jeremiah Long** Mayo Clinic Arizona, Department of Radiology, Phoenix, AZ, USA

**Jenny Lu** Touro College of Osteopathic Medicine, Harlem, NY, USA

**Meghan Lubner** University of Wisconsin School of Medicine and Public Health, Madison, WI, USA

**Daniel R. Ludwig** Mallinckrodt Institute of Radiology, Washington University School of Medicine, Saint Louis, MO, USA

**Sebastian Mafeld** Division of Interventional Radiology, Department of Medical Imaging, University Health Network, Toronto General Hospital, Toronto, ON, Canada  
Temerty Faculty of Medicine, University of Toronto, Toronto, ON, Canada

**Rohan Manickam** Department of Diagnostic and Interventional Imaging, McGovern Medical School at UTHealth Houston, Houston, TX, USA

**Kaitlin M. Marquis** Mallinckrodt Institute of Radiology, St. Louis, MO, USA

**Claudia Martinez-Rios** Department of Medical Imaging Temerty Faculty of Medicine, The Hospital for Sick Children, Department of Diagnostic and Interventional Radiology, University of Toronto, Toronto, ON, Canada

**Salvatore Masala** Department of Medicine, Surgery and Pharmacy, University of Medicine and Surgery, Sassari, Italy

**Govind Mattay** Mallinckrodt Institute of Radiology, Saint Louis, MO, USA

**Vincent M. Mellnick** Mallinckrodt Institute of Radiology, Washington University School of Medicine St. Louis, St. Louis, MO, USA

**Christine O. Menias** Mayo Clinic Department of Radiology, Scottsdale, AZ, USA

**Vittorio Miele** Department of Radiology, Azienda Ospedaliero Universitaria Careggi, Florence, Italy

**Elka Miller** Department of Medical Imaging Temerty Faculty of Medicine, The Hospital for Sick Children, Department of Diagnostic and Interventional Radiology, University of Toronto, Toronto, ON, Canada

**Aaron Mintz** Mallinckrodt Institute of Radiology, Saint Louis, MO, USA

**Arash Mir-Rahimi** Division of Interventional Radiology, Oak Valley Health, Markham, ON, Canada

**Hayley Moffatt** Section of Pediatric Radiology, Children's Hospital, Department of Radiology, University of Manitoba, Winnipeg, MB, Canada

**Gul Moonis** New York University Langone Health, NYU Grossman School of Medicine, New York, NY, USA

**Yunib H. Munir** UTHealth – McGovern School of Medicine, Houston, TX, USA

**Nicolas Murray** Department of Radiology, Vancouver General Hospital/University of British Columbia, Vancouver, BC, Canada

**Prakash Muthusami** Neuroradiology and Image Guided Therapy, Diagnostic Imaging, The Hospital for Sick Children, and University of Toronto, Toronto, ON, Canada

**Muhammad Naeem** Emory University School of Medicine, Atlanta, GA, USA  
Mallinckrodt Institute of Radiology, Washington University School of Medicine, St. Louis, MO, USA

**Jared Narvid** Department of Radiology and Biomedical Imaging, UCSF and Zuckerberg San Francisco General Hospital and Trauma Center, San Francisco, CA, USA

**Adam D. Naylor** Mallinckrodt Institute of Radiology, Washington University in St. Louis, St. Louis, MO, USA

**Kevin Neal** Mallinckrodt Institute of Radiology, St. Louis, MO, USA

**Savvas Nicolaou** Department of Radiology, Vancouver General Hospital/University of British Columbia, Vancouver, BC, Canada

**Raffaella Niola** Department of Diagnostic and Interventional Radiology, “A. Cardarelli” Hospital, Naples, Italy

**Diego B. Nunez** Department of Radiology, Brigham and Women’s Hospital, Harvard Medical School, Boston, MA, USA

**Cathal O’Leary** Division of Interventional Radiology, University Health Network, Toronto General Hospital, Toronto, ON, Canada

**Selin Ocal** John Hopkins School of Medicine, Baltimore, MD, USA

**Devang Odedra** Department of Medical Imaging, North York General Hospital, Toronto, ON, Canada

Department of Medical Imaging, University of Toronto, Toronto, ON, Canada

**Daniel Oppenheimer** Abdominal Imaging Division, Department of Imaging Sciences, University of Rochester Medical Center, Rochester, NY, USA

**George Oreopoulos** Division of Interventional Radiology, Department of Medical Imaging, University Health Network, Toronto General Hospital, Toronto, ON, Canada

Department of Surgery, Division of Vascular Surgery, University Health Network, Toronto, ON, Canada

**Johanna Maria Ospel** Department of Radiology, University Hospital Basel, University of Basel, Basel, Switzerland

Departments of Radiology and Clinical Neurosciences, University of Calgary, Foothills Medical Centre, Calgary, AB, Canada

**Pablo Palacios** Department of Radiology, Lenox Hill Hospital/Northwell Health, New York, NY, USA

**Neeral R. Patel** Division of Interventional Radiology, Imperial College Healthcare NHS Trust, London, UK

**Saagar Patel** Department of Diagnostic and Interventional Imaging, McGovern Medical School at UTHealth Houston, Houston, TX, USA

**Michael N. Patlas** Temerty Faculty of Medicine, University of Toronto, Toronto, ON, Canada

**Thuy-Huong Pham** Department of Surgery, Indiana University School of Medicine, Indianapolis, IN, USA

**Andrea Delli Pizzi** Department of Neuroscience, Imaging and Clinical Sciences, G. d’Annunzio University of Chieti, Chieti, Italy

**Jordan R. Pollock** Mayo Clinic Arizona, Department of Radiology, Phoenix, AZ, USA

**Christopher A. Potter** Department of Radiology, Brigham and Women’s Hospital, Harvard Medical School, Boston, MA, USA

**Paulo Puac-Polanco** Department of Radiology, Radiation Oncology and Medical Physics, University of Ottawa, Ottawa, ON, Canada

Department of Radiology, Division of Neuroradiology, University of Ottawa, Ottawa, ON, Canada

**E. Qazi** Department of Interventional Radiology, Mackenzie Health, Toronto, ON, Canada

**Mohamed Zak Rajput** Mallinckrodt Institute of Radiology, Washington University School of Medicine, St. Louis, MO, USA

**Constantine A. Raptis** Mallinckrodt Institute of Radiology, St. Louis, MO, USA

**Demetrios A. Raptis** Mallinckrodt Institute of Radiology, Washington University in St. Louis, St. Louis, MO, USA

**Varun Razdan** Advanced Medical Imaging Consultants, P.C., Fort Collins, CO, USA

**Martin H. Reed** Section of Pediatric Radiology, Children's Hospital, Departments of Radiology and of Pediatrics and Child Health, University of Manitoba, Winnipeg, MB, Canada

**Roy F. Riascos** Department of Diagnostic and Interventional Imaging, University of Texas Health Science Center at Houston, McGovern Medical School, Houston, TX, USA

**Francisco Rivas-Rodriguez** Department of Radiology, University of Michigan, Ann Arbor, MI, USA

**Andres Rodriguez** Department of Diagnostic and Interventional Imaging, Division Head of Neuroradiology, The University of Texas Health Science Center at Houston, McGovern Medical School, Houston, TX, USA

**Luigia Romano** Department of General and Emergency Radiology, "A. Cardarelli" Hospital, Naples, Italy

**Enrica Rossi** Department of Radiology, Azienda Ospedaliero Universitaria Meyer, Florence, Italy

**Katya Rozovsky** Section of Pediatric Radiology, Children's Hospital, Department of Radiology, University of Manitoba, Winnipeg, MB, Canada

**Muhayman Sadiq** Department of Diagnostic and Interventional Imaging, McGovern Medical School at UTHealth Houston, Houston, TX, USA

**Gaurav Saigal** Division of Neuroradiology and Pediatric Radiology, Department of Radiology, University of Miami Miller School of Medicine, Miami, FL, USA

**Mariano Scaglione** Department of Medical, Surgical and Experimental Sciences, University of Medicine and Surgery, Sassari, Italy

Department of Radiology, James Cook University Hospital, Middlesbrough, UK

**Barbara Seccia** Department of Neuroscience, Imaging and Clinical Sciences, G. d'Annunzio University of Chieti, Chieti, Italy

**Vinil Shah** Department of Radiology and Biomedical Imaging, UCSF and Zuckerberg San Francisco General Hospital and Trauma Center, San Francisco, CA, USA

**Gali Shapira-Zaltsberg** Department of Medical Imaging, CHEO, University of Ottawa, Ottawa, ON, Canada

**Adnan Sheikh** Department of Radiology, Vancouver General Hospital/University of British Columbia, Vancouver, BC, Canada

**Donghoon Shin** Department of Radiology, Mass General Brigham, Boston, MA, USA

**Manohar M. Shroff** Neuroradiology and Image Guided Therapy, Diagnostic Imaging, The Hospital for Sick Children, and University of Toronto, Toronto, ON, Canada

**Scott D. Steenburg** Department of Radiology and Imaging Sciences, Indiana University School of Medicine, Indianapolis, IN, USA

**R**

Radial head, 597–600, 602–606, 608, 609  
 Radiation proctitis, 565  
 Radiocarpal articulation, 619  
 Radiographs, 385  
 Radiography, 653, 923  
   deep lateral femoral sulcus, 653–654  
   lipohearthrosis, 653  
   patella alta/baja, 654–656  
   Pellegrini-Stieda disease, 654–655  
   reverse Segond fracture, 654–655  
   Segond fracture, 654–655  
 Radiologic classification system (RCS), 378  
 Radiology, 991  
 Radius-lunate-capitate axis, 624  
 RADPEER system, 964  
 Raised dissection flaps, 155  
 Recreational marijuana, 147  
 Rectus sheath hematomas, 503, 507, 515  
 Recurrent pyogenic cholangitis (RPC), 418–420  
 Regan-Morrey classification, 605  
 Renal abscess, 454–455, 812, 817  
 Renal calyceal rupture, 452  
 Renal dialysis, 849  
 Renal function, 940  
 Renal hematoma, 457–459  
 Renal hemorrhage, 831, 833  
 Renal infarct, 915  
 Renal infarction, 457  
 Renal injury, 820  
 Renal obstruction nephrostomy, 831–833  
 Renal scintigraphy, 973  
 Renal trauma  
   contrast-enhanced computed tomography, 366  
   epidemiology, 366  
   follow-up imaging, 367  
   ultrasound, 367  
 Renal vein thrombosis, 979–981  
 Respiratory motion, 257–259  
 Respiratory syncytial virus, 288  
 Retained products of conception (RPOC), 468–469  
 Reticuloendothelial system, 423  
 Retrograde jejunojejunal intussusception, 532  
 Retroperitoneal fibrosis (RPF), 495, 496  
 Retroperitoneal hemorrhage, 916  
 Retroperitoneal organs, 819  
 Retropharyngeal abscess (RPA), 179, 180, 724  
 Retropharyngeal space (RPS), 180  
 Reverse Bennett fracture-dislocation, 624  
 Reverse halo sign, 292  
 Reverse Segond fracture, 654–655  
 Reversible cerebral vasoconstriction syndrome (RCVS), 140  
 Rhabdomyosarcoma (RMS), 732  
 Rhinosinusitis, 723  
 Rhomboid fossa, 576  
 Rib fracture, 235, 236, 254, 263–266  
 Rib injuries, 235  
 Ribs, 894, 933  
 Right hepatic venous thrombus, 976  
 Rigler's triad, 908  
 Rockwood-Altman classification, 581  
 Rolando fracture, 624  
 Roux-en-Y gastric bypass (RYGB), 46, 520–522, 524–526, 536  
   anastomotic stricture/ulcer, 522  
   hemorrhage, 521  
   hernia, 524, 526

intussusception, 526  
 leak, 521  
   small bowel obstruction (SBO), 524  
 Roux limb obstruction, 526  
 Ruedi-Allgower classification, 676, 679  
 Ruptured abdominal aortic aneurysm (RAAA)  
   clinical features, 22  
   CT angiography (CTA), 22  
   epidemiology, 22  
   open surgical repair (OSR), 24  
   surgical emergency, 22  
   ultrasound, 22  
 Ruptured aneurysm, 490  
 Ruptured ovarian cyst, 471–476  
 Rutherford classification, 31

**S**

Sacral fracture  
   AOSpine classification, 639  
   Denis classification, 637  
   diagnosis, 633  
   Isler classification, 638  
   modified Roy-Camille classification, 638  
 Sacral insufficiency fractures, 930  
 Sacrum, 632, 633, 636, 639  
 Safety net' algorithms, 15  
 SAH, *see* Traumatic subarachnoid hemorrhage (SAH)  
 Salivary gland source, 175–176  
*Salmonella*, 778, 899  
 Sanders classification, 680, 683  
 Sarcoma, 807  
 Scaphoid fractures, 621–623, 929  
 Scapholunate joint, 623  
 Scapholunate ligamentous injury, 619  
 Scapula, 576–578, 581–588, 592  
 SCFE, 765–768  
 Schatzker classification, 657, 661  
 Schatzker type I fracture, 662  
 Schatzker type II fracture, 662  
 Schatzker type III fracture, 658, 663  
 Schwannoma, 211, 212  
 Schwannomatosis, 211  
 Scrotal injury, 393  
 SDH, *see* Subdural hematomas (SDH)  
 Seat belt sign, 361  
 Secondary adrenal insufficiency, 915  
 Secondary stabilization, 652  
 Second branchial cleft cyst, 181  
 Segmental arterial mediolysis (SAM), 486, 497–500  
 Segmental rib fractures, 237  
 Segond fracture, 654–655  
 Seldinger technique, 43, 49, 827  
 Selective angiographic embolization (SAE), 345, 347, 348  
 Self-supervised learning, 13  
 Semi-autonomous AI, 18  
 Sensorineural hearing loss, 86  
 Sensorineural hearing loss (SNHL), 82  
 Septal thickening, 896  
 Septic arthritis, 699–700, 779, 782–787  
   clinical features, 783  
   diagnostic investigations, 783, 785  
   epidemiology, 783  
 Septic facet joint arthritis, 887–889  
 Septic joint, 831–834  
 Septic pulmonary emboli, 289

- Serosal tumors, 561  
 Severe acute respiratory syndrome (SARS) virus, 293  
 Severe coagulopathy, 405  
 Severe infantile asphyxia, 716  
 Shared sheath rupture, 273, 274  
 Shattered kidney, 370  
 Shotgun injuries, 388  
 Shoulder trauma  
   acromioclavicular joint separations, 580–582  
   clavicle fractures, 580–583  
   computerized tomography, 578  
   glenohumeral joint dislocations, 583–590  
   magnetic resonance imaging, 578–579  
   proximal humerus fractures, 585–591  
   radiography, 577–578  
   scapula fractures, 581–588  
   scapulothoracic dissociation/floating shoulder, 586–592  
   shoulder soft tissue injuries, 588–593  
   sternoclavicular joint injuries, 579–580  
   ultrasonography, 578  
 Silicone adenopathy, 307  
 Sinonasal source, 172–174  
 Sjogren's syndrome, 217  
 Skin and soft tissue infections  
   clinical features, 788  
   diagnostic evaluation, 788–791  
   epidemiology, 787, 788  
 Skin folds, 227, 228  
 Skull base fractures  
   anterior cranial fossa (*see* Anterior cranial fossa)  
   clinical presentation, 76  
   imaging modalities, 76  
   incidence, 75  
 Skull fractures, 709  
 Sleeve gastrectomy (SG), 520, 527, 528, 536  
   gastric stricturing or stenosis, 528  
   gastrointestinal leak, 528  
   hemorrhage, 528  
 Slipped LAGB, 536  
 Small bowel obstruction (SBO), 440, 520, 524, 525, 536, 907  
   clinical features, 439  
   complications, 439–440  
   diagnostic investigations, 439–440  
   epidemiology, 439  
   imaging findings, 439–441  
   modality, 439  
   technique, 439  
 Small bowel radiation damage, 565  
 Smith fracture, 929  
 Society for Vascular Surgery (SVS), 255  
 Society of Interventional Radiology, 27  
 Soft tissue abscess, 779, 788–790  
 Soft tissue injuries, 606–611, 627, 628, 685–687, 997  
 Solid-organ injuries, 399  
 Solid visceral injuries, 389  
   aorta and vascular, 394  
   bowel and mesentery, 392  
   diaphragm, 394  
   kidneys and ureters, 391  
   liver and spleen, 389  
   pancreas, 390  
 Spaces, 170, 171, 173–175, 177–180, 182, 183  
 Spectral Doppler tracings, 304  
 Sphenoid sinusitis, 724  
 Sphenoparietal sinus injury, 85  
 Spinal astrocytomas, 749  
 Spinal canal contents, 194  
 Spinal cord compression, 206  
 Spinal cord infarction, 213, 883–885  
 Spinal cord injury (SCI), 186–189, 194, 199  
 Spinal cord injury without radiographic abnormality (SCIWORA), 743  
 Spinal dural arteriovenous fistula, 885  
 Spinal epidural abscess (SEA), 886  
 Spinal instability neoplastic score (SINS), 878, 882, 883, 890  
 Spinal stability, 188, 189  
 Spinal subdural abscess, 886–888  
 Spinal trauma, 186  
   conventional MRI protocol, 187  
   MRI, 187  
 Spine imaging, 6  
 Spinopelvic dissociation, 637–639  
 Spiral fractures, 934  
 Spleen, 26  
 Splenic artery aneurysms (SAAs), 426, 427, 429, 512  
 Splenic artery calcifications, 910  
 Splenic hydatid cysts, 430  
 Splenic infarction, 343, 425, 426, 428  
 Splenic infections, 430, 432  
 Splenic injury, 820  
 Splenic lacerations, 341  
 Splenic parenchyma, 820  
 Splenic pedicle injuries, 343  
 Splenic pseudoaneurysm, 428  
 Splenic sequestration, 429, 431  
 Splenic torsion, 428, 429  
 Splenic trauma, 830  
 Splenic vascular injuries, 342, 343, 345, 346, 348–351  
 Splenic vasculature, 424  
 Splenic venous thrombosis (SVT), 427, 428, 430  
 Spondylodiscitis, 754  
 Spontaneous hemoperitoneum, 512, 561  
 Spontaneous intracranial hemorrhage  
   arteriovenous malformations in children, 712  
   in neonates, 710  
 Spontaneous pseudoaneurysm, 304  
 Spontaneous splenic rupture, 427  
 Spot sign, 136  
 Stab wound (SW), 248, 265  
 Stakeholders, 966  
*Staphylococcus aureus*, 207, 692, 696, 700, 778, 783, 787, 899  
 Starry night pattern, 419  
 ST-elevation MI (STEMI), 899  
 Stercoral colitis, 912, 913  
 Sternal fracture, 237, 238  
 Sternoclavicular dislocation, 237  
 Sternoclavicular (SC) joint injuries, 263, 579–580  
 Steroid therapy, 290  
 Stomach, 896–897  
 Stomal stenosis, 520, 530, 535, 536  
 “Stop the Bleed” education movement, 399  
 Streamlining approaches, 953  
*Streptococcus pneumoniae*, 122, 123, 723, 730, 778, 895  
*Streptococcus pyogenes*, 778, 783, 788  
 Stress management techniques, 959  
 Subarachnoid neurocysticercosis, 131  
 Subcapsular hematomas, 342, 368  
 Subcapsular renal hematoma, 459, 981  
 Subdural empyema, 862–867  
 Subdural hematomas (SDHs), 64, 68, 843, 844, 849, 854  
 Subfalcine herniation, 67, 70  
 Subperiosteal abscess, 725, 778–781, 784

- Subtle colonic injury, 386  
 Subtle DAI, 62  
 Subtle non-displaced fracture, 238  
 Subungual hematoma, 628  
 Suicide, 842, 846–847  
 Superficial neuronal layers, 12  
 Superficial soft tissue injuries, 646  
 Superimposed infection, 452  
 Superior mesenteric artery embolism, 500  
 Superior mesenteric artery (SMA), 813, 814  
 Superior mesenteric vein (SMV), 814  
 Superior peroneal retinacular avulsion fracture, 680  
 Supervised learning, 12  
 Suppurative adenopathy, 730  
 Suppurative retropharyngeal adenitis, 726  
 Supracondylar fracture, 655  
 Supracondylar humerus fractures (SCHFs), 763  
 Suprapatellar fat pad, 653  
 Surgical exploration, 373  
 Susceptibility-weighted imaging (SWI), 207  
 Suspected hepatobiliary disorders, 412  
 Swirl sign, 136  
 Symptomatic malrotation, 813  
 Synchronous injuries, 997  
 Systemic inflammatory diseases, 215  
 Systemic lupus erythematosus (SLE), 215  
 Systemic metabolic dysfunction, 717
- T**
- Takayasu arteritis, 495  
 Talus, 672, 673, 677–682, 687  
 Tangential calcium sign, 489  
*Target sign*, 813  
 Teen dating violence (TDV), 999  
 Teeth, 94, 99, 100, 103  
 Teleradiology, 953, 956, 957, 967  
 Temporal bone fractures, 80, 82, 85–88  
 Temporary abdominal closure (TAC), 399  
 Temporomandibular joint, 80  
 Tension hemothorax, 229  
 Tension pneumothorax, 228  
 Test-bolus or bolus-tracking technique, 906  
 Testicular torsion, 472–478  
 TEVAR repair, 279  
 Thoracic and lumbosacral spine
  - clinical features, 744
  - epidemiology, 744
  - focal injuries, 744
  - imaging guidelines, 744
 Thoracic aorta, 898–900  
 Thoracic aortic dissection, 272  
 Thoracic CT protocol, 249  
 Thoracic emergencies, 794  
 Thoracic endovascular aortic repair (TEVAR), 26, 255, 272, 279  
 Thoracic injuries, 996–999  
 Thoracic spine, 237, 922  
 Thoracoabdominal aorta, 900  
 Thoracodorsal artery, 266  
 Thoracolumbar spine
  - compression fractures, 924–926
  - degenerative spine, 926
  - hyperflexion injuries, 925
  - ligamentous injuries, 925
  - transverse process fractures, 925
 Thoracostomy tubes, 227  
 Thrombolysis
  - acute limb ischemia (ALI), 29
  - deep vein thrombosis (DVT), 32, 34
  - pulmonary embolism (PE), 30, 32
 Thrombosis, 979  
 T2 hyperintense foci, 218  
 Thyroglossal duct cyst (TGDC), 182–183
  - clinical features, 728
  - diagnostic investigations, 729
  - epidemiology, 728
 Tibia, 652–655, 657–659, 661, 662, 665, 667, 668  
 Tibiofemoral dislocation, 660–662, 665  
 Tile classification, 641–643  
 Time-of-flight MR angiography (TOF-MRA), 110, 112  
 Toddler fractures (TFs), 770–771  
 Tonsillar lymphoma, 735  
 Tonsillitis/pharyngitis, 724, 726  
 Torso trauma, 992  
 Torticollis, 727  
 Toxic-metabolic encephalopathies, 717  
 Toxoplasmosis, 131  
 Trampoline fractures (TRFs), 770–771  
 Trans-arterial chemoembolization (TACE), 421  
 Transdiaphragmatic injury, 393  
 Transesophageal echocardiography (TEE), 270  
 Transformer-based models, 13  
 Transformers, 13  
 Transitional ankle fractures (TAFS), 771–772  
 Transjugular portosystemic shunt (TIPS) insertion, 37  
 Transmesocolic hernia, 529  
 Transmural inflammation, 816  
 Transtentorial herniation, 67, 71  
 Transthoracic echocardiography (TTE), 26  
 Transvaginal ultrasonography, 465  
 Trapdoor fractures, 103  
 Trapezoid, 619  
 Trauma, 576–579, 581, 583, 585, 586, 588, 590, 596–598, 600, 606, 607, 610, 632, 633, 635–637, 645–648, 672, 674, 675, 681, 683
  - clinical features, 734
  - diagnostic investigations, 734
  - epidemiology, 734
 Trauma Audit and Research Network (TARN) database, 248  
 Trauma CT protocol, 249  
 Traumatic abdominal emergencies, 817
  - contrast enhanced-CT (CECT), 819–821
  - contrast-enhanced ultrasound (CEUS), 820
  - CT, 819
  - E-FAST, 819
  - US, 819
 Traumatic abnormalities, 742  
 Traumatic and iatrogenic disease
  - hematoma, 302–303
  - localization wires, 305
  - penetrating injury, 305
  - post-operative seroma, 303–304
  - pseudoaneurysm, 303–305
 Traumatic brain injury (TBI)
  - advanced imaging techniques, 70–72
  - brain parenchymal injuries, 57–62
  - dementia, 849
  - diffusion-tensor imaging, 72
  - disposition and outcome, 849
  - elder abuse, 849
  - epidemiology, 842

- extra-axial hemorrhage, 62–67
  - falls, 844–847
  - functional MRI (fMRI), 71
  - geriatric patients, 842
  - intracranial vascular injury, 68–70
  - MRI evaluation, 72, 844, 845
  - MVCs, 845–848
  - perfusion imaging, 71
  - radiologic assessment, 843, 844
  - risk factors, 842, 843
  - seizures, 849
  - suicide, 846–847
  - Traumatic diaphragmatic rupture, 241
  - Traumatic emergencies
    - central cord syndrome, 879–880
    - cervical extension-distraction injuries, 880
    - epidemiology, 878
    - imaging assessment, 879
    - odontoid fractures, 880–881
    - risk factors, 878–879
  - Traumatic injuries, 229, 241
    - kidneys, 28
    - liver, 27
    - pelvis, 29
    - pericardial injury, 239
    - spleen, 26
  - Traumatic pseudoaneurysm, 72
  - Traumatic rib injuries, 235
  - Traumatic spinal emergencies, 740
  - Traumatic spinal injury
    - craniocervical junction and cervical spine (*see* Craniocervical junction and cervical spine)
    - thoracic and lumbosacral spine (*see* Thoracic and lumbosacral spine)
    - traumatic abnormalities, 743
  - Traumatic subarachnoid hemorrhage (SAH), 66, 69
  - Traumatic vascular injury, 248
  - Triplane fractures (TrPFs), 771
  - Triquetral fractures, 622
  - Trocar technique, 43
  - Tubal ectopic pregnancy, 466–468
  - Tuberculosis (TB), 288
  - Tuberculous meningitis*, 125, 126
  - Tumor superinfection, 566
  - Turnaround times (TATs), 965
  - Twisting injuries, 675–676
  - Type IA endoleak, 494
  - Type IB endoleak, 494
  - Type I occipital condyle fracture, 90
  - Type II occipital condyle fracture, 90
  - Type III occipital condyle fracture, 87, 90
  - Typhlitis, 563
- U**
- Ulcer-like projection (ULP), 275, 276, 497, 498
  - Uncal herniation, 67, 71
  - Upper central midface (UCM), 95, 96, 99
  - Upper extremity injuries
    - distal radius/Colles *vs.* Smith fracture, 929
    - elbow fractures and dislocation, 927–928
    - scaphoid fractures, 929
    - shoulder/humerus, 926–928
  - Upper extremity nerve injuries, 607
  - Upper gastrointestinal (UGI), 520–523, 525, 527–533, 535
  - Ureteral injuries, 391
  - Ureteral trauma, 391
    - AAST Ureteral Injury Scale, 374
    - epidemiology, 374
  - Urgent drainage, 42
  - Urinary bladder (UB) injury, 374, 375
    - AAST UB Injury Scale, 377
    - diagnostic investigations, 375
    - epidemiology, 375
    - management, 379
    - radiologic classification system, 378
  - Urinary outflow obstruction, 982–983
  - Urinary tract obstruction (UTO)
    - clinical features, 48
    - complications, 51, 52
    - epidemiology, 48
    - percutaneous nephrostomy (PCN), 48
    - precautious antegrade *vs.* retrograde intervention, 50
    - radiological findings, 48
    - techniques, 48
  - Urine leakage, 820
  - Urinoma, 982
  - Urolithiasis, 451, 554
- V**
- Varicella zoster myelitis, 218
  - Vascular access, 832–835
  - Vascular anastomoses, 973
  - Vascular disease
    - clinical features, 755
    - diagnostic investigations, 755
    - epidemiology, 755
  - Vascular emergencies, 883–885
    - AD (*see* Aortic dissection (AD))
    - GIB (*see* Gastrointestinal bleeding (GIB))
    - hemoptysis (*see* Hemoptysis)
    - PPH (*see* Postpartum hemorrhage (PPH))
    - RAAA (*see* Ruptured abdominal aortic aneurysm (RAAA))
    - thrombolysis (*see* Thrombolysis)
    - trauma (*see* Traumatic injuries)
  - Vascular health, 941
  - Vascular injury, 69, 85, 248, 369, 609, 611
  - Vascular malformations
    - arteriovenous fistula (AVFs), 143
    - arteriovenous malformations (AVMs), 143
    - cavernous malformations (CMs), 143, 145
  - Vascular neoplasms, 213
  - Vascular occlusion, 494
  - Vasculitis, 140, 142, 213, 281, 486, 494, 497–500
  - Vasospasm, 160, 728
  - Vein of galen aneurysmal malformations (VGAM), 719
  - Venous and osseous hemorrhage, 29
  - Venous epidural hematoma, 67, 85
  - Venous thoracic outlet/Paget Schroetter syndrome, 33
  - Venous thrombosis, 145, 146
  - Ventriculitis, 123
  - Vertebral bodies, 747
  - Vertebral metastases, 210
  - Vertical shear (VS), 638, 640–642
  - Vertigo, 866
  - Vessel wall, mild irregularities, 155
  - Viral rhinosinusitis (VRS), 722
  - Visceral trauma, 26
  - Vision-language models (VLMs), 14
  - vRad, 16