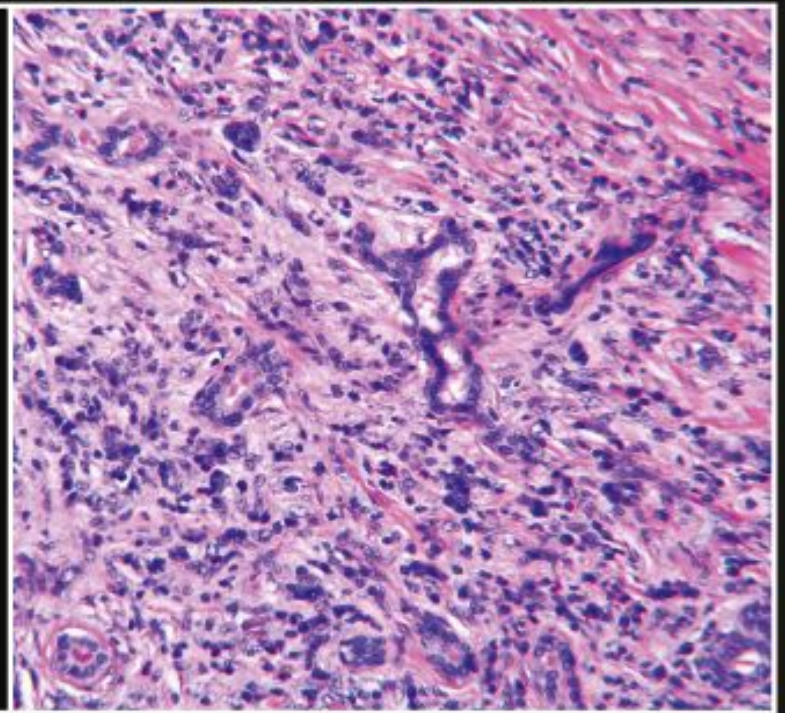
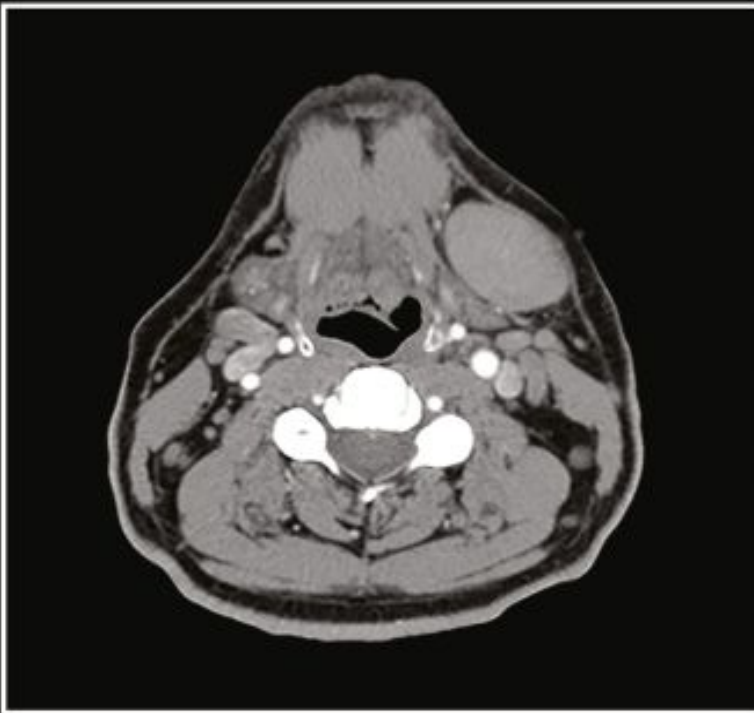

THIRD EDITION

SALIVARY GLAND PATHOLOGY

DIAGNOSIS AND MANAGEMENT

EDITED BY ERIC R. CARLSON AND ROBERT A. ORD



WILEY Blackwell

Table of Contents

[Cover](#)

[Title Page](#)

[Copyright Page](#)

[Contributors](#)

[Foreword First Edition](#)

[Foreword Second Edition](#)

[Foreword Third Edition](#)

[Preface First Edition](#)

[Preface Second Edition](#)

[Preface Third Edition](#)

[Acknowledgments](#)

[About the Companion Website](#)

[Chapter 1: Surgical Anatomy, Embryology, and Physiology of the Salivary Glands](#)

[Introduction](#)

[Parotid Gland](#)

[Submandibular Gland](#)

[Sublingual Gland](#)

[Minor Salivary Glands](#)

[Tubarial Salivary Glands](#)

[Histology of the Salivary Glands](#)

[Control of Salivation](#)

[Summary](#)

[Case Presentation - *Wait, What?*](#)

[References](#)

Chapter 2: Diagnostic Imaging of Salivary Gland Pathology

Introduction

Imaging Modalities

Diagnostic Imaging Anatomy

Pathology of the Salivary Glands

Summary

Case Presentation - *Duplicity*

References

Chapter 3: Infections of the Salivary Glands

Introduction

General Considerations

Bacterial Salivary Gland Infections

Viral Salivary Gland Infections

Bacterial Sialadenitis in Pregnancy

Autoimmune Sialadenitis and IgG4-Related Disease

Summary

Case Presentation - *Gadzooks*

References

Chapter 4: Cysts and Cyst-Like Lesions of the Salivary Glands

Introduction

Mucous Escape Reaction

Mucous Retention Cyst

Parotid Cysts Associated with Human

Immunodeficiency Virus Infection

Branchial Cleft Cysts

Parotid Neoplasms Masquerading as Cysts

Summary

[Case Presentation - *Down Yonder*](#)

[References](#)

[Chapter 5: Sialolithiasis](#)

[Introduction](#)

[Pathophysiology of Sialolithiasis](#)

[Clinical Features of Sialolithiasis](#)

[Differential Diagnosis and Diagnosis of Sialolithiasis](#)

[Treatment of Sialolithiasis](#)

[Sialolithiasis of the Sublingual Gland and Minor Salivary Glands](#)

[The Relationship of Salivary Lithiasis to Nephrolithiasis, Cholelithiasis, Primary Hyperparathyroidism, and Gout](#)

[Summary](#)

[Case Presentation - *Stoneorama*](#)

[References](#)

[Chapter 6: Systemic Diseases Affecting the Salivary Glands](#)

[Introduction](#)

[Sjögren Syndrome](#)

[Sarcoidosis](#)

[Sialosis](#)

[IgG4-Related Disease](#)

[Summary](#)

[Case Presentation - *Esoterica*](#)

[References](#)

[Chapter 7: Salivary Gland Pathology in Children and Adolescents](#)

[Introduction](#)

[Nonneoplastic Salivary Gland Lesions](#)

[Neoplastic Salivary Gland Disease](#)

[Summary](#)

[Case Presentation - *Size Matters*](#)

[References](#)

[Chapter 8: Classification, Grading, and Staging of Salivary Gland Tumors](#)

[Introduction](#)

[Classification Systems for Salivary Gland Neoplasms](#)

[Grading and Staging of Salivary Gland Tumors](#)

[TNM and Staging of Salivary Gland Tumors](#)

[Summary](#)

[Case Presentation - *Reclassified*](#)

[References](#)

[Chapter 9: The Molecular Biology of Benign and Malignant Salivary Gland Tumors](#)

[Introduction: The Puzzle and the Promise](#)

[Salivary Gland Tumor Cell Biology](#)

[Molecular Biology of Salivary Gland Neoplasms](#)

[Summary and Clinical Applications](#)

[Summary](#)

[References](#)

[Chapter 10: Tumors of the Parotid Gland](#)

[Introduction](#)

[Etiology and Epidemiology](#)

[Diagnosis](#)

[Surgical Management](#)

[Summary](#)

[Case Presentation - *How Did This All Start?*](#)

[References](#)

[Chapter 11: Tumors of the Submandibular and Sublingual Glands](#)

[Introduction](#)

[Epidemiology and Etiology](#)

[Diagnosis](#)

[Management](#)

[Summary](#)

[Case Presentation - *But I Took the Road Less Traveled*](#)

[References](#)

[Chapter 12: Tumors of the Minor Salivary Glands](#)

[Introduction](#)

[Etiology of Minor Salivary Gland Tumors](#)

[Diagnosis of Minor Salivary Gland Tumors](#)

[Treatment of Minor Salivary Gland Tumors](#)

[Summary](#)

[Case Presentation - *Two Peas in a Pod*](#)

[References](#)

[Chapter 13: Radiation Therapy for Salivary Gland Malignancies](#)

[Introduction](#)

[Low-Risk Salivary Gland Malignancies](#)

[Moderate-Risk Salivary Gland Malignancies](#)

[High-Risk Salivary Gland Malignancies](#)

[Evolution of Radiation Techniques in Salivary Gland Malignancies](#)

[Complications of Radiation Therapy in Salivary Gland Malignancies](#)

[Radiation Technique for Low- and Moderate-Risk Salivary Gland Tumors](#)

[Radiation Technique for High-Risk Salivary Gland Tumors](#)

[Advanced Radiation Therapy Techniques](#)

[Summary](#)

[References](#)

[Chapter 14: Systemic Therapy for Salivary Gland Cancer](#)

[Introduction](#)

[Epidemiology and Risk Factors](#)

[Molecular Biology of Salivary Gland Tumors](#)

[Clinical Presentation](#)

[Treatment](#)

[Summary](#)

[References](#)

[Chapter 15: Non-salivary Tumors of the Salivary Glands](#)

[Introduction](#)

[Mesenchymal Tumors](#)

[Epithelial Non-salivary Tumors](#)

[Tumors of Salivary Gland Lymph Nodes](#)

[Miscellaneous](#)

[Summary](#)

[Case Presentation - *From One Salivary Gland to Another*](#)

[References](#)

[Chapter 16: Trauma and Injuries to the Salivary Glands](#)

[Introduction](#)

[Penetrating Injuries](#)

[Radiation Injury](#)

[Barotrauma](#)

[Summary \(Figures 16.22 and 16.23\)](#)

[References](#)

[Chapter 17: Miscellaneous Pathologic Processes of the Salivary Glands](#)

[Introduction](#)

[Hereditary and Congenital Conditions](#)

[Saliva](#)

[Ischemic/Degenerative Changes](#)

[Küttner Tumor](#)

[Salivary Gland Biopsy for Systemic Disease](#)

[Summary](#)

[Case Presentation - *The Great Pretender*](#)

[References](#)

[Chapter 18: Complications of Salivary Gland Surgery](#)

[Introduction](#)

[General Considerations](#)

[Complications of Parotid Gland Surgery](#)

[Parotid Duct Leakage](#)

[Complications of Submandibular and Sublingual Gland Surgery](#)

[Complications Associated with Removal of Minor Salivary Gland Mucocele](#)

[Summary](#)

[Case Presentation - *Get It Right the First Time. That's the Main Thing*](#)

[References](#)

[Chapter 19: Innovations in Salivary Gland Surgery](#)

[Minimally Invasive Parotid Gland Surgery](#)

[Minimally Invasive Sublingual Gland Surgery](#)

[Minimally Invasive Salivary Gland Surgery with Sialendoscopy](#)

[Summary](#)

[References](#)

[Index](#)

[End User License Agreement](#)

List of Tables

Chapter 2

[Table 2.1. CT density in Hounsfield units \(H\).](#)

[Table 2.2. Tissue characteristics on T1 and T2 MRI.^a](#)

[Table 2.3. Standard uptake value \(SUV\) of salivary glands.](#)

Chapter 3

[Table 3.1. Classification of salivary gland inflammation/infection.](#)

[Table 3.2. Risk factors associated with salivary gland inflammation/infection...](#)

Chapter 4

[Table 4.1. Cysts and cyst-like lesions of the salivary glands - nomenclature ...](#)

[Table 4.2. Classification and examples of cystic lesions of the parotid gland...](#)

Chapter 5

[Table 5.1. Composition of normal adult saliva.](#)

Chapter 6

[Table 6.1. Frequency of extraglandular findings in primary Sjögren syndrome.](#)

[Table 6.2. Clinical involvement by sarcoidosis.](#)

[Table 6.3. Classification of sialosis.](#)

Chapter 7

[Table 7.1. Inflammatory and infectious diseases of the salivary glands in chi...](#)

[Table 7.2. Comparison of the reported incidence of epithelial salivary gland ...](#)

Chapter 8

[Table 8.1. 2017 WHO classification of salivary gland tumors.](#)

[Table 8.2. Grading of malignant salivary gland tumors.](#)

[Table 8.3. Staging of malignant salivary gland tumors.](#)

Chapter 11

[Table 11.1. Sublingual gland tumors 1990-2020 \(Experience of Drs. Carlson and...](#)

Chapter 12

[Table 12.1. Incidence of minor salivary gland tumors.](#)

[Table 12.2. Incidence of benign and malignant minor salivary gland tumors at ...](#)

[Table 12.3. Management of the anatomic barriers in minor salivary_gland tumor...](#)

Chapter 14

[Table 14.1. Chemotherapy in the treatment of metastatic or recurrent salivary...](#)

[Table 14.2. Targeted therapy in the treatment of metastatic or recurrent sali...](#)

Chapter 18

[Table 18.1. House-Brackmann facial paralysis scale.](#)

[Table 18.2. Dosage per type A botulinum formulation for the treatment of Frey...](#)

List of Illustrations

Chapter 1

[Figure 1.1. A lateral view of the skull showing some of the bony features re...](#)

[Figure 1.2. The parotid gland and associated structures.](#)

[Figure 1.3. The mandibulo-stylohyoid ligament.](#)

[Figure 1.4. Anatomical landmarks of the extratemporal facial nerve.](#)

[Figure 1.5. Clinical photograph of dissected facial nerve following superfic...](#)

[Figure 1.6. The branching patterns of the facial nerve.](#)

[Figure 1.7. The facial nerve and its relationship to the retromandibular vei...](#)

[Figure 1.8. The surface markings for the location of the parotid duct.](#)

[Figure 1.9. The parasympathetic innervations of the salivary glands. The par...](#)

[Figure 1.10. The relationship of the superficial and deep lobes of the subma...](#)

[Figure 1.11 Superficial dissection of the left submandibular gland. The inve...](#)

[Figure 1.12. Deep dissection of the left submandibular gland. With the subma...](#)

[Figure 1.13. Clinical photograph showing the relationship of the lingual ner...](#)

[Figure 1.14. Diagram showing the histology of the major components of the sa...](#)

[Figure 1.15. Axial \(a\) and coronal \(b\) CT angiogram of the neck demonstratin...](#)

Chapter 2

[Figure 2.1. Axial CT of the neck in soft-tissue window without contrast demo...](#)

[Figure 2.2. Axial CT of the neck in soft-tissue window with IV contrast demo...](#)

[Figure 2.3. Axial CT of the skull base reconstructed in a sharp algorithm an...](#)

[Figure 2.4. Axial CT of the neck at the thoracic inlet in lung windows demon...](#)

[Figure 2.5. Coronal CT reformation of the neck in soft-tissue window at the ...](#)

[Figure 2.6. Sagittal CT reformation of the neck in soft-tissue window at the...](#)

[Figure 2.7. CT angiogram \(CTA\) of the neck at the level of the parotid gland...](#)

[Figure 2.8. Axial MRI T1 weighted image at level of the skull base and brain...](#)

[Figure 2.9. Axial MRI FSE T2 weighted image demonstrating the high signal of...](#)

[Figure 2.10. Axial MRI GRE image.](#)

[Figure 2.11. Axial MRI STIR image at the skull base demonstrating the high s...](#)

[Figure 2.12. Sagittal MRI STIR image at the level of the parotid gland demon...](#)

[Figure 2.13. Axial \(a\) and coronal \(b\) MRI T1 post-contrast fat saturated im...](#)

[Figure 2.14. Axial MRI FLAIR image at the skull base demonstrating CSF flow-...](#)

[Figure 2.15. Axial MRI DWI image at the skull base demonstrating susceptibil...](#)

[Figure 2.16. Ultrasound of the submandibular gland \(black arrow\) adjacent to...](#)

[Figure 2.17. Ultrasound of the parotid gland demonstrating a normal intrapar...](#)

[Figure 2.18. Ultrasound of the parotid gland in longitudinal orientation dem...](#)

[Figure 2.19. Ultrasound of the parotid gland in longitudinal orientation dem...](#)

[Figure 2.20. Submandibular sialogram \(a\). Note the continuity defect that re...](#)

[Figure 2.21. Parotid sialogram. Note the numerous areas of duct dilatation a...](#)

[Figure 2.22. Submandibular sialogram: Note the “soft” noncalcified stone fil...](#)

[Figure 2.23. Parotid sialogram. Note the punctate filling areas without duct...](#)

[Figure 2.24. Parotid sialo-CT. Although the main duct is opacified, it is im...](#)

[Figure 2.25. Contrast-enhanced axial CT exam through the parotid gland prior...](#)

[Figure 2.26. CT \(a\), PET \(b\), and fused PET/CT \(c\) images in axial plane and...](#)

[Figure 2.27. PET image \(a\), corresponding CT image \(b\) and a fused PET/CT im...](#)

[Figure 2.28. CT \(a\) and PET \(b\) images in axial plane demonstrating normal p...](#)

[Figure 2.29. CT \(a\) and PET \(b\) images in axial plane demonstrating normal s...](#)

[Figure 2.30. Axial CT of the neck demonstrates the intermediate to low densi...](#)

[Figure 2.31. Reformatted coronal CT of the neck at the level of the parotid ...](#)

[Figure 2.32. Reformatted sagittal CT of the neck at the level of the parotid...](#)

[Figure 2.33. Axial T1 MRI image at the level of the parotid gland demonstrat...](#)

[Figure 2.34. Coronal STIR MRI image at the level of the parotid gland demons...](#)

[Figure 2.35. Sagittal fat suppressed T1 MRI image of the parotid gland demon...](#)

[Figure 2.36. Axial CT scan \(a\) and corresponding PET scan \(b\) at the level o...](#)

[Figure 2.37. Axial CT at the level of the submandibular gland demonstrating...](#)

[Figure 2.38. Reformatted coronal CT at the level of the submandibular gland ...](#)

[Figure 2.39. Reformatted sagittal CT at the level of the submandibular gland...](#)

[Figure 2.40. Axial T1 MRI of the submandibular gland demonstrating slight hy...](#)

[Figure 2.41. Coronal fat saturated T2 MRI of the submandibular gland. Note t...](#)

[Figure 2.42. Sagittal T1 fat saturated MRI of the submandibular gland demons...](#)

[Figure 2.43. Axial CT \(a\) and corresponding PET \(b\) of the submandibular gla...](#)

[Figure 2.44. Axial CT of the neck at the level of the sublingual gland demon...](#)

[Figure 2.45. Axial contrast-enhanced T1 MRI of the sublingual gland demonstr...](#)

[Figure 2.46. Axial PET of the sublingual gland demonstrating the intense upt...](#)

[Figure 2.47. Axial contrast-enhanced CT of the neck at the level of the subm...](#)

[Figure 2.48. Coronal STIR MRI of the face of a different patient with a very...](#)

[Figure 2.49. Direct coronal CT displayed in bone window demonstrating smooth...](#)

[Figure 2.50. Coronal fat suppressed contrast-enhanced T1 MRI image correspon...](#)

[Figure 2.51. Coronal fat saturated T2 MRI image demonstrating a well-demarca...](#)

[Figure 2.52. Axial CT with contrast at the level of the masseter muscles dem...](#)

[Figure 2.53. Axial contrast-enhanced fat saturated T1 MRI demonstrating hete...](#)

[Figure 2.54. Reformatted coronal CT demonstrating enlargement and enhancemen...](#)

[Figure 2.55. Axial CT demonstrating a large cystic lesion in the right parot...](#)

[Figure 2.56. Reformatted coronal contrast-enhanced CT of the submandibular g...](#)

[Figure 2.57. Axial contrast-enhanced CT of the parotid gland demonstrating a...](#)

[Figure 2.58. Axial contrast-enhanced CT at the level of the submandibular gl...](#)

[Figure 2.59. Axial contrast-enhanced CT \(a\) of the head with a cystic mass a...](#)

[Figure 2.60. Axial contrast-enhanced CT of the maxillofacial soft tissues wi...](#)

[Figure 2.61. Axial contrast-enhanced CT of the parotid gland with a heteroge...](#)

[Figure 2.62. Axial PET/CT fused image demonstrating intense FDG uptake in a ...](#)

[Figure 2.63. Axial contrast-enhanced CT of a heterogenous parotid mass at th...](#)

[Figure 2.64. Axial contrast-enhanced CT demonstrating an ill-defined mass di...](#)

[Figure 2.65. Axial contrast-enhanced CT demonstrating large bulky cervical l...](#)

[Figure 2.66. Reformatted coronal contrast-enhanced CT demonstrating an ill-d...](#)

[Figure 2.67. Coronal contrast-enhanced MRI of the skull base demonstrating a...](#)

[Figure 2.68. Axial CT in bone window demonstrating a mass eroding through th...](#)

[Figure 2.69. Coronal CT corresponding to the case illustrated in Figure 2.68...](#)

[Figure 2.70. Reformatted contrast-enhanced coronal CT with a mass in the rig...](#)

[Figure 2.71. Reformatted sagittal contrast-enhanced CT corresponding to the ...](#)

[Figure 2.72. Axial contrasted-enhanced CT of the head with a fat density mas...](#)

[Figure 2.73. Axial contrast-enhanced CT through the submandibular gland with...](#)

[Figure 2.74. Coronal T1 contrast-enhanced MRI demonstrating a mass in the le...](#)

[Figure 2.75. Coronal T2 MRI corresponding to the case illustrated in Figure ...](#)

[Figure 2.76. Axial CT at the skull base displayed in bone window showing dil...](#)

[Figure 2.77. Coronal T1 contrast image showing a very ill-defined mass with ...](#)

[Figure 2.78. Axial T2 MRI image corresponding to the case illustrated in Fig...](#)

[Figure 2.79. Axial CT scan with contrast at the level of the parotid tail de...](#)

[Figure 2.80. Axial PET scan image corresponding to the case in Figure 2.79. ...](#)

[Figure 2.81. Fused axial PET/CT image corresponding to the case illustrated ...](#)

[Figure 2.82. Axial CT of a mass in the right parotid gland with homogenous e...](#)

[Figure 2.83. Axial PET scan corresponding to the case illustrated in Figure ...](#)

[Figure 2.84. Axial contrast-enhanced CT scan through the parotid glands demo...](#)

[Figure 2.85. The patient demonstrates obvious left facial swelling in the re...](#)

Chapter 3

[Figure 3.1. A 55-year-old woman \(a and b\) with a one-week history of pain an...](#)

[Figure 3.2. A 45-year-old man \(a\) with a six-month history of left submandib...](#)

[Figure 3.3. A 35-year-old man with a toxic megacolon \(a\) associated with Clo...](#)

[Figure 3.4. A severe case of hospital acquired parotitis related to insuffic...](#)

[Figure 3.5. A mild case of community acquired parotitis is noted by the expr...](#)

[Figure 3.6. Lacrimal probes are utilized to probe the salivary ducts. The fo...](#)

[Figure 3.7. Axial \(a\) and coronal \(b\) CT scans of a patient with a hospital ...](#)

[Figure 3.8. The algorithm for diagnosis and treatment of a unilateral or bil...](#)

[Figure 3.9. A left facial abscess in a 45-year-old man with a two-week histo...](#)

[Figure 3.10. Algorithm for the management of chronic recurrent bacterial par...](#)

[Figure 3.11. The miniature endoscope for diagnostic and interventional siale...](#)

[Figure 3.12. A 35-year-old man with a two-year history of left parotid pain ...](#)

[Figure 3.13. The CT scan \(a\) of a 73-year-old man with a one-year history of...](#)

[Figure 3.14. Algorithm for diagnosis and management of acute bacterial subma...](#)

[Figure 3.15. A 52-year-old man \(a\) with a one-year history of vague discomfo...](#)

[Figure 3.16. A 21-year-old woman \(a\) with a two-week history of left submand...](#)

[Figure 3.17. A 9-year-old girl with a left parotid swelling with overlying e...](#)

[Figure 3.18. Axial \(a\) and coronal \(b\) CT images demonstrating contrast enha...](#)

[Figure 3.19. A 6-year-old African female with AIDS showing involvement of th...](#)

[Figure 3.20. A 21-year-old woman \(a and b\) with a three-week history of left...](#)

[Figure 3.21. A 71-year-old man \(a\) demonstrated significant left facial swel...](#)

Chapter 4

[Figure 4.1. The typical appearance of a ranula of the floor of mouth. The ch...](#)

[Figure 4.2. This ranula has resulted in significant pain experienced by the ...](#)

[Figure 4.3. The classic appearance of a mucocele of the lower lip. Similar t...](#)

[Figure 4.4. A ranula of the left floor of mouth. While the lesion is clearly...](#)

[Figure 4.5. A ranula of the right floor of mouth. Classic signs of elevation...](#)

[Figure 4.6. An 8-year-old girl with obvious right submandibular swelling_\(a\)...](#)

[Figure 4.7. This elderly woman shows left submandibular swelling_\(a\). Her hi...](#)

[Figure 4.8. The excision of the sublingual gland and associated ranula from ...](#)

[Figure 4.9. The specimen from the excision of the mucocele seen in Figure 4....](#)

[Figure 4.10. The patient seen in Figure 4.7 underwent excision of her left s...](#)

[Figure 4.11. A 48-year-old man with a swelling of the right submandibular re...](#)

[Figure 4.12. A cyst of Blandin and Nuhn of the ventral surface of the tongue...](#)

[Figure 4.13. A 71-year-old man was referred with a six-month history of a pr...](#)

[Figure 4.14. A 50-year-old HIV positive male presented in 1994 with obvious ...](#)

[Figure 4.15. A 35-year-old HIV positive man presented in 2005 with a complai...](#)

[Figure 4.16. A 79-year-old man was referred with a six-month history of a ma...](#)

[Figure 4.17. This patient presented with a seven-month history of a painless...](#)

[Figure 5.1. A single sialolith noted within the right submandibular gland. I...](#)

[Figure 5.2. This panoramic radiograph close-up shows two sialoliths within t...](#)

[Figure 5.3. This lateral cephalometric radiograph shows a single stone locat...](#)

[Figure 5.4. This panoramic radiograph shows an oval sialolith of the left su...](#)

[Figure 5.5. This very large sialolith is associated with the right submandib...](#)

[Figure 5.6. This axial section of computerized tomograms shows the presence ...](#)

[Figure 5.7. A close-up of a panoramic radiograph obtained in a patient with ...](#)

[Figure 5.8. A panoramic radiograph demonstrating calcifications within the l...](#)

[Figure 5.9. This panoramic radiographic close-up shows an irregular mass ass...](#)

[Figure 5.10. Algorithm for management of submandibular sialolithiasis.](#)

[Figure 5.11. A sialolith is noted at the opening of the right Wharton's duct...](#)

[Figure 5.12. The clinical appearance of a man with pain and left submandibul...](#)

[Figure 5.13. Interventional sialendoscopic instrumentation for retrieval of ...](#)

[Figure 5.14. Algorithm for management of parotid sialolithiasis.](#)

[Figure 5.15. Management of an extraglandular parotid duct sialolith. The pan...](#)

[Figure 5.16. Axial CT scan demonstrating a parotid sialolith at the hilum wi...](#)

[Figure 5.17. A lateral oblique plain film demonstrating two sialoliths of St...](#)

[Figure 5.18. A 72-year-old man with pain and swelling of one month's duratio...](#)

[Figure 5.19. Floor of mouth swelling present in a 55-year-old woman \(a\). A d...](#)

[Figure 5.20. A 54-year-old man \(a and b\) with a long history of prandial swe...](#)

Chapter 6

[Figure 6.1. The association between the lymphoepithelial lesion, Sjögren syn...](#)

[Figure 6.2. A 36-year-old woman with a known history of Sjögren syndrome ass...](#)

[Figure 6.3. A 75-year-old woman \(a and b\) with a left parotid mass. Fine nee...](#)

[Figure 6.4. A 45-year-old woman diagnosed with Sjögren syndrome with bilater...](#)

[Figure 6.5. A 55-year-old woman \(a\) with a 10-year history of a progressivel...](#)

[Figure 6.6. A 32-year-old woman with the recent development of dry eyes and ...](#)

[Figure 6.7. An incisional parotid biopsy was performed on the patient seen i...](#)

[Figure 6.8. The histopathology of the incisional parotid biopsy of the patie...](#)

[Figure 6.9. Posterior-anterior \(a\) and lateral \(b\) chest radiographs of a pa...](#)

[Figure 6.10. Severe nasal cartilage involvement by sarcoidosis in this elder...](#)

[Figure 6.11. A 64-year-old woman with parotid swelling of two month's durati...](#)

[Figure 6.12. A 55-year-old man with bilateral submandibular gland swellings ...](#)

[Figure 6.13 Histopathology of sarcoidosis \(hematoxylin and eosin, original m...](#)

[Figure 6.14. A 32-year-old man with a chronic history of bilateral parotid s...](#)

[Figure 6.15. The fluoroscopic images of the barium swallow performed in the ...](#)

[Figure 6.16. The histopathology of the incisional parotid biopsy performed o...](#)

[Figure 6.17. The relative incidence of the most commonly observed IgG4-relat...](#)

[Figure 6.18. Axial \(a and b\), coronal \(c\), and sagittal \(d\) CT scans identif...](#)

Chapter 7

[Figure 7.1. A 14-year-old boy with a nine-month history of left parotid swel...](#)

[Figure 7.2. A seven-year-old girl \(a\) with recurrent swellings of the left s...](#)

[Figure 7.3. A baby with an acute suppurative infection of the right parotid ...](#)

[Figure 7.4. A six-year-old girl with recurrent right parotid swelling indica...](#)

[Figure 7.5. A four-month-old infant with left parotid swelling related to a ...](#)

[Figure 7.6. An 18-year-old patient with calcifications superimposed over the...](#)

[Figure 7.7. A three-year-old boy \(a\) with left parotid swelling that is soft...](#)

[Figure 7.8. An 11-month-old boy with a right facial/upper neck swelling that...](#)

[Figure 7.9. An eight-year-old girl \(a\) with left submandibular swelling that...](#)

[Figure 7.10. A nine-year-old boy \(a\) with a mass of the left hard-soft palat...](#)

[Figure 7.11. A 12-year-old girl \(a\) with a long history of a slowly growing ...](#)

[Figure 7.12. \(a\) Axial MRI showing an enhancing lesion at the posterior hard...](#)

Chapter 8

[Figure 8.1. \(a\) Pleomorphic adenoma containing tubular and solid structures ...](#)

[Figure 8.2. Warthin tumor with well-developed fibrous capsule delineating th...](#)

[Figure 8.3. Basal cell adenoma consisting of monotonous sheets of basaloid c...](#)

[Figure 8.4. Canalicular adenoma demonstrating columns of columnar cells lini...](#)

[Figure 8.5. Oncocytoma characterized by eosinophilic, granular cytoplasm, wi...](#)

[Figure 8.6. Sebaceous adenoma demonstrating numerous islands of tumor cells ...](#)

[Figure 8.7. One morphologic pattern of myoepithelioma demonstrating a monoto...](#)

[Figure 8.8. Cystadenoma characterized by tortuous cystic spaces lined by cub...](#)

[Figure 8.9. Sialadenoma papilliferum demonstrating papillary stalks composed...](#)

[Figure 8.10. Polycystic sclerosing adenoma composed of numerous tubuloacinar...](#)

[Figure 8.11. Mucoepidermoid carcinoma exhibiting large cystic spaces contain...](#)

[Figure 8.12. Intermediate-grade mucoepidermoid carcinoma with mostly solid f...](#)

[Figure 8.13. Intermediate-grade mucoepidermoid carcinoma from Figure 8.12 de...](#)

[Figure 8.14. Adenoid cystic carcinoma manifesting cribriform and tubular pat...](#)

[Figure 8.15. Adenoid cystic carcinoma demonstrating classic nerve invasion p...](#)

[Figure 8.16. Microcystic type of acinic cell carcinoma. Note the numerous sm...](#)

[Figure 8.17. Acinic cell carcinoma composed predominately of acinar cells. H...](#)

[Figure 8.18. Polymorphous adenocarcinoma comprised of both small- and interm...](#)

[Figure 8.19. Polymorphous adenocarcinoma arranged in a concentric pattern. N...](#)

[Figure 8.20. Adenocarcinoma, NOS demonstrating infiltrative growth of neopla...](#)

[Figure 8.21. Basal cell adenocarcinoma arranged much like a basal cell adeno...](#)

[Figure 8.22. Primary clear cell carcinoma arising within the parotid gland. ...](#)

[Figure 8.23. A glassy cell variant of a squamous cell carcinoma. Note the cl...](#)

[Figure 8.24. A clear cell variant of a mucoepidermoid carcinoma. H&E stainin...](#)

[Figure 8.25. The classic clear cell variant of a renal cell carcinoma metast...](#)

[Figure 8.26. Low-grade cribriform cystadenocarcinoma, also known as the low-...](#)

[Figure 8.27. Sebaceous adenocarcinoma characterized by sebaceous differentia...](#)

[Figure 8.28. Oncocytic carcinoma demonstrating the atypical cellular feature...](#)

[Figure 8.29. Salivary duct carcinoma containing comedonecrosis centrally wit...](#)

[Figure 8.30. Nodules of salivary duct carcinoma embedded within a dense conn...](#)

[Figure 8.31. Carcinoma ex-pleomorphic adenoma. The histology demonstrates ad...](#)

[Figure 8.32. Carcinoma ex-pleomorphic adenoma exhibiting nuclear abnormaliti...](#)

[Figure 8.33. Primary squamous cell carcinoma arising within a parotid gland....](#)

[Figure 8.34. Closer view of Figure 8.33 exhibiting atypical nuclear features...](#)

[Figure 8.35. Myoepithelial carcinoma of salivary gland. Note the larger clea...](#)

[Figure 8.36. Poorly differentiated carcinoma arranged in groups. Note the la...](#)

[Figure 8.37. Poorly differentiated carcinoma as in Figure 8.35. This immunos...](#)

[Figure 8.38. Small cell undifferentiated carcinoma of minor salivary gland. ...](#)

[Figure 8.39. Large cell undifferentiated carcinoma of the submandibular gland...](#)

[Figure 8.40. Lymphoepithelial carcinoma is composed of large malignant cells...](#)

[Figure 8.41. Immunohistochemistry is a great help in determining the exact t...](#)

[Figure 8.42. Mammary analogue secretory carcinoma of salivary gland. Note th...](#)

[Figure 8.43. Mammary analogue secretory carcinoma of salivary gland. Note th...](#)

[Figure 8.44. Lymphoid aggregate in mucous minor salivary gland often seen in...](#)

[Figure 8.45. Benign lymphoepithelial lesion, now designated as lymphoepithel...](#)

[Figure 8.46. Small B-cell lymphoma arising within a Warthin tumor from the p...](#)

[Figure 8.47. Hodgkin lymphoma within an intraparotid node. Note the classic ...](#)

[Figure 8.48. Benign spindle cell tumor of the parotid gland. After immunosta...](#)

[Figure 8.49. Another spindle cell tumor of the parotid gland determined to r...](#)

[Figure 8.50. \(a\) A mass of the left soft palate that conjures numerous benign...](#)

Chapter 9

[Figure 9.1. Why are salivary gland tumors so hard to study? Among the most im...](#)

[Figure 9.2. Histogenetic versus morphogenetic classification: How do salivary...](#)

[Figure 9.3. Paradigms in tumor biology: What are the cellular and molecular a...](#)

[Figure 9.4. Enhanced cellular proliferation: How does protein deregulation le...](#)

[Figure 9.5. How chromosomal alterations lead to phenotypes in salivary_gland ...](#)

[Figure 9.6. How can biomarkers aid in salivary gland tumor diagnosis? Biomark...](#)

[Figure 9.7. How can an understanding of salivary gland tumor biology lead to ...](#)

Chapter 10

[Figure 10.1. \(a\) A 67-year-old gentleman with a rapidly growing right paroti...](#)

[Figure 10.2. \(a\) A woman with a Warthin tumor in the parotid tail presenting...](#)

[Figure 10.3. \(a and b\) MR T1 and T2 weighted images of a cystic pleomorphic ...](#)

[Figure 10.4. \(a\) A 45-year-old lady with parotid pleomorphic adenoma biopsie...](#)

[Figure 10.5. \(a and b\) Patient with pleomorphic adenoma of the left parotid ...](#)

[Figure 10.6. \(a and b\) Post surgery facial views of patient with left paroti...](#)

[Figure 10.7. \(a\) Omega incision preauricular limb used to access a PA in the...](#)

[Figure 10.8. Facial nerve trunk 4 mm superior to and at the same depth as th...](#)

[Figure 10.9. \(a\) A 67-year-old African-American lady with a preauricular swe...](#)

[Figure 10.10. \(a\) MR shows large parapharyngeal PA. \(b\) Standard lip split i...](#)

[Figure 10.11. \(a\) Deep lobe parotid tumor with parapharyngeal extension pres...](#)

[Figure 10.12. \(a\) Female patient with fullness and mass in anterior right ch...](#)

[Figure 10.13. The superficial parotidectomy is completed and the superficial...](#)

[Figure 10.14. \(a-c\) MR images of large cystic benign tumor in the parotid ta...](#)

[Figure 10.15. \(a\) Two large nodules of recurrent pleomorphic adenoma exist i...](#)

[Figure 10.16. \(a\) A 20-year-old lady who previously had a "cyst" enucleated ...](#)

[Figure 10.17. \(a\) Axial CT shows large hypodense mass in the retromandibular...](#)

[Figure 10.18. \(a\) CT scan of large superficial lobe tumor in 22-year-old lad...](#)

[Figure 10.19. \(a\) Patient who had "skin-cyst" biopsied, which was histologic...](#)

[Figure 10.20. \(a\) MR of parotid tumor which radiologically was diagnosed as ...](#)

[Figure 10.21. \(a\) High-grade parotid malignancy with skin fixity and N0 neck...](#)

[Figure 10.22. \(a\) Coronal MRI view shows mass in left sublingual gland adjac...](#)

[Figure 11.1. A 64-year-old man with a painless submandibular mass.](#)

[Figure 11.2. \(a\) Elderly lady with a hard-submandibular mass \(adenoid cystic...](#)

[Figure 11.3. \(a and b\) CT scans showing submandibular mass with differing re...](#)

[Figure 11.4. \(a\) T2 coronal MR with skin marker overlying the palpable nodul...](#)

[Figure 11.5. \(a\) Adenocarcinoma of right sublingual gland. \(b\) Polymorphous ...](#)

[Figure 11.6. CT scan of large malignant sublingual gland tumor.](#)

[Figure 11.7. \(a\) The incision for submandibular gland tumor removal lies app...](#)

[Figure 11.8. Another case of submandibular pleomorphic adenoma dissected to ...](#)

[Figure 11.9. \(a\) Axial CT shows tumor projecting beyond the gland surface. \(...](#)

[Figure 11.10. \(a\) Submandibular gland attached only by its duct. The pleomor...](#)

[Figure 11.11. \(a\) A 82-year-old man with pain and swelling of the right subma...](#)

[Figure 11.12. Three-dimensional CT scan of a 15-year-old Caucasian girl who ...](#)

[Figure 11.13. Delivering sublingual gland with low-grade \(polymorphous adeno...](#)

[Figure 11.14. \(a and b\) A 48-year-old Asian female with ACC of left sublingu...](#)

[Figure 11.15. \(a\) Adenoid cystic carcinoma of sublingual gland closely appro...](#)