THIRD EDITION

SALIVARY GLAND PATHOLOGY

DIAGNOSIS AND MANAGEMENT

EDITED BY ERIC R. CARLSON AND ROBERT A. ORD



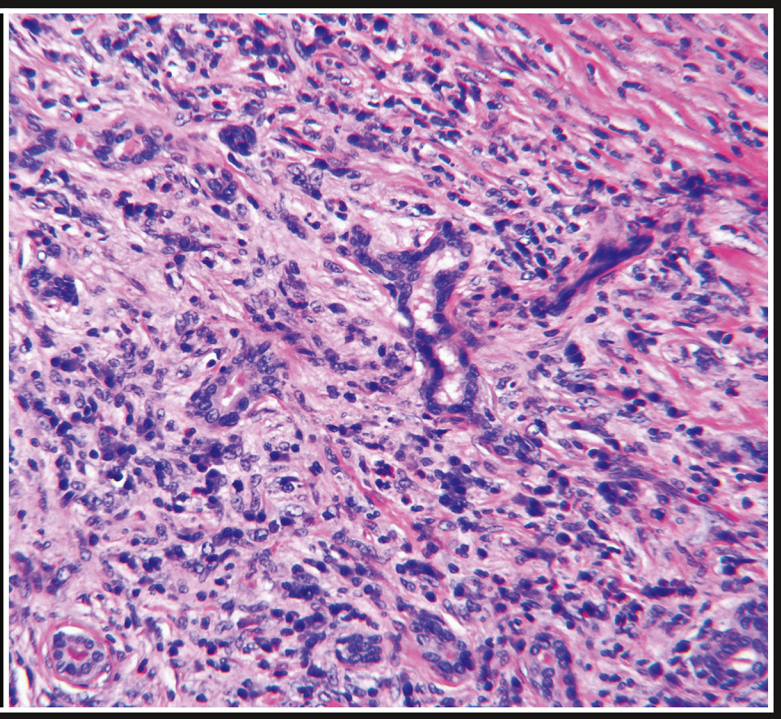

with website

WILEY Blackwell

SALIVARY GLAND PATHOLOGY

DIAGNOSIS AND MANAGEMENT

SALIVARY GLAND PATHOLOGY

DIAGNOSIS AND MANAGEMENT

Third Edition

Edited by

Eric R. Carlson
University of Tennessee Graduate School of Medicine,
University of Tennessee Cancer Institute,
Knoxville, TN, United States

Robert A. Ord
University of Maryland Medical Center,
Greenbaum Cancer Institute, Baltimore, MD,
United States

WILEY Blackwell

This edition first published 2022
© 2022 John Wiley & Sons, Inc.

Edition History
Wiley-Blackwell (1e, 2008); John Wiley & Sons, Inc. (2e, 2016)

All rights reserved. No part of this publication may be reproduced, stored in a retrieval system, or transmitted, in any form or by any means, electronic, mechanical, photocopying, recording or otherwise, except as permitted by law. Advice on how to obtain permission to reuse material from this title is available at http://www.wiley.com/go/permissions.

The right of Eric R. Carlson and Robert A. Ord to be identified as the authors of the editorial material in this work has been asserted in accordance with law.

Registered Office
John Wiley & Sons, Inc., 111 River Street, Hoboken, NJ 07030, USA

Editorial Office
111 River Street, Hoboken, NJ 07030, USA

For details of our global editorial offices, customer services, and more information about Wiley products visit us at www.wiley.com.

Wiley also publishes its books in a variety of electronic formats and by print-on-demand. Some content that appears in standard print versions of this book may not be available in other formats.

Limit of Liability/Disclaimer of Warranty
The contents of this work are intended to further general scientific research, understanding, and discussion only and are not intended and should not be relied upon as recommending or promoting scientific method, diagnosis, or treatment by physicians for any particular patient. In view of ongoing research, equipment modifications, changes in governmental regulations, and the constant flow of information relating to the use of medicines, equipment, and devices, the reader is urged to review and evaluate the information provided in the package insert or instructions for each medicine, equipment, or device for, among other things, any changes in the instructions or indication of usage and for added warnings and precautions. While the publisher and authors have used their best efforts in preparing this work, they make no representations or warranties with respect to the accuracy or completeness of the contents of this work and specifically disclaim all warranties, including without limitation any implied warranties of merchantability or fitness for a particular purpose. No warranty may be created or extended by sales representatives, written sales materials or promotional statements for this work. The fact that an organization, website, or product is referred to in this work as a citation and/or potential source of further information does not mean that the publisher and authors endorse the information or services the organization, website, or product may provide or recommendations it may make. This work is sold with the understanding that the publisher is not engaged in rendering professional services. The advice and strategies contained herein may not be suitable for your situation. You should consult with a specialist where appropriate. Further, readers should be aware that websites listed in this work may have changed or disappeared between when this work was written and when it is read. Neither the publisher nor authors shall be liable for any loss of profit or any other commercial damages, including but not limited to special, incidental, consequential, or other damages.

Library of Congress Cataloging-in-Publication Data applied for
[ISBN: 9781119730187]

Cover image:
Cover design by

Set in 10.5/12pt Slimbach by Straive, Pondicherry, India

10 9 8 7 6 5 4 3 2 1

Contents

Contributors		vii
Foreword to the First Edition		ix
Foreword to the Second Edition		xi
Foreword to the Third Edition		xiii
Preface to the First Edition		xv
Preface to the Second Edition		xvii
Preface to the Third Edition		xix
Acknowledgments		xxi
About the Companion Website		xxiii
Chapter 1	Surgical Anatomy, Embryology, and Physiology of the Salivary Glands *John D. Langdon*	1
Chapter 2	Diagnostic Imaging of Salivary Gland Pathology *J. Michael McCoy and Pradeep K. Jacob*	19
Chapter 3	Infections of the Salivary Glands	79
Chapter 4	Cysts and Cyst-Like Lesions of the Salivary Glands	117
Chapter 5	Sialolithiasis	145
Chapter 6	Systemic Diseases Affecting the Salivary Glands	175
Chapter 7	Salivary Gland Pathology in Children and Adolescents	201
Chapter 8	Classification, Grading, and Staging of Salivary Gland Tumors *J. Michael McCoy and John Sauk*	225
Chapter 9	The Molecular Biology of Benign and Malignant Salivary Gland Tumors *Randy Todd*	269
Chapter 10	Tumors of the Parotid Gland	301
Chapter 11	Tumors of the Submandibular and Sublingual Glands	345
Chapter 12	Tumors of the Minor Salivary Glands	373
Chapter 13	Radiation Therapy for Salivary Gland Malignancies *Joseph R. Kelley and Max Ofori*	435
Chapter 14	Systemic Therapy for Salivary Gland Cancer *Janakiraman Subramanian and Lara Kujtan*	455
Chapter 15	Non-salivary Tumors of the Salivary Glands	471

Chapter 16 Trauma and Injuries to the Salivary Glands 509

Chapter 17 Miscellaneous Pathologic Processes of the Salivary Glands 543

Chapter 18 Complications of Salivary Gland Surgery 569
Michael D. Turner

Chapter 19 Innovations in Salivary Gland Surgery 601
Mark McGurk and Katherine George

Index 625

Contributors

Eric R. Carlson, DMD, MD, EdM, FACS
Department of Oral and Maxillofacial Surgery, University of Tennessee Graduate School of Medicine, University of Tennessee Cancer Institute, Knoxville, TN, USA

Robert A. Ord, BDS, MB BCh (Hons), FRCS, FACS, MS, MBA
Department of Oral and Maxillofacial Surgery, University of Maryland Medical Center, Greenbaum Cancer Institute, Baltimore, MD, USA

Katherine George, BDS, BSc, MBBS, MFDS RCS (Eng), FRCS (OMFS)
Oral and Maxillofacial Surgeon, Kings College Hospital NHS Foundation Trust, Denmark Hill, London, UK

Pradeep Jacob, MD, MBA
Private Practice of Radiology, Chattanooga, TN, USA

Joseph Kelley, MD, PhD
Director of Clinical Research, GenesisCare USA of North Carolina

Lara Kujtan, MD, MSc
Department of Medicine, University of Missouri at Kansas City, Kansas City, MO, USA

John D. Langdon, FKC, MB BS, BDS, MDS, FDSRCS, FRCS, FMedSci
Department of Maxillofacial Surgery, King's College, London, England

J. Michael McCoy, DDS
Departments of Oral and Maxillofacial Surgery, Pathology, and Radiology, University of Tennessee Graduate School of Medicine, Knoxville, TN, USA

Mark McGurk, BDS, MD, FRCS, DLO, FDS, RCS
Head and Neck Academic Center, Department of Head and Neck Surgery, University College London Hospital, London, UK

Max Ofori, MD
Division of Radiation Oncology, University of Tennessee Medical Center, Knoxville, TN, USA

John J. Sauk, DDS, MS, FAAAS, FAHNS
School of Dentistry, University of Louisville, Louisville, KY, USA

Janikiraman Subramanian, MD
Department of Medicine, Thoracic Oncology and Center for Precision Oncology, Saint Luke's Cancer Institute, University of Missouri at Kansas City, Kansas City, MI, USA

Randy Todd, DMD, MD, DSc
Private Practice of Oral and Maxillofacial Surgery (retired), Peabody, MA, USA

Michael D. Turner, DDS, MD, FACS
Division of Oral and Maxillofacial Surgery, Mount Sinai Hospital, Icahn Mount Sinai School of Medicine, New York, NY, USA

Foreword First Edition

The mention of "head and neck cancer" immediately connotes the sobering realities and potentials of oral squamous cell carcinoma. Left to secondary recollection and awareness is the significance of salivary gland malignancy. The same can be said for the general perception of benign salivary neoplasia. In this brilliant new textbook, authors Carlson and Ord correct these notions, focusing proper emphasis on the group of diseases which, in their malignant form, represent some three percent of all North American head and neck tumors, affecting a minimum of 2500 victims per year.

One marvels at the dedication, energies, and resources – to say nothing of the expertise – mustered to produce a volume of this depth and expanse. While almost forty percent of the effort is directed toward the vitally significant elements of classification, diagnosis, and clinical care of neoplasia, there is more – much more – here, for both the training and practicing readerships. The whole array of salivary gland dysfunctions is marvelously displayed in meaningful clinical color, in easily grasped sketches and graphs, and in well-chosen descriptive imaging. From the mandatory fundaments for such an undertaking – John Langdon's discourse on macro- and microanatomy, Pradeep Jacob's presentation on imaging diagnostics (45 pages!), John Sauk's explanations of current classification and staging of tumors – to the surgical demonstrations of pathology, anatomy, and technique, the visual material is extraordinary.

What are the vagaries in defining the SMAS layer, can cell type be distinguished on the basis of imaging alone, what influence do genomics and biomarkers have in clinical classification, does contemporary understanding explain the etiology of mucous escape phenomena? Up-to-date propositions on such topics occupy these chapters. Clinical challenges, traditional and new, e.g., transection of ducts and nerves, intraductal micromanipulations, salivary diagnostics – they're all here, presented in clear, expansive, prose (28 pages of information on sialolithiasis alone!). The detriments of age and metabolic disorder on gland function, the genesis of non-salivary tumors inside the glands, and the lodging of metastatic disease within their confines receive emphasis in these pages. So do the presence of aberrant glands and the esoteric transplantation of salivary tissue in the management of xerophthalmia.

The *Textbook and Color Atlas of Salivary Gland Pathology* is authoritative. Its authors do not write anecdotally, but from the combined experience of decades which has elevated them both to international recognition in the field of head and neck neoplasia. Their clinical material here presented represents volumes in the operating room, and the comprehensive bibliographies in each of the text's chapters testify to the authors' awareness of their topic and their world-views. Eric Carlson displays the fruits of his earlier endeavors in Pittsburgh, Detroit, and Miami, and speaks now from his position as Professor and Chairman in the Department of Oral and Maxillofacial Surgery at the University of Tennessee Graduate School of Medicine in Knoxville. Robert Ord established his worthy reputation in Britain before resettling himself in Baltimore on the western shores of the Atlantic some 20 years ago, where he now serves as Professor and Chairman of the Department of Oral and Maxillofacial Surgery at the University of Maryland. Theirs is the first time in this domain engineered authoritatively by oral and maxillofacial surgeons, and does honor to their colleagues and forebears in the specialty who have toiled in the vineyards of salivary gland pathology. Neither in design nor execution, however, is their marvelous achievement directed to a parochial audience. Rather, surgeons or clinicians of whatever ilk will offer the authors a nod of appreciation in benefitting from this text.

Probably, one day, an expansion of this work will be written; and, undoubtedly, Carlson and Ord will write it.

R. Bruce MacIntosh, DDS
Detroit
June 2008

Foreword Second Edition

Casual students of surgery of pathology might be inclined to ask what can possibly have transpired over the past seven years to warrant a new edition of a text concerning salivary gland dysfunction only first published in 2008. The prevalence of salivary gland neoplasia in comparison to other oral tumors is very small, and to whole body cancer even smaller; significant trauma to the glands ranks low in incidence compared to the rest of maxillofacial injuries; no one dies from inflammatory or immune disease of the glands; don't these facts mitigate against the need for a new textbook on the salivary glands every few years?

Quite the contrary! Because the 2008 Carlson-Ord volume was one of the very few works – and certainly the most comprehensive – dedicated solely to their topic, it is almost mandatory that it be reviewed and up-dated on a regular basis to provide clinicians and educators an authoritative repository of new information in this specialized field of interest.

And, indeed, there is new information! The complexity, variety, and heterogeneity in the origins of salivary gland tumors (as discussed in the new Chapter 8) makes these lesions an ideal study group for the development of all malignant neoplasia; they give credence to the notion that all disease, particularly malignant, is ultimately individualized and not to be boxed into currently recognized classifications. Senior readers will well remember the teaching axiom that salivary gland malignancies are impervious to radiation therapy; this new edition's Chapter 12 effectively disassembles that contention. Concurrently with the burgeoning understanding of cellular pathology at the subcellular and molecular levels, the concept of systemic chemotherapy, even targeted therapy, for salivary gland cancers has demanded re-evaluation over the past decade; this is illuminated in the new Chapter 13. Further, the authors have combined their first-hand knowledge with a compilation of all pertinent literature to offer a unique assembly of pediatric salivary gland pathology in Chapter 15, another addition.

While new knowledge – most excitingly provided in Chapters 8, 12, and 13 – and updated bibliographies, sketches, highlighted algorithms, and investigational studies are features of the new text, the focus of these elements and the overall emphasis of the work remains the surgical treatment of patients. Illustrative surgeries from the first edition have been retained, and new cases added to demonstrate principles and additional techniques. Management of the more common salivary tumors, injuries, and infections is well exhibited, but room is provided for illustration of rarer entities (Primary desmoid melanoma of the parotid?! Central (osseous) mucoepidermoid carcinoma of the mandibular ramus?!). Mundane or rare, the range of these maladies, plus the scope and depth of their demonstrated knowledge, attest to the broad experiences of Carlson and Ord in the field of salivary gland abnormality, and deservedly position them in the upper echelons of American salivary gland surgeons.

One could anticipate in 2008 that Carlson-Ord would recognize the abiding need for pertinence and currency in their text; indeed, they have and have delivered again.

Robert Bruce MacIntosh, DDS
Department of Oral and Maxillofacial Surgery,
University of Detroit Mercy School of Dentistry,
Detroit, MI, USA

Foreword Third Edition

What defines dedication if not the willing contribution of countless hours, huge blocks of energy, and outpouring of intellect and meaningful experience to construct a landmark scientific text? Indeed, these were the elements that Eric Carlson and Robert Ord mobilized in 2008 in introducing to the surgical world their first – now landmark – textbook on salivary gland pathology and treatment. Their dedication to the topic was intense – they had elevated it to the level of subspecialty – and the volume's success prompted an updated second edition in 2016. Now, with Carlson-Ord-III, they have answered the continuing demand and – because of progress within the discipline – the need, for integration of previous writing with new information in the field.

To be a good scientific writer, an author must first be a good teacher, ready to anticipate uncertainties, confusion, or missed emphasis in the minds of his less-initiated readers, but also ready to anticipate the worthy critique of an experienced colleague. Both Carlson and Ord have easily answered this requirement, not only in their decades-long responsibilities in the resident education milieu but in countless lecture engagements, conferences, and surgical activities worldwide. Their word on the topic of salivary gland maladies is authority, and it is effectively transmitted both in the operating room and from the podium.

Some say today that a textbook is passé, that what is important in the literature can be much more efficiently harvested through one's fingertips on a computer. The good textbook is bifocal, however: It must be a lightning rod for all that is new and exciting at the time of printing, but also an entombed repository of everything pertinent that has been recorded up to that date. To honor the functions, the authors have labored diligently to review and update the bibliographies of the texted materials, including pertinent meta-analyses of earlier literature, and inserting more descriptive visuals of earlier material where appropriate. New features of this Third Edition include greater than 100 new full-color images, illustrated case presentations to demonstrate important clinical situations, and new chapters on minimally invasive surgery and the complications of surgery in the field. The roster of contributing faculty now numbers 14. With this detailed review and revision, the new edition provides an edited compilation of salivary gland pathology not readily recoverable through journal review, regardless how efficient.

From the perspective of 50 + years of navigation in the ablative and reconstructive precincts of oral and maxillofacial surgery, one can safely relate today's circumstances to those of "back when". In the earlier decades of the last half-century, imaging diagnosis of salivary gland disease depended chiefly on plain radiography and contrast sialography; microscopic diagnosis was dependent on the accommodation of a tumor to one of perhaps a dozen epithelial variants; chemotherapy protocols were essentially adaptions of those used for management of squamous cell carcinoma; salivary carcinoma was thought impervious to radiation therapy; surgical management of salivary malignancy fell almost exclusively to those few otolaryngologists, general surgeons, or, more infrequently, oral and maxillofacial surgeons, with special interests in treating these relatively uncommon lesions.

Immense progress in understanding the pathophysiology of salivary gland disease in later years has delivered incredibly complicated microscopic classifications and more precisely directed chemical treatment protocols, and over the past two decades, the earlier assumption that salivary gland disease was impervious to radiation therapy has been demolished. This improved understanding of salivary gland biology has brought in train the need for increasingly well-founded and sophisticated care within all interested surgical groups; Dr. Carlson in Knoxville, and Dr. Ord in Baltimore have answered this call with their surgical expertise and recognized educational efforts in oral and maxillofacial surgical training.

With this Third Edition, the authors have ensured their volume's position in the lexicon of surgical texts, a metric against which all future efforts will be scaled.

Robert Bruce MacIntosh, DDS
Department of Oral and Maxillofacial Surgery,
University of Detroit Mercy School of Dentistry,
Detroit, MI, USA

Preface First Edition

The concept of this book devoted to the diagnosis and management of salivary gland pathology arose from our longstanding friendship and professional relationship where we first collaborated in the early 1990s. This led to a trip to India with the Health Volunteers Overseas in 1996, where we operated numerous complex cancer cases, including many salivary gland malignancies. Dr. Carlson's interest in benign and malignant tumor surgery was fostered by the expert surgical tutelage of Dr. Robert E. Marx at the University of Miami Miller School of Medicine/Jackson Memorial Hospital in Miami, Florida. It was the training by Professor John Langdon who nurtured Dr. Ord's love of the parotidectomy. Over the years, following the publication of several papers and book chapters devoted to salivary gland surgery, we realized that a textbook and atlas related to this discipline should be produced. It was believed that a work written by two surgeons who shared similar surgical philosophies would be a unique addition to the current literature. This has been a project that we have approached with energy and enthusiasm which hopefully is evident to the reader.

The diagnosis and management of salivary gland pathology are an exciting and thought provoking discipline in medicine, dentistry, and surgery. It is incumbent on the clinician examining a patient with a suspected developmental, neoplastic, or non-neoplastic lesion of the major or minor salivary glands to obtain a comprehensive history and physical examination, after which time a differential diagnosis is established. A definitive diagnosis is provided with either an excisional or incisional biopsy depending on the gland involved and the differential diagnosis established preoperatively. A complete understanding of the anatomic barriers surrounding a salivary gland lesion is paramount when performing surgery for a salivary gland neoplasm.

It is the purpose of this Textbook and Color Atlas of Salivary Gland Pathology to provide both text and clinical images, thereby making this a singular work. The reader interested in the science and evidence based medicine associated with the management of salivary gland pathology will be attracted to our text. The reader interested in how to perform salivary gland surgery as a function of diagnosis and anatomic site will find the real-time images useful. To that end, artist sketches are limited in this book. Where appropriate, algorithms have been included as a guide for diagnosis and management. It is our hope that this text and atlas will find a home on the bookshelves of those surgeons who share our fascination with the diagnosis and management of salivary gland disease.

Eric R. Carlson, DMD, MD, FACS
Robert A. Ord, DDS, MD, FRCS, FACS, MS

Preface Second Edition

In 2008, we published our first work entitled Textbook and Color Atlas of Salivary Gland Pathology – Diagnosis and Management. In preparation for the development and publication of the second edition of this book, several issues became apparent that resulted in changes and additions to our first edition. The first change is the title. We selected Salivary Gland Pathology – Diagnosis and Management due to the inherent and obvious textbook nature of this work. In addition, our readership is aware that our teaching mission involves the use of high quality color images to illustrate the cases included in each chapter and to guide the reader through the workup and execution of the medical and surgical management of salivary gland pathology. The title was shortened accordingly. All chapters have been updated in terms of references and the addition of new cases to illustrate important points within each chapter. This includes Chapter 7, *Classification, Grading, and Staging of Salivary Gland Tumors*, where histomicrographs of most of the benign and malignant salivary gland neoplasms are now illustrated in the chapter. In keeping with our expanding knowledge base of the diagnosis and management of salivary gland pathology, we have included four new chapters in this second edition, including those devoted to the molecular biology of benign and malignant salivary gland tumors, radiation therapy for salivary gland tumors, systemic therapy for salivary gland cancer, and pediatric salivary gland pathology. Four new authors have been added including Drs. Joseph Kelley, J. Michael McCoy, Janakiraman Subramanian, and Randy Todd. Where appropriate, algorithms have been included in the chapters to assist in decision making processes associated with the management of salivary gland pathology.

As with the first edition of this textbook, it is our expressed purpose to make this second edition a singular work with extensive text and clinical images. It is our hope that this textbook will provide a useful update to our international colleagues who benefited from the first edition.

Eric R. Carlson, DMD, MD, FACS
Robert A. Ord, DDS, MD, FRCS, FACS, MS, MBA

Preface Third Edition

We enthusiastically present the third edition of Salivary Gland Pathology – Diagnosis and Management to practitioners and trainees, surgeons and pathologists, and clinicians and scientists alike. The World Health Organization's updated classification of head and neck tumors in 2017, including that of salivary gland tumors, is a reminder to the reader of the ephemeral nature of salivary gland pathology as well as the inherent need to frequently update our knowledge base. Therein, this third edition of our tome exploits the new information available regarding the taxonomy of salivary gland tumors as well as new neoplastic and non-neoplastic entities, image guided biopsies of salivary gland lesions, minimally invasive surgery to address these entities, and the complications encountered in traditional and nontraditional forms of salivary gland surgery. To this end, we introduce two new chapters and five new authors. Professor Mark McGurk of the United Kingdom requires no introduction as his contributions to oral and maxillofacial surgery, and especially salivary gland surgery, are extensive, innovative, highly meaningful, and transformational. Dr. Katherine George teamed up with Professor McGurk to review their experiences with innovative salivary gland surgery, including diagnostic and therapeutic sialendoscopy. Dr. Michael Turner of New York City is also an accomplished salivary gland surgeon and lends his expertise in the management of complications to our textbook. Dr. Laura Kujtan joins Dr. Subramanian in their update of chemotherapy and targeted therapy for salivary gland malignancies. Finally, Dr. Ofori collaborated with Dr. Joseph Kelley in their scholarly review of radiation therapy in the management of salivary gland tumors.

The practice of twenty-first century medicine and surgery exists within a data-driven world. To that end, all chapters are updated in terms of new references and many meta-analyses/systematic reviews are reviewed in the spirit of supporting evidence-based practice. New cases have been added to most chapters to illustrate important points. Algorithms continue to be offered to assist clinicians in decision-making processes associated with the management of salivary gland pathology. Most chapters also contain a new teaching element – case presentations that serve to illustrate and reinforce essential take-home messages either suggested or emphasized in their respective chapters. Finally, videos of salivary gland surgical procedures are included in the chapter devoted to innovative salivary gland surgery in this third edition.

As with the first and second editions of this textbook, it is our expressed purpose to brand this third edition a singular reference with extensive text and clinical images. It is our hope that this textbook will provide a useful update to our international colleagues and their patients who benefited from the prior editions.



Eric R. Carlson, DMD, MD, EdM, FACS



Robert A. Ord, BDS, MB BCh (Hons), FRCS, FACS, MS, MBA

Acknowledgments

I would like to thank my teachers, residents, fellows, and patients for their trust, encouragement, wisdom, and inspiration. I am grateful to all of you.

Eric R. Carlson

To my wife, Sue, my inspiration as always.

Robert A. Ord

About the Companion Website

Don’t forget to visit the companion web site for this book:

www.wiley.com/go/carlson/salivary 

There you will find valuable materials, including:

- Videos

Scan this QR code to visit the companion website:

SEM *see* scanning electron microscopy
sensory innervation, 12–13
serous cells, 14
shock wave lithotripsy, 154–158, 160–162, 206, 614–615, *614–615*
short tau inversion recovery (STIR), 26–27, *27*, *44*, *50*
shotgun wounds, 510, *511*, 522
sialadenectomy
  complications of salivary gland surgery, 586, *586*, 588–590
  innovations in salivary gland surgery, 608–609
sialadenitis, 79–115
  acute bacterial parotitis, 82, *83–84*, 85–89, *87–88*, *90–91*, 111–114, *112–113*
  acute bacterial submandibular sialadenitis, 98–99, *98–99*
  autoimmune sialadenitis and IgG4-related disease, 110–111
  bacterial sialadenitis in pregnancy, 108–110, *109*
  case presentation, 111–114, *112–113*
  cat-scratch disease, 99–102, *103–104*
  children and adolescents, 203–207, *204–207*
  chronic bacterial parotitis, 89–97, *91–96*
  chronic recurrent juvenile parotitis, 97–98
  chronic recurrent submandibular sialadenitis, 99, *100–102*
  classification, **81**
  complications of salivary gland surgery, *570*
  diagnostic imaging, 52, *52–53*
  HIV/AIDS, 82, 105–107, *108*
  influenza A, 107–108
  introduction and general considerations, 79–85
  Küttner tumor, 557–558
  mumps, 85, 105
  nontuberculous mycobacterial disease, 104–105, *106*
  risk factors, 79–85, **81–82**
  sialolithiasis, 145, 146, 148–149
  tuberculous mycobacterial disease, 102–104
  tumors of the submandibular and sublingual glands, 346
sialadenoma papilliferum (SP), 233, *233*
sialadenosis *see* sialosis
sialendoscopy and sialography
  basket retrieval of stones, 610–613, *611–613*
  children and adolescents, 206–207
  chronic bacterial parotitis, 89, *92–94*
  chronic recurrent juvenile parotitis, 97
  chronic recurrent submandibular sialadenitis, 99
  clinical indications, 32, *33*
  combined open and endoscopic stone removal, 616–617, *616*
  complications of salivary gland surgery, *570*, 581–583, *581–582*, 586–587, *587*
  concepts and definitions, 32
  fragmentation of stones, 613–615, *614–615*
  imaging modalities for sialolithiasis, 609, *609–610*
  intraoral stone release, 615–616, *615*
  minimally invasive surgery, 608–617
  salivary duct strictures, 617–621, *619–620*
  sialolithiasis, 146, 149, 157–158, *158*
  technique and equipment, 33–35, 609–610, *610–611*
  traumatic injury to the salivary glands, 515, 529, *530*, 533–534
sialoblastoma, 245–246
sialoceles
  complications of salivary gland surgery, 578–579, *579*
  traumatic injury to the salivary glands, 512–515, *512–515*
sialodochoplasty
  complications of salivary gland surgery, *583*, 588, *589*
  hereditary and congenital conditions, *545*
  sialolithiasis, 152–153, *165*
  traumatic injury to the salivary glands, 529, *529*
sialolithiasis, 145–174
  case presentation, 168–172, *169–172*
  children and adolescents, 203–206
  clinical features, 147–149, *147–149*
  complications of salivary gland surgery, 578–579, *579*, 586, *588–589*
  composition of saliva, 146, **147**
  diagnosis and differential diagnosis, 150, *151–153*
  diagnostic imaging, 55, *55*
  etiology and epidemiology, 145
  innovations in salivary gland surgery, 608–609, *609*
  multiple and bilateral sialoliths, 149–150, 162, *164–165*
  nephrolithiasis, cholelithiasis, primary hyperparathyroidism, and gout, 147, 166–168
  parotid sialolithiasis, 147–150, **147**, 159–162, *159–165*
  pathophysiology, 145–146, **147**
  sialadenitis, 145, 146, 148–149

sialolithiasis (*Cont'd*)
sublingual and minor salivary gland sialolithiasis, 147, 162, *166*
submandibular sialolithiasis, 146–150, *147–149*, **147**, 152–158, *154–158*, *164–165*, 168–172, *169–172*
treatment, 150–162
tumors of the submandibular and sublingual glands, 346
sialolithotomy, 152, 160
sialosis, 192–194
clinical manifestations, 193
diagnosis with salivary gland biopsy, 193–194, *194*
diagnostic imaging of salivary gland pathology, 54–55
etiology and classification, 192–193, **192**
Sicca syndrome, 560
single photon emission computed tomography (SPECT), 46
sinuses, 545–548, *547*, *549–553*
Sjögren syndrome, 175–185
amyloidosis, 560
children and adolescents, 203
clinical manifestations, 176–177, *177*
complications of salivary gland surgery, *587*
diagnosis with salivary gland biopsy, 180–185, *183–185*
diagnostic imaging, 34–35, *34*, 55–56, 64
epidemiology, 175–176
extraglandular findings, 175, **176**
lymphoma, 177–180, *177–178*, 184–185
Mikulicz disease, 178–180, *179–182*
minor salivary glands, 180, *181–182*, 183, 185
non-salivary tumors of the salivary glands, 483–485
pathophysiology, 176
sialadenitis, 110–111
skin cancers, 479, *482*, 486–493, *488–492*
SLE *see* systemic lupus erythematosus
small B-cell lymphoma, *252*
small cell neuroendocrine carcinoma (SCNEC), 248, 493–495, *496–497*
SMAS *see* superficial musculoaponeurotic system
smoking
systemic therapy for salivary gland cancer, 456, 462
tumors of the parotid gland, 302
SP *see* sialadenoma papilliferum
SPECT *see* single photon emission computed tomography
spindle cell tumor, *252–253*
spin-echo T1 MRI, 25, *25*, **26**, *43–44*, *46–47*, *51*, *53*, *64*
spin-echo T2 MRI, 25, **26**, *27*, *47*, *51*, *57*, *63–64*
squamous cell carcinoma (SCC)
classification systems for salivary gland tumors, 246, *246*
molecular biology of salivary gland tumors, 269
non-salivary tumors of the salivary glands, 479, *482*, 486–493, *488–492*
radiation therapy for malignant tumors, 436, 437, 440
saliva, 550, 554
tumors of the parotid gland, 302
standardized uptake values (SUV), 39–41, *41*, **42**, 63–64
Staphylococcus spp., 86, 206
stenosis
innovations in salivary gland surgery, 619–621
parotid duct orifice, 583
Stensen duct
complications of salivary gland surgery, *583*
sialadenitis, 82, *84*, 85, 97, 111–114, *112–113*
sialolithiasis, 147, *148*, 160, *160–161*
traumatic injury to the salivary glands, 524–525, *526–527*, *530*
sternocleidomastoid muscle (SCM)
complications of salivary gland surgery, 577, 578
diagnostic imaging, 44–45
tumors of the parotid gland, 308–312
STIR *see* short tau inversion recovery
Streptococcus spp., 86, 97, 146, 206
stricture formation
classification of salivary duct strictures, 618
complications of salivary gland surgery, 586–587, *587*
dilatation techniques, 618–619, *619–620*
imaging modalities, 617–618
innovations in salivary gland surgery, 617–621
treatment and outcomes, 618–621, *619–620*
stroke, *518*
stylomandibular ligament, 4–5, *4*
sublingual gland
anatomy, embryology, and physiology, 13
complications of salivary gland surgery, 583–588
cysts and cyst-like lesions, 121–125, *123–124*
diagnostic imaging, 48–49, *48–49*
innovations in salivary gland surgery, 606–608

non-salivary tumors of the salivary glands, *483*, 487–488
saliva, 555–556
sialolithiasis, 147, 162, *166*
Sjögren syndrome, 177
systemic therapy for salivary gland cancer, 456
tumors of the sublingual glands, 345–372
case presentation, 365–370, *366–368*
diagnosis, **347**, 350–351, *351*
epidemiology and etiology, 345–346
management, 359–363, *359–365*
submandibular gland, 9–13
agenesis, 16–17, *17*
amyloidosis, 560
anatomical structures, 10–13, *10–12*
blood supply and lymphatic drainage, 12
children and adolescents, 203–206, *205*, 214
complications of salivary gland surgery, 570, *570*, 583–590
cysts and cyst-like lesions, 125–126, *126*
deep lobe, 11, *12*
diagnostic imaging, *31*, *33*, 45–48, *46–47*
embryology, 9–10
hereditary and congenital conditions, 544–545
IgG4-related disease, 196–199, *197–198*
innovations in salivary gland surgery, 608, 615–616, *615*
nerve supply, 12–13, *12*
non-salivary tumors of the salivary glands, 478–479, *478*, 483, 487
radiation therapy for malignant tumors, 439
saliva, 555–556
sarcoidosis, 186–187, *191*
sialadenitis, 79, *81*
sialolithiasis, 146–150, *147–149*, **147**, 152–158, *154–158*, *164–165*, 168–172, *169–172*
Sjögren syndrome, 177
submandibular duct, 11–12
superficial lobe, 11, *11*
systemic therapy for salivary gland cancer, 456
traumatic injury to the salivary glands, 510–512, 529, 531, *531*, 533
tumors of the submandibular glands, 345–372
case presentation, 365–370, *366–368*
diagnosis, 346–349, *347–350*
epidemiology and etiology, 345–346
management, 351–359, *352–357*
see also individual disorders
superficial lobe
anatomy, embryology, and physiology, 11, *11*
tumor, *315*, *328–329*
superficial musculoaponeurotic system (SMAS), 2–3, 308, 523–524, 577, *577*, 578
suppurative parotitis, 111–114, *112–113*
children and adolescents, 206, *206*
sural nerve graft, 517–519, *522*
SUV *see* standardized uptake values
sympathetic nervous system, 12, 14–16
synovial cell carcinoma, *480–481*
syringoma, 488, *488*
systemic lupus erythematosus (SLE), 110
systemic therapy *see* chemotherapy

TB *see* tuberculosis
tear flow tests, 177
temporalis fascia, 581
temporoparietal flap (TPF), 523–524, 576, 578
three-dimensional conformal radiation therapy (3D-CRT), 442–443, *443*
tissue inhibitors of matrix metalloproteinases (TIMP), 176, 280
TNM staging, 255–256, **257–259**
tongue tumors, 379, *404–406*, 487–488
TPF *see* temporoparietal flap
traumatic injury to the salivary glands, 509–541
barotrauma, 534–535
blunt trauma, *535*
penetrating injuries, 509–529
facial nerve injuries, 515–522, *516–522*
Frey syndrome, 522–524, *524*
hollowing, 524
management algorithm, *534*
salivary fistula, 509–512, *510–511*
sialocele, 512–515, *512–515*
stricture of the salivary duct, 529, *530*
transection of the salivary duct, 524–529, *525–529*
radiation injury, 530–534, *531*
trumpet blower's syndrome, 82
tubarial salivary glands, 13–14
tuberculosis (TB), 102–104
tumorigenesis, 271, 275, 283, 288
tumor initiation cell theory, 274
tumors *see* benign neoplasms; malignancies
tumor suppressor genes, 271, 275, 283

tympanic neurectomy, 580–581
tyrosine kinase inhibitors, 285, 288–290

ulceration, 376
ultrasonography (US)
  concepts and definitions, 31–32, *31–32*
  hereditary and congenital conditions, 544
  image-guided biopsies, 35–36, *37*
  innovations in salivary gland surgery, 609, *609*, 617
  Küttner tumor, 561, *562*
  non-salivary tumors of the salivary glands, 471–473
  sarcoidosis, 56
  technique, 32
  tumors of the parotid gland, 304
  tumors of the submandibular and sublingual glands, 349, *350*
undifferentiated carcinoma
  classification systems for salivary gland tumors, 248–249, *248–249*
  molecular biology of salivary gland tumors, 274
  radiation therapy for malignant tumors, 436, 440
  tumors of the parotid gland, 325
uric acid, 147, 166–168
US *see* ultrasonography

vaccination, 105
vascular endothelial growth factor (VEGF), 279–280
vascular lesions
  diagnostic imaging, 50–52, *50–51*
  non-salivary tumors of the salivary glands, 473
vascular malformation
  non-salivary tumors of the salivary glands, 473
  tumors of the submandibular and sublingual glands, 347–348
vascular tumors, 210–211, *210–212*
VEGF *see* vascular endothelial growth factor
volumetric modulated arch therapy (VMAT), 442–447, *444*, 449–451

Warthin tumor
  children and adolescents, 209–210
  classification systems for salivary gland tumors, 230, *230*
  diagnostic imaging, 59, *59*, 68, *68–74*
  systemic therapy for salivary gland cancer, 456
  tumors of the parotid gland, 302, *305*, 324–325, *326–327*
Wharton duct
  complications of salivary gland surgery, *584*
  cysts and cyst-like lesions, 122, *123–124*
  hereditary and congenital conditions, 544, *545*
  innovations in salivary gland surgery, 620
  sialadenitis, 85, 98
  sialolithiasis, 146, 152, *155*, *164–166*
  traumatic injury to the salivary glands, 529, *529*
  tumors of the submandibular and sublingual glands, 355
Wnt/β-catenin pathway, 277
World Health Organization (WHO), **227**

xerophthalmia, 556
xerostomia
  hereditary and congenital conditions, 543–544, 550–554, 556
  IgG4-related disease, 196
  radiation therapy for malignant tumors, 445–446, *445*
  sialolithiasis, 172
  Sjögren syndrome, 175–177
  traumatic injury to the salivary glands, 532–534
X-ray diffraction analysis (EDX), 146