

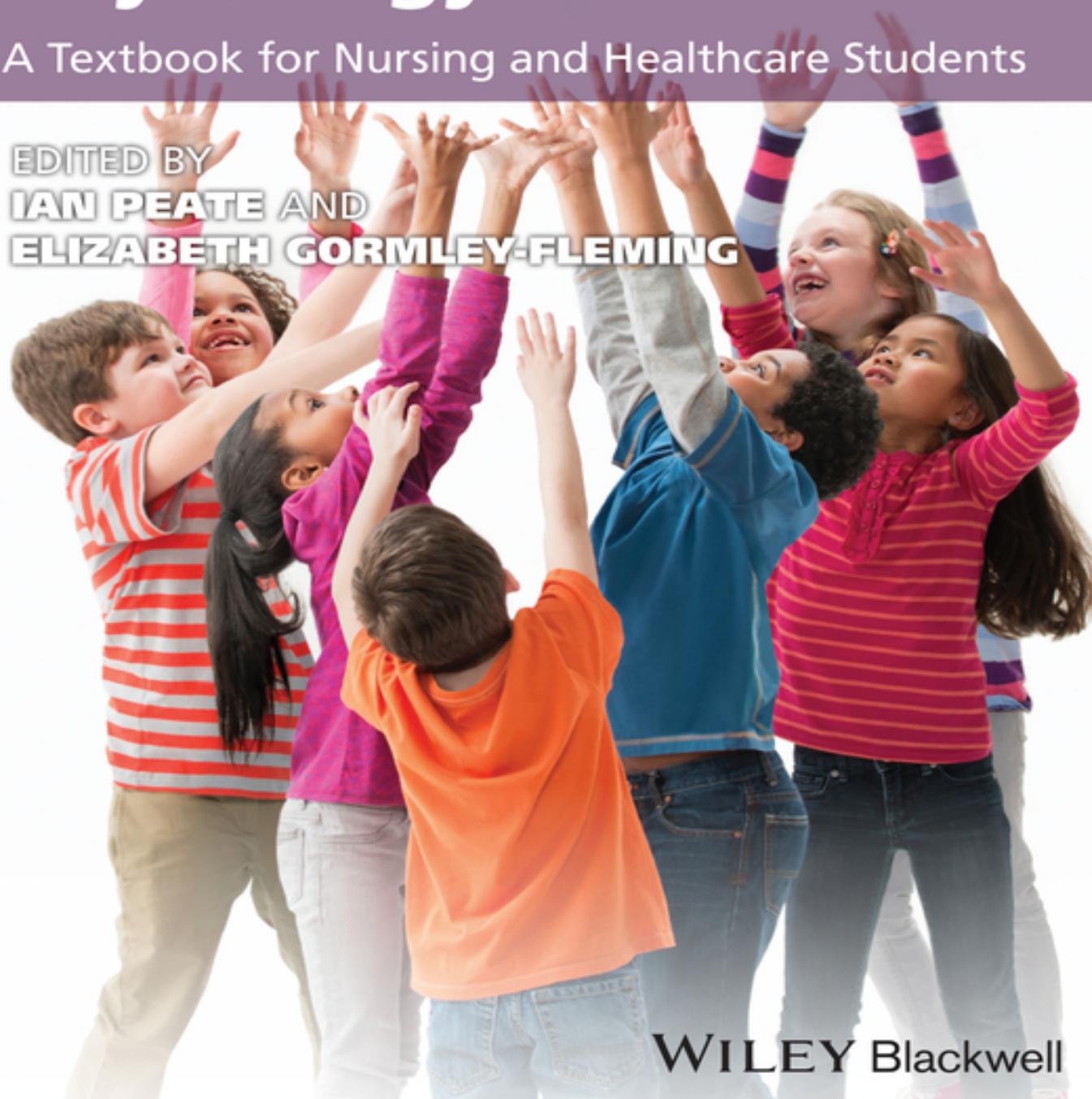
FUNDAMENTALS

SECOND EDITION

# Fundamentals of Children and Young People's Anatomy and Physiology

A Textbook for Nursing and Healthcare Students

EDITED BY  
IAN PEATE AND  
ELIZABETH GORMLEY-FLEMING



WILEY Blackwell

# Table of Contents

[Cover](#)

[Series Page](#)

[Title Page](#)

[Copyright Page](#)

[Contributors](#)

[Preface](#)

[Anatomy and physiology](#)

[The Nursing and Midwifery Council](#)

[Chapter content](#)

[Web-based materials](#)

[References](#)

[Acknowledgements](#)

[How to use your textbook](#)

[Features contained within your textbook](#)

[About the companion website](#)

[Chapter 1: Children and young people's health and well-being](#)

[Aim](#)

[Introduction](#)

[The concept of childhood](#)

[Fundamental aspects of children's lives](#)

[Health and well-being of children and young people](#)

[Current influences on the health and well-being of children and young people](#)

[The 'voice' of children and young people](#)

[Public health of children and young people](#)

[Promoting the health of children and young people:  
The role of the children's nurse](#)

[Childhood morbidity and mortality within the  
twenty-first-century context](#)

[Conclusion](#)

[Activities](#)

[References](#)

## [Chapter 2: Homeostasis](#)

[Aim](#)

[Introduction](#)

[Regulation of homeostasis](#)

[Feedback mechanisms](#)

[Homeostatic mechanisms](#)

[Energy production](#)

[Systematic approach to homeostasis](#)

[Gastrointestinal system](#)

[Conclusion](#)

[Activities](#)

[Wordsearch grid 1](#)

[Wordsearch grid 2: Amino acids](#)

[Glossary](#)

[References](#)

## [Chapter 3: Scientific principles](#)

[Aim](#)

[Introduction](#)

[Levels of organisation](#)

[Characteristics of life](#)

[Bodily requirements](#)

[Atoms](#)

[Conclusion](#)

[Activities](#)

[Exercise](#)

[References](#)

## [Chapter 4: The cell](#)

[Aim](#)

[Introduction](#)

[Characteristics of the cell](#)

[The structure of the cell](#)

[The organelles](#)

[Fluids and the body](#)

[Conclusion](#)

[Activities](#)

[Glossary](#)

[References](#)

## [Chapter 5: Genetics](#)

[Aim](#)

[Introduction](#)

[Genes](#)

[From DNA to proteins](#)

[The transference of genes](#)

[Mendelian genetics](#)

[Conclusion](#)

[Activities](#)

[Exercise](#)

[Glossary](#)

[References](#)

## [Chapter 6: Tissues](#)

[Aim](#)

[Introduction](#)

[Types of tissues](#)

[Children and tissue development](#)

[Conclusion](#)

[Activities](#)

[Glossary](#)

[References](#)

## [Chapter 7: The immune system](#)

[Aim](#)

[Introduction](#)

[Blood cell development](#)

[The organs and tissues of the immune system](#)

[Types of immunity](#)

[Immunoglobulins \(antibodies\)](#)

[Actions of antibodies](#)

[Immunisations](#)

[Conclusion](#)

[Activities](#)

[Glossary](#)

[References](#)

## [Chapter 8: Blood](#)

[Aim](#)

[Introduction](#)

[Composition of blood](#)

[Constituents of blood](#)

[Structure and function of blood vessels](#)

[Conclusion](#)

[Activities](#)

[Glossary](#)

[References](#)

## [Chapter 9: The cardiac system](#)

[Aim](#)

[Body map](#)

[Introduction](#)

[Changes at birth](#)

[Position and size of the heart](#)

[Structures of the heart](#)

[The electrical pathway through the heart](#)

[Electrocardiogram](#)

[The cardiac cycle](#)

[Cardiac output](#)

[Factors affecting the heart rate](#)

[Conclusion](#)

[Conditions to consider in relation to the cardiac system](#)

[Activities](#)

[Glossary](#)

[References](#)

## [Chapter 10: The respiratory system](#)

[Aim](#)

[Introduction](#)

[The airway](#)

[The lungs](#)

[Conclusion](#)

[Activities](#)

[Review questions](#)

[Glossary](#)

[References](#)

## [Chapter 11: The endocrine system](#)

[Aim](#)

[Introduction](#)

[Physiology of the endocrine system](#)

[Anatomy of the endocrine system](#)

[Conclusion](#)

[Activities](#)

[References](#)

## [Chapter 12: The digestive system and nutrition](#)

[Aim](#)

[Body map](#)

[Introduction](#)

[Carbohydrates](#)

[Fats](#)

[Proteins](#)

[Fetal development and infant nutrition](#)

[The anatomy and physiology](#)

[Conclusion](#)

[Activities](#)

[References](#)

## [Chapter 13: The renal system](#)

[Aim](#)

[Introduction](#)

[The renal system](#)

[The kidney](#)

[Functions of the kidney](#)

[Blood supply to the kidneys](#)

[Formation of urine](#)

[Composition of urine](#)

[The urethra](#)

[Function of the bladder and micturition](#)

[Conclusion](#)

[Activities](#)

[References](#)

## [Chapter 14: The reproductive systems](#)

[Aim](#)

[Introduction](#)

[Fetal embryology: sexual differentiation](#)

[The male reproductive system](#)

[The female reproductive system](#)

[Conclusion](#)

[Activities](#)

[References](#)

## [Chapter 15: The nervous system](#)

[Aim](#)

[Introduction](#)

[Organisation of the nervous system](#)

[Cellular structure of the nervous system](#)

[Transmission of nerve impulses](#)

[Fetal development](#)

[Childhood development](#)

[Central nervous system](#)

[Peripheral nervous system](#)



[Conclusion](#)

[Activities](#)

[References](#)

## [Chapter 16: The muscular system](#)

[Aim](#)

[Introduction](#)

[Muscle development in early life](#)

[Types of muscle tissue](#)

[Functions of muscular system](#)

[Gross anatomy of skeletal muscle](#)

[The micro-anatomy of the muscle](#)

[Types of muscle fibres](#)

[Skeletal muscle relaxation and contraction](#)

[Contraction](#)

[Energy requirements for muscle contraction](#)

[Organisation of skeletal muscle](#)

[Conclusion](#)

[Activities](#)

[References](#)

## [Chapter 17: The skeletal system](#)

[Aim](#)

[Body map](#)

[Introduction](#)

[The axial skeleton](#)

[The appendicular skeleton](#)

[The function of the skeleton](#)

[Bone structure and growth](#)

[Bone healing](#)

[Bone classification](#)

[Joints](#)

[Conclusion](#)

[Activities](#)

[References](#)

## [Chapter 18: The senses](#)

[Aim](#)

[Introduction](#)

[The sense of smell \(olfaction\)](#)

[The sense of taste \(gustation\)](#)

[The ear](#)

[The sense of equilibrium](#)

[The sense of sight](#)

[Conclusion](#)

[Activities](#)

[Exercises](#)

[References](#)

## [Chapter 19: The skin](#)

[Aim](#)

[Introduction](#)

[The structure of skin](#)

[Functions of the skin](#)

[Conclusion](#)

[Activities](#)

[References](#)

## [Self-assessment answers](#)

[Index](#)

[End User License Agreement](#)

# List of Tables

## Chapter 1

[Table 1.1 Key features of the paradigm of childhood.](#)

[Table 1.2 Key documents that advocate the involvement of children.](#)

[Table 1.3 The current focus of the NHS England Youth Forum.](#)

[Table 1.4 Promoting health, preventing ill health: Future nurse: Standards of...](#)

[Table 1.5 Examples of MECC health-promoting activities for children's nurses.](#)

[Table 1.6 Survival rates for premature babies.](#)

## Chapter 2

[Table 2.1 Normal blood gas values. Source: Adapted from Higgins \(2007\), Verkla...](#)

[Table 2.2 Essential and non-essential amino acids in children. Source: Adapted...](#)

## Chapter 3

[Table 3.1 The fundamental SI units and other common SI units. Source: Peate an...](#)

[Table 3.2 Multiples of SI units.](#)

[Table 3.3 Measures of weight, volume, length and energy.](#)

## Chapter 4

[Table 4.1 Cellular compartments and their functions.](#)

[Table 4.2 Principal electrolytes and their functions.](#)

## Chapter 6

[Table 6.1 The major primary blast cells and their connective tissue type. Sour...](#)

[Table 6.2 Types of connective tissue proper - their main constituents, functi...](#)

## Chapter 8

[Table 8.1 Haematological values for infants and children.](#)

[Table 8.2 Plasma coagulation factors.](#)

[Table 8.3 Blood groups and who they can donate to and receive from.](#)

[Table 8.4 Differences between arteries and veins.](#)

## Chapter 11

[Table 11.1 Hormones of the hypothalamus.](#)

[Table 11.2 Hormones of the pituitary gland.](#)

[Table 11.3 Hormones of the pineal gland.](#)

[Table 11.4 Hormones of the thyroid gland.](#)

[Table 11.5 Hormones of the parathyroid glands.](#)

[Table 11.6 Hormones of the thymus gland.](#)

[Table 11.7 Hormones of the adrenal glands.](#)

[Table 11.8 Hormones of the pancreas.](#)

[Table 11.9 Hormones of the testes and ovaries.](#)

[Table 11.10 Hormones of other organs in the body and their functions.](#)

## Chapter 12

[Table 12.1 Vitamins and minerals required for growth and development, the foo...](#)

[Table 12.2 Pancreatic enzymes and enzyme precursors.](#)

## Chapter 13

[Table 13.1 Renal function in the newborn – key points.](#)

[Table 13.2 Function of the structures within the nephron.](#)

[Table 13.3 Functions of the kidney.](#)

[Table 13.4 Outcome of simple filtration.](#)

[Table 13.5 Composition of urine.](#)

[Table 13.6 Signs and symptoms of UTIs in infants and children.](#)

[Table 13.7 Urine output in 24 h for infants, children and young people.](#)

## Chapter 15

[Table 15.1 Cranial nerves.](#)

[Table 15.2 Effects of the sympathetic and parasympathetic divisions of the au...](#)

## Chapter 16

[Table 16.1 Summary of the muscle tissue.](#)

[Table 16.2 Principal movement functions of muscles.](#)

[Table 16.3 The organisation and functions of the components of skeletal muscul...](#)

[Table 16.4 Muscles of facial expression.](#)

[Table 16.5 The muscles of chewing and of the tongue.](#)

[Table 16.6 Muscles of the neck - function, origin and insertion.](#)

[Table 16.7 Muscles of the shoulder - function, origin and insertion.](#)

[Table 16.8 Muscles of the arm and hand - function, origin and insertion.](#)

[Table 16.9 Muscles of the thorax and abdomen - function, origin and insertion...](#)

[Table 16.10 The function of the hip and pelvis muscles.](#)

[Table 16.11 Function, origin and insertion of the muscles of the thigh, lower...](#)

## Chapter 17

[Table 17.1 The bones of the axial skeleton.](#)

[Table 17.2 The bones of the appendicular skeleton.](#)

[Table 17.3 Ossification.](#)

[Table 17.4 Some factors impacting on bone structure.](#)

[Table 17.5 Six types of joints.](#)

## Chapter 19

[Table 19.1 The layers of the epidermis.](#)

[Table 19.2 The location and functions of the glands of the dermis.](#)

# List of Illustrations

## Chapter 2

[Figure 2.1 \(a\) Cellular respiration. \(b\) Overview of the Krebs cycle.](#)

[Figure 2.2 Oxygen-haemoglobin dissociation curves showing the effect of \(a\) ...](#)

[Figure 2.3 Hormonal regulation of sodium and chloride reabsorption.](#)

[Figure 2.4 Regulation of aldosterone by the renin-angiotensin-aldosterone pa...](#)

[Figure 2.5 Effect of aldosterone on fluid balance.](#)

[Figure 2.6 Regulation of the secretion and action of antidiuretic hormone....](#)

### Chapter 3

[Figure 3.1 Levels of organisation of the body.](#)

[Figure 3.2 The atom.](#)

[Figure 3.3 Schematic diagram of an atom.](#)

[Figure 3.4 Different atoms.](#)

[Figure 3.5 \(a\)-\(d\) Ionic bonding of a sodium and a chlorine atom to form a s...](#)

[Figure 3.6 \(a\)-\(e\) Covalent bonds.](#)

[Figure 3.7 Hydrogen bonds and water.](#)

[Figure 3.8 Pictorial depiction of the chemical equation \(reaction\) producing...](#)

### Chapter 4

[Figure 4.1 Examples of some cells of the human body.](#)

[Figure 4.2 Structure of the cell.](#)

[Figure 4.3 Cell membrane.](#)

[Figure 4.4 Facilitated diffusion.](#)

[Figure 4.5 Effect of solute concentration on a red blood cell. \(a\) Illustrat...](#)

[Figure 4.6 Active transport system.](#)

[Figure 4.7 Pinocytosis, phagocytosis and receptor-mediated endocytosis.](#)

[Figure 4.8 Exocytosis.](#)

[Figure 4.9 Endoplasmic reticulum. \(a\) Details. \(b\) Transverse section. \*Sourc...\*](#)

[Figure 4.10 The cytoskeleton.](#)

[Figure 4.11 Fluid compartments and distribution.](#)

[Figure 4.12 Capillary hydrostatic and osmotic pressures.](#)

## Chapter 5

[Figure 5.1 The cell nucleus.](#)

[Figure 5.2 A pictorial representation of a portion of the double helix.](#)

[Figure 5.3 DNA from double helix to chromosome.](#)

[Figure 5.4 Male human chromosomes.](#)

[Figure 5.5 The separation of DNA and production of further DNA.](#)

[Figure 5.6 mRNA becomes associated with small ribosomal subunit. \(a\) \*Compone...\*](#)

[Figure 5.7 Summary of the movement of the ribosome along mRNA.](#)

[Figure 5.8 Brief summary of protein synthesis.](#)

[Figure 5.9 The cell cycle.](#)

[Figure 5.10 Mitosis. \(a\) Interphase. \(b\) Prophase. \(c\) Metaphase. \(d\) Anapha...](#)

[Figure 5.11 Gene crossover.](#)

[Figure 5.12 Genetic inheritance.](#)



[Figure 5.13 X-linked inheritance.](#)

## Chapter 6

[Figure 6.1 Types of cells.](#)

[Figure 6.2 Simple epithelium.](#)

[Figure 6.3 Simple epithelia types.](#)

[Figure 6.4 Stratified epithelium.](#)

[Figure 6.5 Connective tissue reinforces epithelial tissue.](#)

[Figure 6.6 Where cartilage is found in the body.](#)

[Figure 6.7 Synovial membranes fill joint cavities.](#)

[Figure 6.8 Skeletal muscle cells taken.](#)

[Figure 6.9 Smooth muscle.](#)

[Figure 6.10 Peristalsis.](#)

[Figure 6.11 Nerve cell.](#)

## Chapter 7

[Figure 7.1 Organs and tissues of the immune system.](#)

[Figure 7.2 Haemopoiesis.](#)

[Figure 7.3 Distribution of lymph vessels and nodes.](#)

[Figure 7.4 Organs of lymphocyte production in the fetus.](#)

[Figure 7.5 Location of thymus gland. \(a\) Thymus of an adolescent. \(b\) Thymic...](#)

[Figure 7.6 Simplified drawing of a lymph node.](#)

[Figure 7.7 Stages of phagocytosis: \(a\) stage 1, \(b\) stage 2 and \(c\) stage 3....](#)

[Figure 7.8 Inflammation and the stages that occur.](#)

[Figure 7.9 Flowchart of inflammatory events.](#)

[Figure 7.10 Development of B cell lymphocytes.](#)

[Figure 7.11 Cellular and humoral immune responses.](#)

[Figure 7.12 Primary and secondary responses to infection.](#)

[Figure 7.13 Acquired \(specific\) immunity.](#)

## Chapter 8

[Figure 8.1 Cells of the blood.](#)

[Figure 8.2 Composition of blood in percentages.](#)

[Figure 8.3 The development of blood cells.](#)

[Figure 8.4 Red blood cells.](#)

[Figure 8.5 Destruction of the red blood cell.](#)

[Figure 8.6 Negative feedback mechanism for erythropoiesis.](#)

[Figure 8.7 Platelet plug formation.](#)

[Figure 8.8 Blood coagulation, simplified.](#)

[Figure 8.9 A, B and O blood groups.](#)

[Figure 8.10 Schematic of blood vessels.](#)

[Figure 8.11 Basic structure of an artery and vein.](#)

[Figure 8.12 Walls of blood vessels. \(a\) Artery. \(b\) Vein. \(c\) Capillary. \(d\)...](#)

[Figure 8.13 Capillary networks.](#)

## Chapter 9

[Figure 9.1 The fetal circulation.](#)

[Figure 9.2 Patent ductus.](#)

[Figure 9.3 Transposition of the great arteries. The aorta takes blood from t...](#)

[Figure 9.4 Heart position - adult and child.](#)

[Figure 9.5 Diagrammatic representation of the blood flow through the heart....](#)

[Figure 9.6 The layers of the heart wall.](#)

[Figure 9.7 The electrical pathway through the heart.](#)

[Figure 9.8 The ECG tracing.](#)

[Figure 9.9 The blood pressure cuff.](#)

## Chapter 10

[Figure 10.1 An overview of the respiratory system and associated structures....](#)

[Figure 10.2 The airways of a child and an adult.](#)

[Figure 10.3 The nasopharynx, oropharynx and laryngopharynx, and the associat...](#)

[Figure 10.4 The trachea.](#)

[Figure 10.5 The alveoli.](#)

[Figure 10.6 The oxygen-haemoglobin dissociation curve.](#)

[Figure 10.7 The respiratory centre within the brain.](#)

[Figure 10.8 The mechanism of respiration.](#)

[Figure 10.9 Chest movement with inspiration and expiration.](#)

## Chapter 11

[Figure 11.1 The endocrine system.](#)

[Figure 11.2 The endocrine glands and hormones of the head and neck.](#)

[Figure 11.3 The parathyroid glands.](#)

[Figure 11.4 The thymus gland.](#)

[Figure 11.5 The adrenal glands.](#)

[Figure 11.6 The gastrointestinal system and its hormones.](#)

[Figure 11.7 The reproductive system and its hormones.](#)

## Chapter 12

[Figure 12.1 The structures associated with the digestion of food.](#)

[Figure 12.2 The blood supply to the gastrointestinal system.](#)

[Figure 12.3 Innervation of the digestive tract.](#)

[Figure 12.4 The oral cavity.](#)

[Figure 12.5 Primary dentition, or 'milk teeth'.](#)

[Figure 12.6 Secondary dentition, or permanent teeth.](#)

[Figure 12.7 Salivary gland positions in the mouth.](#)

[Figure 12.8 Diagram showing circular and longitudinal muscles in the digesti...](#)

[Figure 12.9 Peristalsis.](#)

[Figure 12.10 pH testing strips for nasogastric tube placement.](#)

[Figure 12.11 An overview of the small intestine.](#)

[Figure 12.12 Structure of a villus of the small intestine.](#)

[Figure 12.13 Position of the liver in relation to the gastrointestinal tract...](#)

[Figure 12.14 Position of the gallbladder and pancreas.](#)

[Figure 12.15 The large intestine.](#)

## Chapter 13

[Figure 13.1 The renal system - anterior view.](#)

[Figure 13.2 Gross anatomy of the kidney.](#)

[Figure 13.3 Internal anatomy of the kidney.](#)

[Figure 13.4 The nephron.](#)

[Figure 13.5 Blood supply to and from the kidneys.](#)

[Figure 13.6 The bladder - cross-section.](#)

[Figure 13.7 Female and male urethra.](#)

[Figure 13.8 Bladder control sensory pathway.](#)

## Chapter 14

[Figure 14.1 Development of internal genitalia.](#)

[Figure 14.2 Development of external genitalia.](#)

[Figure 14.3 Male reproductive system.](#)

[Figure 14.4 The Tanner scale for male genital growth.](#)

[Figure 14.5 Negative-feedback system associated with the control of testoste...](#)

[Figure 14.6 Male reproductive organs. \(a\) Posterior aspect of the longitudin...](#)

[Figure 14.7 Events in the transformation of a spermatid into a sperm cell....](#)

[Figure 14.8 Stages of spermatogenesis. \(a\) Transverse section of several sem...](#)

[Figure 14.9 Components of a sperm.](#)

[Figure 14.10 The female reproductive system \(sagittal section\) and surroundi...](#)

[Figure 14.11 The uterus and associated structures.](#)

[Figure 14.12 The developmental sequences associated with maturation of an ov...](#)

[Figure 14.13 Oogenesis and follicular development.](#)

[Figure 14.14 The ovarian and uterine cycles.](#)

[Figure 14.15 The female reproductive cycle: changes in anterior pituitary an...](#)

[Figure 14.16 Anatomy of the vagina.](#)

[Figure 14.17 The female external genitalia \(vulva\).](#)

[Figure 14.18 The breast.](#)

[Figure 14.19 The Tanner scale for female breast growth.](#)

## Chapter 15

[Figure 15.1 Organisation of the nervous system.](#)

[Figure 15.2 Motor neurone cell.](#)

[Figure 15.3 Neuroglia cell of the CNS.](#)

[Figure 15.4 Action potential.](#)

[Figure 15.5 Embryonic brain development.](#)

[Figure 15.6 Development of the brain and spinal cord. \(a\) Three-four-week em...](#)

[Figure 15.7 Circle of Willis.](#)

[Figure 15.8 Cerebral ventricles \(right lateral view\).](#)

[Figure 15.9 Anterior view of frontal section through the skull showing the c...](#)

[Figure 15.10 Structure of the brain.](#)

[Figure 15.11 Lateral view of the right cerebral hemisphere showing Brodmann'...](#)

[Figure 15.12 Anterior view of the spinal cord.](#)

[Figure 15.13 Functions of the cranial nerves. Blue indicates a sensory pathw...](#)

[Figure 15.14 The spinal cord and spinal nerves.](#)

[Figure 15.15 The spinal nerves and their areas of innervation.](#)

[Figure 15.16 A typical spinal nerve.](#)

[Figure 15.17 Sympathetic nervous system.](#)

[Figure 15.18 Parasympathetic nervous system.](#)

## Chapter 16

[Figure 16.1 Smooth muscle - cross-section.](#)

[Figure 16.2 Cardiac muscle.](#)

[Figure 16.3 The gross anatomy of striated skeletal muscle.](#)

[Figure 16.4 Micro-anatomy of skeletal muscle fibre.](#)

[Figure 16.5 Neuromuscular junction.](#)

[Figure 16.6 Origin and insertion.](#)

[Figure 16.7 Lateral view of the muscles of facial expression.](#)

[Figure 16.8 Anterior view of the muscles of facial expression.](#)

[Figure 16.9 Muscles of the neck.](#)

[Figure 16.10 The superficial muscles of the shoulder.](#)

[Figure 16.11 Rotator cuff muscles.](#)

[Figure 16.12 Anterior and posterior views of upper arm muscles.](#)

[Figure 16.13 Muscles of the forearm.](#)

[Figure 16.14 Muscles of breathing.](#)

[Figure 16.15 The abdominal muscles.](#)

[Figure 16.16 Muscles of the pelvis.](#)

[Figure 16.17 Muscles of the hip.](#)

[Figure 16.18 Anterior and posterior views of the muscles of the leg.](#)

[Figure 16.19 The muscles of the foot.](#)

## Chapter 17

[Figure 17.1 The axial and appendicular skeleton. \(a\) Anterior view. \(b\) Post...](#)

[Figure 17.2 Bone formation.](#)

[Figure 17.3 Intramembranous ossification.](#)

[Figure 17.4 Ossification of bone.](#)

[Figure 17.5 Bone growth and remodelling.](#)

[Figure 17.6 Ossification of the wrist.](#)

[Figure 17.7 Haversian canal.](#)

[Figure 17.8 Common types of fractures.](#)

[Figure 17.9 A long bone - femur.](#)

[Figure 17.10 The tarsal bones - short bone.](#)

[Figure 17.11 A flat bone - the sternum.](#)

[Figure 17.12 The vertebrae - an irregular bone.](#)

[Figure 17.13 The patella - a sesamoid bone.](#)

## Chapter 18



[Figure 18.1 Olfactory nerve pathway. \(a\) Sagittal view. \(b\) Enlarged aspect ...](#)

[Figure 18.2 Location and structures of tongue papillae and taste buds. \(a\) D...](#)

[Figure 18.3 The anatomy of the ear.](#)

[Figure 18.4 Properties of sound waves with different pitch and volume.](#)

[Figure 18.5 Cochlear anatomy.](#)

[Figure 18.6 Structure of a crista ampullaris. \(a\) Details of a crista. \(b\) P...](#)

[Figure 18.7a Anatomy of the eye.](#)

[Figure 18.7b Circular and radial muscles of the iris.](#)

[Figure 18.8 Refraction of light in the eye.](#)

[Figure 18.9 Anatomy of the optic nerve.](#)

[Figure 18.10 Optic chiasma.](#)

## Chapter 19

[Figure 19.1 The cells of the epidermis.](#)

[Figure 19.2 The layers of the epidermis.](#)

[Figure 19.3 The structures of the dermis.](#)

[Figure 19.4 The nail.](#)

[Figure 19.5 The hair follicle.](#)

[Figure 19.6 Heat loss from a newborn baby.](#)

[Figure 19.7 Implication of cold stress on an infant.](#)

To those children, young people, nurses and other health  
and social care staff who have lost their lives as a result of  
COVID-19.

# **Fundamentals of Children and Young People's Anatomy and Physiology**

# **A Textbook for Nursing and Healthcare Students**

SECOND EDITION

EDITED BY

**IAN PEATE**

**Principal, School of Health Studies, Gibraltar Health Authority, Gibraltar; Visiting Professor, St George's University of London, Kingston University London and Northumbria University; Visiting Senior Clinical Fellow, University of Hertfordshire; Editor in Chief of the *British Journal of Nursing***

AND

**ELIZABETH GORMLEY-FLEMING**

**Associate Director, Academic Quality Assurance, Centre for Academic Quality Assurance, University of Hertfordshire, Hatfield, United Kingdom**

**WILEY Blackwell**

This edition first published 2021  
© 2021 John Wiley & Sons Ltd

*Edition History*

Wiley-Blackwell (1e, 2015)

All rights reserved. No part of this publication may be reproduced, stored in a retrieval system or transmitted, in any form or by any means, electronic, mechanical, photocopying, recording or otherwise, except as permitted by law. Advice on how to obtain permission to reuse material from this title is available at <http://www.wiley.com/go/permissions>.

The right of Ian Peate and Elizabeth Gormley-Fleming to be identified as the authors of the editorial material in this work has been asserted in accordance with law.

*Registered Office(s)*

John Wiley & Sons, Inc., 111 River Street, Hoboken, NJ 07030, USA

John Wiley & Sons Ltd, The Atrium, Southern Gate, Chichester, West Sussex, PO19 8SQ, UK

*Editorial Office*

9600 Garsington Road, Oxford, OX4 2DQ, UK

For details of our global editorial offices, customer services, and more information about Wiley products, visit us at [www.wiley.com](http://www.wiley.com).

Wiley also publishes its books in a variety of electronic formats and by print-on-demand. Some content that appears in standard print versions of this book may not be available in other formats.

*Limit of Liability/Disclaimer of Warranty*

The contents of this work are intended to further general scientific research, understanding and discussion only, and are not intended and should not be relied upon as recommending or promoting scientific method, diagnosis or treatment by physicians for any particular patient. In view of ongoing research, equipment modifications, changes in governmental regulations and the constant flow of information relating to the use of medicines, equipment and devices, the reader is urged to review and evaluate the information provided in the package insert or instructions for each medicine, equipment or device for, among other things, any changes in the instructions or indication of usage and for added warnings and precautions. While the publisher and authors have used their best efforts in preparing this work, they make no representations or warranties with respect to the accuracy or completeness of the contents of this work and specifically disclaim all warranties, including without limitation any implied warranties of merchantability or fitness for a particular purpose. No warranty may be created or extended by sales representatives, written sales materials or promotional statements for this work. The fact that an organisation, website or product is referred to in this work as a citation and/or potential source of further information does not mean that the publisher and authors endorse the information or services the organisation, website or

product may provide or recommendations it may make. This work is sold with the understanding that the publisher is not engaged in rendering professional services. The advice and strategies contained herein may not be suitable for your situation. You should consult with a specialist where appropriate. Further, readers should be aware that websites listed in this work may have changed or disappeared between when this work was written and when it is read. Neither the publisher nor authors shall be liable for any loss of profit or any other commercial damages, including but not limited to special, incidental, consequential or other damages.

*Library of Congress Cataloging-in-Publication Data*

Names: Peate, Ian, editor. | Gormley-Fleming, Elizabeth, editor.

Title: Fundamentals of children and young people's anatomy and physiology : a textbook for nursing and healthcare students / edited by Ian Peate, Elizabeth Gormley-Fleming.

Other titles: Fundamentals of children's anatomy and physiology

Description: Second edition. | Hoboken, NJ : Wiley-Blackwell, 2021. | Preceded by Fundamentals of children's anatomy and physiology / edited by Ian Peate and Elizabeth Gormley-Fleming. 2015. | Includes bibliographical references and index.

Identifiers: LCCN 2020030569 (print) | LCCN 2020030570 (ebook) | ISBN 9781119619222 (paperback) | ISBN 9781119619284 (adobe PDF) | ISBN 9781119619246 (ePUB)

Subjects: MESH: Anatomy | Physiological Phenomena | Child | Adolescent

Classification: LCC RJ125 (print) | LCC RJ125 (ebook) | NLM QS 4 | DDC 612.0083-dc23

LC record available at <https://lcn.loc.gov/2020030569>

LC ebook record available at <https://lcn.loc.gov/2020030570>

Cover Design: Wiley

Cover Image: © Jose Luis Pelaez Inc/Getty Images