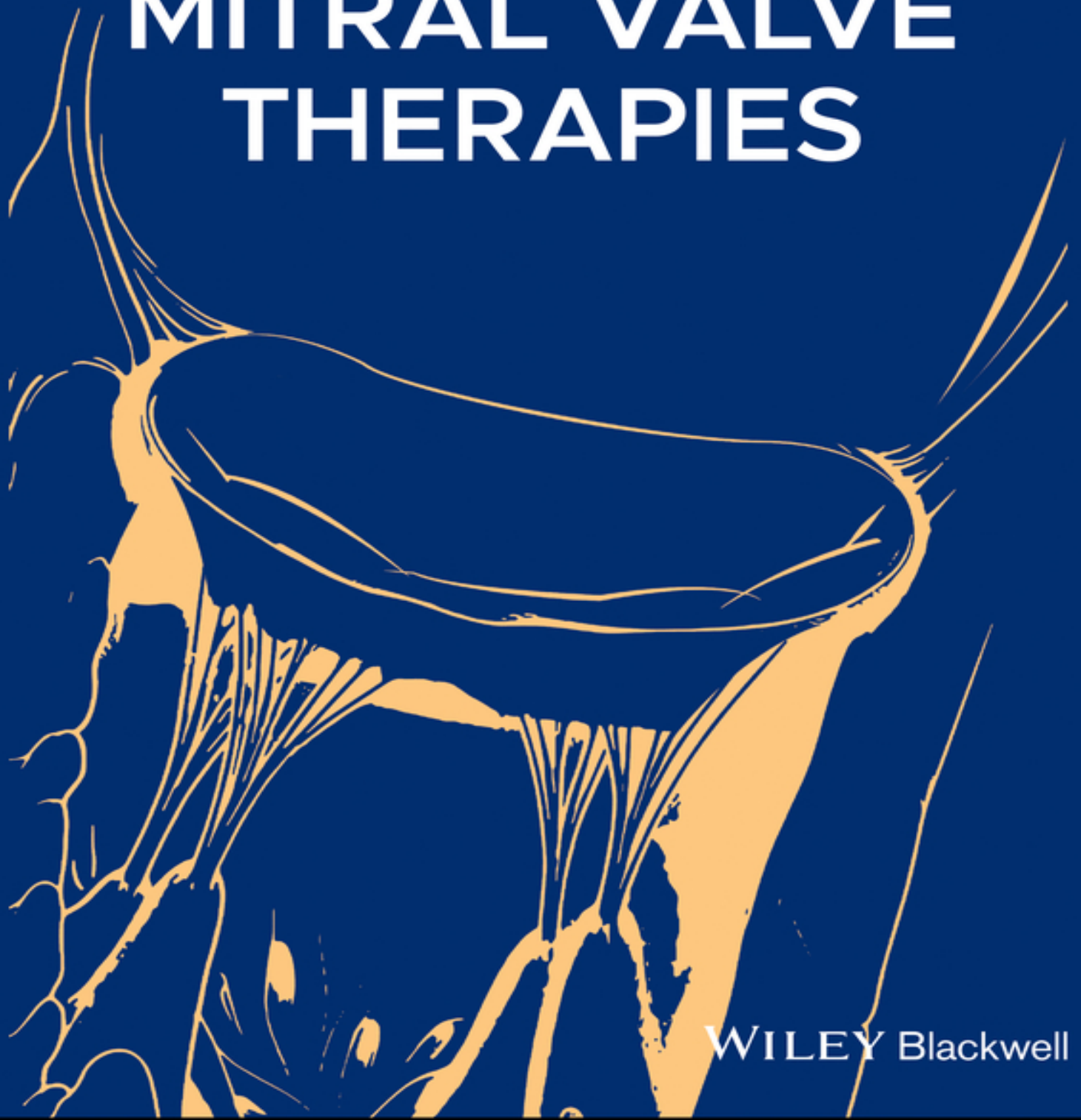


EDITED BY
RON WAKSMAN | TOBY ROGERS

TRANSCATHETER MITRAL VALVE THERAPIES



WILEY Blackwell

Table of Contents

[Cover](#)

[Title Page](#)

[Copyright Page](#)

[List of Contributors](#)

[Introduction—The Mitral Book](#)

[1 The Pathology of Mitral Valve Disease](#)

[1.1 Introduction](#)

[1.2 General Anatomy of the Mitral Valve](#)

[1.3 Pathology of Mitral Valve](#)

[References](#)

[2 The Importance of Minimally Invasive Approaches for Mitral Valve Repair](#)

[2.1 Introduction to Minimally Invasive Mitral Valve Surgery](#)

[2.2 The Importance of MICS MVS](#)

[2.3 Patient Selection](#)

[2.4 Surgical Setup—Fibrillating Heart MVS](#)

[2.5 Alternatives for Cannulation](#)

[2.6 Alternatives to Myocardial Protection](#)

[2.7 Mitral Valve Repair](#)

[2.8 Outcomes](#)

[2.9 Initiating Minimally Invasive Mitral Valve Repair Program](#)

[2.10 Conclusion](#)

[References](#)

3 When to Intervene—Should Surgical Guidelines Apply to Transcatheter Techniques in Treating Mitral Regurgitation?

3.1 Introduction

3.2 Primary MR

3.3 Secondary MR

3.4 Conclusions

References

4 Transcatheter Mitral Valve Therapies

4.1 Introduction

4.2 Conclusions

References

5 CMR Assessment of Mitral Regurgitation

5.1 Introduction

5.2 Pulse Sequences Used in CMR

5.3 Assessment of MR Severity

5.4 Identification of MR Etiology

5.5 The Role of CMR Assessment of MR in Clinical Practice

5.6 Conclusions

References

6 CT Planning for TMVR and Predicting LVOT Obstruction

6.1 Introduction

6.2 History of Imaging for Mitral Valve Disease

6.3 Concept of Aortic and Mitral Valve Technology Development

6.4 Basics of CT Imaging Acquisition

6.5 Definition of Mitral Valve and TMVR device Landing Zone

[6.6 Definition of LVOT](#)

[6.8 CT Validation of Neo-LVOT Prediction Modeling Post-TMVR](#)

[6.9 Correlation Between Pre- and Post-TMVR CT Neo-LVOT Prediction Modeling](#)

[6.10 What Else Has CT Planning for TMVR Taught Us?](#)

[Acknowledgments](#)

[References](#)

[7 General Principles and State-of-the-Art Echocardiographic Evaluation of the Mitral Valve](#)

[7.1 Introduction](#)

[7.2 Mechanism and Etiology of Chronic MR](#)

[7.3 Continuous Wave \(CW\) Density Jet](#)

[7.4 Pulmonary Vein Flow/Mitral Inflow](#)

[7.5 Selection of Best Candidates for Interventions of the Mitral Valve](#)

[References](#)

[8 Intraprocedural Echocardiography for MitraClip](#)

[8.1 Introduction](#)

[8.2 Pre-Procedure Evaluation](#)

[8.3 Importance of the Baseline Study – TEE](#)

[8.4 The Transseptal Puncture](#)

[8.5 Guiding MitraClip System to Mitral Valve](#)

[8.6 Intraprocedural Guidance of Clip within Mitral Valve and Leaflets](#)

[8.7 Post-Clip-Deployment Assessment of Mitral Valve Function](#)

[8.8 Assessment of Complications and Iatrogenic ASD](#)

References

9 Intraprocedural Echocardiography for Transcatheter Mitral Valve Replacement

9.1 Introduction

9.2 Baseline Mitral Valve Assessment

9.3 Access to the Left Atrium, Left Ventricle, and Mitral Valve

9.4 Predeployment and Deployment Monitoring

9.5 Postdeployment Evaluation

References

10 Transcatheter Repair

10.1 Surgery for Degenerative Mitral Regurgitation

10.2 Evidence Base for MitraClip

10.3 Challenges for the MitraClip Procedure

10.4 Evaluation of MitraClip for Less than Prohibitive-Risk DMR Patients

10.5 Future Directions for MitraClip and Alternative Approaches for Leaflet Repair

10.6 Summary

References

11 MitraClip[™] for Secondary Mitral Regurgitation

11.1 Introduction

11.2 European and US Clinical Practice Guidelines

11.3 The MitraClip System

11.4 MitraClip Preprocedural Planning

11.5 Surgical Outcomes Data

11.6 The COAPT and MITRA-FR Trials

11.7 Summary and Conclusions

References

12 The Edwards PASCAL Transcatheter Valve Repair System

12.1 Introduction

12.2 The Edwards PASCAL™ Transcatheter Valve Repair System

12.3 Implantation Procedure

12.4 Compassionate-Use and Early Feasibility Data

12.5 Future Developments

References

13 The Development of a Novel Percutaneous Treatment for Secondary Mitral Regurgitation—The Carillon® Mitral Contour System®

13.1 Introduction

13.2 REDUCE-FMR

13.3 The CARILLON Trial

13.4 Summary

References

14 A Fully Percutaneous Mitral Ring

14.1 Introduction

14.2 Mitral Annulus Anatomy

14.3 Pathophysiological Role of the Mitral Annulus in Mitral Regurgitation

14.4 Surgical Annuloplasty in Mitral Regurgitation

14.5 The Cardioband System: Description of the Device

14.6 Procedural Planning

14.7 Clinical Studies

14.8 Possible Complications Related to the Implantation of Cardioband

[14.9 Recurrence of Mitral Regurgitation Following Cardioband Implantation](#)

[14.10 Cardioband in Combination with Other Devices](#)

[14.11 Conclusions](#)

[References](#)

[15 Transcatheter Mitral Cerclage Annuloplasty](#)

[15.1 Introduction](#)

[15.2 Cerclage Anatomy and Function](#)

[15.3 Limitations of Coronary Sinus Annuloplasty](#)

[15.4 Cerclage Annuloplasty Device](#)

[15.5 The Cerclage Procedure](#)

[15.6 Preclinical Experiments](#)

[15.7 Initial Human Experience](#)

[15.8 Future Directions](#)

[15.9 Summary](#)

[Competing Interests](#)

[References](#)

[16 The Transapical Off-Pump Mitral Valve Repair with the NeoChord Implantation \(TOP-MINI\)](#)

[16.1 Introduction](#)

[16.2 Technology](#)

[16.3 Patient Selection](#)

[16.4 Procedure](#)

[16.5 Echocardiographic Guidance](#)

[16.6 Examples](#)

[16.7 Conclusion](#)

[References](#)

17 AltaValve™—A Transcatheter Mitral Valve Regurgitation Treatment Technology

17.1 Clinical Need

17.2 Device Description

17.3 Anatomical Imaging and Sizing

17.4 Preclinical and Clinical Experience

17.5 Human Clinical Experience

17.6 Summary

References

18 The ARTO Transcatheter Mitral Valve Repair System

18.1 Device Description

18.2 Procedural Details

18.3 Clinical Experience with the ARTO System

18.4 Unique Features of the ARTO System

References

19 Transcatheter Mitral Annuloplasty

19.1 Background

19.2 The Millipede Device

19.3 Millipede Implantation Procedure

19.4 Surgical Millipede Implants

19.5 Millipede Clinical Results

19.6 Clinical Implications

19.7 Summary

Author Disclosures

References

20 Transapical and Transseptal Access for Transcatheter Mitral Valve Replacement

20.1 Introduction

20.2 Transapical Approach

[20.3 Transseptal Approach](#)

[20.4 Conclusions](#)

[References](#)

[21 Mitral Valve-in-Valve and Valve-in-Ring Therapies](#)

[21.1 Overview](#)

[21.2 Evidence](#)

[21.3 Procedure Planning](#)

[21.4 Procedure](#)

[21.5 Pitfalls and Solutions—POULEZ and LAMPOON](#)

[References](#)

[22 Edwards SAPIEN in Native Mitral Annular Calcification \(MAC\)](#)

[22.1 Introduction](#)

[22.2 Anatomic Considerations and Sizing](#)

[22.3 Delivery Access Types](#)

[22.4 Preprocedural Planning](#)

[22.5 Valve Deployment Technique](#)

[22.6 Clinical Outcomes and Complications](#)

[22.7 LVOT Obstruction](#)

[22.8 TMVR in MAC Clinical Trials](#)

[22.9 Aortic THV versus Dedicated TMVR Devices for MAC](#)

[22.10 Conclusions](#)

[Disclosures](#)

[References](#)

[23 Transcatheter Mitral Valve Replacement](#)

[23.1 Introduction](#)

[23.2 The Tendyne TMVI Device](#)

[23.3 Patient Screening and Preprocedural Imaging](#)

[23.4 Implantation Technique](#)

[23.5 Clinical Outcomes](#)

[23.6 Future Challenges](#)

[23.7 Conclusion](#)

[References](#)

[24 TIARA Transcatheter Mitral Replacement System](#)

[24.1 Introduction](#)

[24.2 Neovasc TIARA TMVR System](#)

[24.3 Candidacy for TIARA TMVR](#)

[24.4 Clinical Case and TIARA TMVR Implantation](#)

[24.5 Clinical Updates](#)

[24.6 Conclusions](#)

[Conflict of Interest](#)

[References](#)

[25 Caisson Transcatheter Mitral Valve Replacement System](#)

[25.1 Introduction](#)

[25.2 Caisson Transcatheter Mitral Valve Replacement System Components](#)

[25.3 Procedural Details](#)

[25.4 Current Status of the Caisson Research Program](#)

[25.5 Conclusions](#)

[Reference](#)

[26 Transcatheter Mitral Valve Replacement with the CardiAQ-Edwards and EVOQUE Prostheses](#)

[26.1 Introduction](#)

[26.2 Device Description](#)

[26.3 First-in-Human Transfemoral Case](#)

[26.4 Initial Experience via Transapical Approach](#)

[26.5 Second-Generation Transseptal Approach](#)

[26.6 Current CardiAQ Generation Design and Contemporary Case Example](#)

[26.7 Discussion](#)

[References](#)

[27 Intrepid](#)

[27.1 Background](#)

[27.2 The Intrepid Valve Features](#)

[27.3 Clinical Experience](#)

[27.4 Discussion](#)

[References](#)

[28 Laceration of the Anterior Mitral Leaflet to Prevent Outflow Obstruction \(LAMPOON\)](#)

[28.1 Introduction](#)

[28.2 The LAMPOON Technique](#)

[28.3 Alternative LAMPOON Techniques](#)

[28.4 Evidence for LAMPOON-Assisted TMVR](#)

[28.5 Future Directions](#)

[28.6 Conclusions](#)

[References](#)

[29 Use of Alcohol Septal Reduction Therapy to Facilitate Transcatheter Mitral Valve Replacement](#)

[29.1 Introduction](#)

[29.2 Technique](#)

[29.3 Safety](#)

[29.4 Efficacy](#)

[29.5 Conclusion](#)

References

30 Direct Transatrial Approach with Resection of the Anterior Mitral Leaflet to Prevent Outflow Tract Obstruction

30.1 Introduction

30.2 Advantages of the Direct Transatrial Access

30.3 Patients Selection and THV Sizing

30.4 Implantation Techniques

30.5 Surgical Access

30.6 Early Outcomes Data

30.7 Conclusions

References

31 Transcatheter Closure of Mitral Paravalvular Leak

31.1 Introduction

31.2 Prevalence and Clinical Presentation

31.3 Assessment of Mitral PVL

31.4 Timing of Intervention

31.5 Preplanning

31.6 Devices Used for PVL Closure

31.7 Procedural Complications

31.8 Follow-Up

31.9 Future

31.10 Conclusion

Disclosures

References

32 Management of Iatrogenic Interatrial Septal Defect —To Close or not to Close?

32.1 Introduction

32.2 Hemodynamics and iASDs

[32.3 Incidence of Persistent Iatrogenic Atrial Septal Defects](#)

[32.4 Evaluation of Iatrogenic Atrial Septal Defect](#)

[32.5 Closure](#)

[32.6 ASD Closure Procedure](#)

[32.7 Management](#)

[References](#)

[33 Antithrombotic Therapy in Transcatheter Mitral Valve Intervention](#)

[33.1 Introduction](#)

[33.2 MitraClip System](#)

[33.3 Transcatheter Mitral Valve Replacement](#)

[33.4 Patients with Atrial Fibrillation](#)

[33.5 Antithrombotic Therapy for Other Mitral Valve Interventions](#)

[33.6 Conclusions](#)

[References](#)

[Index](#)

[End User License Agreement](#)

List of Tables

Chapter 1

[Table 1.1 Classification of the mitral valve disease.](#)

[Table 1.2 Key differences between Barlow's disease and fibroelastic deficiency...](#)

Chapter 2

[Table 2.1 Relative contraindications to minimally invasive mitral valve surgery...](#)

[Table 2.2 Variations of minimally invasive mitral valve repair.](#)

Chapter 3

[Table 3.1 2017 AHA/ACC and ESC mitral valve intervention guidelines for prima...](#)

[Table 3.2 Current and emerging transcatheter therapies for treating MR.](#)

[Table 3.3 2017 AHA/ACC and ESC mitral valve intervention guidelines for secon...](#)

Chapter 4

[Table 4.1 Morphological characteristics for MitraClip eligibility.](#)

Chapter 7

[Table 7.1 Grading the severity of chronic MR by echocardiography.](#)

[Table 7.2 Grading the severity of MR.](#)

Chapter 8

[Table 8.1a TEE parameters useful in determining residual MR severity after Mi...](#)

[Table 8.1b Echocardiographic and Doppler parameters for grading MR severity b...](#)

Chapter 10

[Table 10.1 Intervention for chronic primary MR.](#)

[Table 10.2 Morphology for a MitraClip therapy.](#)

[Table 10.3 Idealized indications for the MitraClip therapy.](#)

Chapter 11

[Table 11.1 Potential reasons for differences in results of MITRA-FR and COAPT...](#)

Chapter 17

[Table 17.1 Materials used in the construction of the AltaValve.](#)

Chapter 18

[Table 18.1 MAVERIC Phase I: cumulative major adverse events to 3-year follow-...](#)

[Table 18.2 Echocardiographic outcomes.](#)

Chapter 20

[Table 20.1 Transcatheter mitral valve replacement devices in early feasibilit...](#)

Chapter 21

[Table 21.1 Baseline characteristics of TMVR procedures.](#)

[Table 21.2 Outcomes of TMVR studies.](#)

[Table 21.3 Information needed about previous surgery.](#)

[Table 21.4 Spectrum of imaging for TMVR.](#)

Chapter 23

[Table 23.1 Clinical events in follow-up after 1 year in 100 patients.](#)

Chapter 27

[Table 27.1 The implant procedure.](#)

[Table 27.2 Patient characteristics \(\$N = 50\$ \).](#)

[Table 27.3 Procedural data.](#)

[Table 27.4 Early and late adverse events.](#)

Chapter 29

[Table 29.1 Representative single-center and multicenter registries of percuta...](#)

Chapter 30

[Table 30.1 Comparison between the different approaches to the mitral valve fo...](#)

Chapter 31

[Table 31.1 Summary of echocardiographic criteria for mitral prosthetic PVL.](#)

[Table 31.2 Devices used for PVL closure.](#)

[Table 31.3 Complications of PVL closure.](#)

Chapter 33

[Table 33.1 Risk stratification for periprocedural bridging anticoagulation.](#)

List of Illustrations

Chapter 1

[Figure 1.1 Normal mitral valve. \(a\) Gross atrial view of the mitral valve sh...](#)

[Figure 1.2 Long axis view of the heart demonstrating the fibrous continuity ...](#)

[Figure 1.3 Adjoining structure around the mitral valve. Superior view of the...](#)

[Figure 1.4 Fibrous continuity of the anterior mitral leaflet with the aortic...](#)

[Figure 1.5 Severe mitral annular calcification. The classification of the ex...](#)

[Figure 1.6 Degenerative mitral valve prolapse. A young female with no known ...](#)

[Figure 1.7 Short-axis view of the interventricular septum and papillary musc...](#)

Chapter 2

[Figure 2.1 Our experience with minimally invasive mitral valve repair strate...](#)

[Figure 2.2 Minimally invasive mitral valve repair using direct vision. \(a\) S...](#)

Chapter 4

[Figure 4.1 3D geometric analysis of the mitral apparatus demonstrating the “...](#)

[Figure 4.2 We found that the true proximal flow convergence region \(PFCR\) co...](#)

[Figure 4.3 Although we can measure the direct VC, the more important target,...](#)

[Figure 4.4 3D zoom en face images of the mitral valve seen from the left atr...](#)

[Figure 4.5 3D use in determining echocardiographic suitability criteria for ...](#)

[Figure 4.6 Atrial septum crossing. \(a\) Tenting of the interatrial septum in ...](#)

[Figure 4.7 Mitral clip positioning and adjustment predeployment. \(a\) MC with...](#)

[Figure 4.8 3D zoom of the mitral valve from the left atrial aspect showing t...](#)

Chapter 5

[Figure 5.1 Left and right ventricular short-axis stack acquired using balanc...](#)

[Figure 5.2 Segmented magnitude \(top panel\) and phase contrast \(bottom panel\)...](#)

Chapter 6

[Figure 6.1 TAVR stent technology. TAVR valves are built upon the concept of ...](#)

[Figure 6.2 Mitral in systole and diastole. Note the change in the medial to ...](#)

[Figure 6.3 Definition of neo-LVOT in TMVR. In the TMVR space, the neo LVOT i...](#)

[Figure 6.4 Cardiac CT phase selection. Rows A, B, and C demonstrate three di...](#)

[Figure 6.5 Method behind LVOT prediction modeling algorithm. Once the size o...](#)

[Figure 6.6 Post-TMVR tilts. Note that in the absence of a steerable TMVR del...](#)

[Figure 6.7 Different TMVR needs based on mitral pathology. \(a\) Patient with ...](#)

[Figure 6.8 Distribution of MAC \(Mitral Annulus Calcification\). \(a\) CT-genera...](#)

[Figure 6.9 Path of least resistance. On the left panel, 3D surgeon's view of...](#)

Chapter 7

[Figure 7.1 Carpentier's classification of mitral regurgitation. \(a\) Normal m...](#)

[Figure 7.2 Algorithm for distinguishing primary from secondary mitral regurg...](#)

[Figure 7.3 Two examples of color-flow Doppler to assess mitral regurgitation...](#)

[Figure 7.4 Continuous wave \(CW\) of mitral regurgitation. A dense jet is note...](#)

[Figure 7.5 Vena contracta of a significant mitral regurgitation jet. Of note...](#)

[Figure 7.6 Flow reversal in the left superior pulmonary vein \(arrows\)](#)

[Figure 7.7 Proximal isovelocity surface area allows quantification of mitral...](#)

[Figure 7.8 COAPT trial echocardiographic inclusion criteria flow chart.](#)

Chapter 8

[Figure 8.1 The heart team approach and the critical role of the imager/echoc...](#)

[Figure 8.2 3D multiplanar reconstruction planimetry of \(a\) mitral valve area...](#)

[Figure 8.3 Direct 3D planimetry to estimate mitral valve area from the \(a\) l...](#)

[Figure 8.4 2D spectral continuous-wave Doppler to estimate mitral inflow gra...](#)

[Figure 8.5 Mid-esophageal four-chamber view: \(a\) 2D and \(b\) 2D color Doppler...](#)

[Figure 8.6 2D assessment of mitral valve scallops using TEE.](#)

[Figure 8.7 TEE maneuvers and imaging positions.](#)

[Figure 8.8 \(a\) 2D and \(b\) 2D color Doppler TEE intercommissural view to dete...](#)

[Figure 8.9 \(a\) 2D and \(b\) color Doppler TEE long-axis view of the mitral val...](#)

[Figure 8.10 Methods for acquiring and presenting 3D TEE dataset of mitral va...](#)

[Figure 8.11 Initial Acquisition of TEE \(a\) 3D dataset and \(b\) the important ...](#)

[Figure 8.12 3D TEE assessment of mitral valve with \(a\) simultaneous presenta...](#)

[Figure 8.13 3D Color Doppler assessment of mitral regurgitation. \(a\) 3D colo...](#)

[Figure 8.14 Determine whether mitral regurgitation is \(a\) degenerative/organ...](#)

[Figure 8.15 Critical echocardiographic criteria to determine suitable anatom...](#)

[Figure 8.16 \(A\) Assessment of functional MR should include \(i\) zone of coapt...](#)

[Figure 8.17 Assessment of mitral valve area using 3D multiplanar reconstruct...](#)

[Figure 8.18 Estimating mitral valve area using direct 3D planimetry from the...](#)

[Figure 8.19 Assessing severity of mitral regurgitation using the proximal is...](#)

[Figure 8.20 Assessing baseline mitral valve inflow Doppler velocities, gradi...](#)

[Figure 8.21 Echocardiographic assessment of pulmonary veins. \(A\) 2D color Do...](#)

[Figure 8.22 Assessing severity of mitral regurgitation using 3D color Dopple...](#)

[Figure 8.23 Real-time imaging of the interatrial septum at the time of trans...](#)

[Figure 8.24 Evaluation of the left atrial appendage using multiple views to ...](#)

[Figure 8.25 Assessing height above mitral valve annulus at time of transsept...](#)

[Figure 8.26 Echocardiographic Guidance for Transseptal Puncture. \(A\) Superio...](#)

[Figure 8.27 Positioning guidewire in the left upper pulmonary vein. \(A\) Conf...](#)

[Figure 8.28 The importance of demonstrating the position of guidewires, cath...](#)

[Figure 8.29 Visualizing the guide catheter in the left atrium.](#)

[Figure 8.30 Real-time X-plane \(bi-plane\) TEE imaging to track position of Cl...](#)

[Figure 8.31 Using X-plane \(bi-plane\) TEE imaging to advance clip to the mitr...](#)

[Figure 8.32 Positioning and deploying MitraClip. \(A\) Positioning MitraClip b...](#)

[Figure 8.33 Assessment of residual mitral regurgitation post-MitraClip deplo...](#)

[Figure 8.34 Additional post-MitraClip-deployment assessment. \(A\) Assessment ...](#)

[Figure 8.35 Assessment of iatrogenic ASD using \(a\) 2D color Doppler imaging ...](#)

Chapter 9

[Figure 9.1 \(a\) This 3D color Doppler demonstrates severe mitral regurgitatio...](#)

[Figure 9.2 This demonstrates the process of the transseptal puncture. \(a\) Th...](#)

[Figure 9.3 If the transcatheter heart valve requires a transapical approach,...](#)

[Figure 9.4 Evaluation and implantation of a transcatheter heart valve in a p...](#)

[Figure 9.5 Example of surgical mitral valve failure with severe prosthetic m...](#)

[Figure 9.6 In situations when transseptal approach is needed for TMVR, the a...](#)

Chapter 10

[Figure 10.1 A case example of MitraClip for degenerative mitral regurgitatio...](#)

[Figure 10.2 This transesophageal echocardiographic frame shows the transsept...](#)

[Figure 10.3 Fluoroscopic images showing the sequence of MitraClip implantati...](#)

[Figure 10.4 The upper left panel \(a\) shows a three-dimensional echo image of...](#)

[Figure 10.5 The short axis \(SAX\) and long axis \(LAX\) show the small residual...](#)

[Figure 10.6 PASCAL CLASP device has two paddles and a central spacer. The pa...](#)

Chapter 11

[Figure 11.1 Primary effectiveness and safety end points and death in the COA...](#)

Chapter 12

[Figure 12.1 The PASCAL repair system. \(a\) The fully assembled delivery syste...](#)

[Figure 12.2 Fluoroscopic views and schematic step-by-step depiction of the i...](#)

[Figure 12.3 Transesophageal echocardiographic images of a patient with sever...](#)

[Figure 12.4 Compassionate-use outcomes after 30 days and 6 months. \(a\) NYHA ...](#)

[Figure 12.5 The PASCAL repair system 30-day outcomes of compassionate use \(N](#)

Chapter 13

[Figure 13.1 The Carillon Mitral Contour System is shown superimposed next to...](#)

[Figure 13.2 The delivery system of the Carillon Mitral Contour System is com...](#)

[Figure 13.3 Color Doppler in a four-chamber view of a baseline echocardiogra...](#)

Chapter 14

[Figure 14.1 The Cardioband ring_\(a\) before and \(b\) after implantation. The i...](#)

[Figure 14.2 Computed tomography \(CT\) scan planning: \(a\) The CT scan helps to...](#)

[Figure 14.3 \(a\) A case example of Cardioband implantation in a patient with ...](#)

[Figure 14.4 A case of severe spasm of the circumflex artery following the im...](#)

[Figure 14.5 A possible algorithm to evaluate recurrence of mitral regurgitat...](#)

Chapter 15

[Figure 15.1 The cerclage trajectory. The loop passes through the coronary si...](#)

[Figure 15.2 Anatomical relationships of the great cardiac vein and circumfle...](#)

[Figure 15.3 Anatomical relationship between the plane of the mitral annulus ...](#)

[Figure 15.4 \(a\) Cerclage annuloplasty device consists of coronary sinus loop...](#)

[Figure 15.5 Key steps in the cerclage procedure. RIJ = right internal jugula...](#)

[Figure 15.6 \(a\) and \(b\) Measurements of regurgitant fraction and regurgitati...](#)

[Figure 15.7 \(a\) and \(b\) PA chest X-ray pre and at 6 months post annuloplasty...](#)

[Figure 15.8 CT-derived volumes of the left-sided cardiac chambers at baselin...](#)

[Figure 15.9 Potential procedures enabled through mitral cerclage techniques....](#)

Chapter 16

[Figure 16.1 This figure illustrates the NeoChord DS1000 system \(NeoChord, In...](#)

[Figure 16.2 Illustration of echocardiographic features of ideal anatomy for ...](#)

[Figure 16.3 Illustration of echocardiographic features of an acceptable anat...](#)

[Figure 16.4 Illustration of echocardiographic features of a challenging anat...](#)

[Figure 16.5 Illustration of advancement of the NeoChord device \(NeoChord, In...](#)

[Figure 16.6 Illustration of moving the Neochord device \(NeoChord, Inc., St. ...](#)

[Figure 16.7 Schematic demonstration of P2 grasping by the NeoChord device \(N...](#)

[Figure 16.8 Schematic demonstration of P2 grasping by the NeoChord device \(N...](#)

[Figure 16.9 Schematic demonstration of P2 perforation and Neochord \(NeoChord...](#)

[Figure 16.10 Schematic demonstration of Neochord \(NeoChord, Inc., St. Louis ...](#)

[Figure 16.11 Transesophageal echocardiography demonstrating before and after...](#)

[Figure 16.12 Transesophageal echocardiography demonstrating before and after...](#)

[Figure 16.13 Transesophageal echocardiography demonstrating before and after...](#)

Chapter 17

[Figure 17.1 Simplified diagram representing the left side of the human heart...](#)

[Figure 17.2 Left: Conventional TMVR device deploys in the mitral valve annul...](#)

[Figure 17.3 Isometric view of AltaValve depicts the tissue valve in the clos...](#)

[Figure 17.4 A highlight of the varying sections of the single-piece stent—ou...](#)

[Figure 17.5 Sizing measurements and recommendations for AltaValve procedural...](#)

[Figure 17.6 A cross-sectional view of the left atrium with the native mitral...](#)

[Figure 17.7 CT images of the AltaValve in a porcine model following explanta...](#)

[Figure 17.8 Left: Segmentation of the AltaValve from CT scan obtained at 6 d...](#)

Chapter 18

[Figure 18.1 The ARTO System in position.](#)

[Figure 18.2 The ARTO System.](#)

[Figure 18.3 The ARTO System deployment. \(a\) Great cardiac vein \(GCV\) and lef...](#)

[Figure 18.4 ARTO case example \[4\]. \(a\) Baseline four-chamber transthoracic e...](#)

[Figure 18.5 \(a\) MAVERIC Phase IMR reduction at 30 days maintained at 3 years...](#)

Chapter 19

[Figure 19.1 The transcatheter Millipede device. The Millipede device consist...](#)

[Figure 19.2 The transcatheter Millipede procedure. First, the ring is placed...](#)

[Figure 19.3 Surgical Millipede ring. The surgical Millipede ring_\(left\), and...](#)

[Figure 19.4 Transcatheter Millipede ring. \(a\) Preprocedure transthoracic ech...](#)

[Figure 19.5 Reduction in septal-lateral dimension. Phase 1, surgical implant...](#)

[Figure 19.6 Mitral regurgitation grade. Phase 1, surgical implants. Phase 2,...](#)

[Figure 19.7 New York Heart Association \(NYHA\) Functional Classification....](#)

[Figure 19.8 Reduction in left ventricular volume. Phase 1, surgical implants...](#)

Chapter 20

[Figure 20.1 Transapical approach. A soft tissue retractor \(a\) without and \(b...](#)

[Figure 20.2 Measurement of the height of the transseptal crossing above the ...](#)

[Figure 20.3 The Baylis radiofrequency needle system allows precise crossing...](#)

Chapter 21

[Figure 21.1 Prevalence of valvular disease..](#)

[Figure 21.2 Transcatheter mitral valve replacement. \(a\) Transcatheter mitral...](#)

[Figure 21.3 Preprocedural CT planning. \(a\) True inner diameter of surgical b...](#)

[Figure 21.4 LAMPOON. \(a\) Mechanism of LVOT obstruction. \(b\) Comparison of an...](#)

Chapter 22

[Figure 22.1 Mitral annulus measurements. Cardiac computed-tomography-based m...](#)

[Figure 22.2 Landing zone. Fluoroscopy simulation of valve deployment angle u...](#)

[Figure 22.3 LVOT assessment. \(a\) Measurement of the left ventricular outflow...](#)

[Figure 22.4 Valve-in-MAC 30-day mortality.](#)

Chapter 23

[Figure 23.1 The Tendyne device. \(a\) The Tendyne bioprosthetic mitral valve s...](#)

[Figure 23.2 Periprocedural transesophageal echo planning. \(A\) 3D en face vie...](#)

[Figure 23.3 Periprocedural multislice CT planning and device simulation. \(A\)...](#)

[Figure 23.4 Transapical access routes and table angles. Once the Tendyne dev...](#)

[Figure 23.5 Tendyne procedure. \(A\) The apical access site is confirmed on X-...](#)

[Figure 23.6 Final device deployment. \(A\) Correct 3D en face Tendyne final po...](#)

[Figure 23.7 Echo outcome after Tendyne at 30 days. There was significant red...](#)

[Figure 23.8 Clinical outcome 1-year after Tendyne. \(A\) NYHA Classification d...](#)

Chapter 24

[Figure 24.1 The Neovasc TIARA TMVR valve prosthesis.](#)

[Figure 24.2 \(a\) Mitral annular perimeter and area measurements by gated card...](#)

[Figure 24.3 \(a\) Delivery system crossing the native mitral valve into left a...](#)

[Figure 24.4 Cardiac CT 18-month post implant showed a well-seated TIARA with...](#)

Chapter 25

[Figure 25.1 Mitral valve anatomy.](#)

[Figure 25.2 Anchor design. Key features of the anchor design are shown in th...](#)

[Figure 25.3 Caisson valve. The valve in combination with the anchor utilizes...](#)

[Figure 25.4 Anchor and valve delivery systems. The upper image shows the anc...](#)

[Figure 25.5 \(a\)–\(d\) Typical CT measurements. CT measurements provided in thi...](#)

Chapter 26

[Figure 26.1 First-generation CardiAQ bioprosthesis.](#)

[Figure 26.2 Second-generation CardiAQ transcatheter mitral valve implantatio...](#)

[Figure 26.3 The CardiAQ-Edwards TMVR system.](#)

[Figure 26.4 Initial \(a\) transthoracic and \(b\) transesophageal echocardiograp...](#)

[Figure 26.5 Procedural images demonstrating \(a\) transseptal puncture locatio...](#)

[Figure 26.6 Final \(a, b\) echocardiographic and \(c, d\) fluoroscopic images of...](#)

Chapter 27

[Figure 27.1 Intrepid dual-stent system and the delivery system. The Intrepid...](#)

[Figure 27.2 Subannular Intrepid positioning.](#)

[Figure 27.3 \(a\) Atrial brim expansion and alignment with annulus target; \(b\)...](#)

[Figure 27.4 Anatomical reasons for exclusion.](#)

[Figure 27.5 APOLLO trial design.](#)

[Figure 27.6 Predicted increase in treatable TMVR patient population.](#)

Chapter 28

[Figure 28.1 Mechanisms of LVOT obstruction from TMVR. The transcatheter hear...](#)

[Figure 28.2 Animal necropsy after LAMPOON. Necropsy of a pig heart after LAM...](#)

[Figure 28.3 The LAMPOON technique. \(a\) Two guiding catheters are advanced re...](#)

[Figure 28.4 Predicting the neo-LVOT and skirt neo-LVOT. \(a\) A virtual valve ...](#)

[Figure 28.5 The LAMPOON procedure. \(a\). Transesophageal echocardiography depi...](#)

[Figure 28.6 LAMPOON prevents LVOT obstruction. \(a\) 3D transesophageal echoca...](#)

Chapter 29

[Figure 29.1 Anatomy of the left ventricular outflow tract \(LVOT\). \(a\) Long-a...](#)

[Figure 29.2 Percutaneous transcatheter mitral valve replacement \(TMVR\) in mi...](#)

[Figure 29.3 Septal reduction therapy of a patient with severe MAC with predi...](#)

Chapter 30

[Figure 30.1 Mitral annulus sizing and prediction of the neo-LVOT. \(A\) CT mea...](#)

[Figure 30.2 Strategies to prevent paravalvular leakage. \(a\) Fixation of a fe...](#)

Chapter 31

[Figure 31.1 Complexity of mitral PVL. Panel \(a\) illustrates multiple PVLs ar...](#)

[Figure 31.2 Preplanning of mitral PVL closure. \(a\) and \(b\) "Clock face" diag...](#)

[Figure 31.3 Transapical access. \(a\) and \(b\). Fluoroscopy guidance. \(a\) A micr...](#)

[Figure 31.4 Antegrade crossing of mitral PVL. Work windows of echo-fluorosc...](#)

[Figure 31.5 Transseptal-transapical atrioventricular loop for closing a larg...](#)

[Figure 31.6 Simultaneous deployment of multiple devices. \(a\) Telescoping coa...](#)