

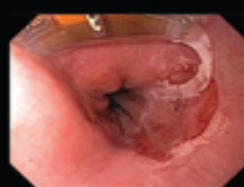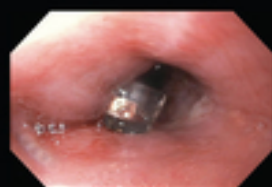

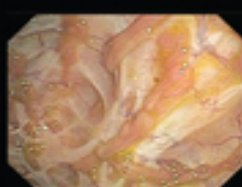
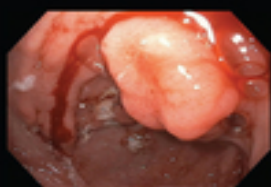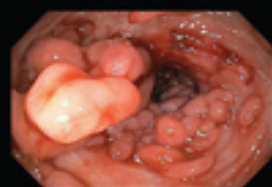PRACTICAL PEDIATRIC GASTROINTESTINAL ENDOSCOPY

THIRD 3 EDITION

EDITED BY

GEORGE GERSHMAN · MIKE THOMSON



WILEY Blackwell

Table of Contents

[Cover](#)

[Title Page](#)

[Copyright Page](#)

[Personal statements](#)

[Contributors](#)

[About the Companion Website](#)

[Part One: Pediatric Endoscopy Setting](#)

[1 Introduction](#)

[2 History of pediatric gastrointestinal endoscopy.](#)

[The precursors](#)

[The fiberscope](#)

[Training](#)

[Evolution](#)

[Conclusion](#)

[REFERENCES](#)

[3 The endoscopy unit](#)

[Unit design](#)

[Unit management](#)

[Equipment](#)

[Conclusion](#)

[REFERENCES](#)

[4 Pediatric procedural sedation and general anesthesia for gastrointestinal endoscopy.](#)

[Introduction](#)

[Definitions/spectrum of sedation to general anesthesia](#)

[Assessing risk in the pediatric patient](#)

[Preparation](#)

[Staffing and environment preparation](#)

[During sedation and monitoring](#)

[Postsedation care](#)

[Conclusion](#)

[FURTHER READING](#)

[5 Pediatric endoscopy training and ongoing assessment](#)

[Introduction](#)

[Training](#)

[Assessment](#)

[Conclusion](#)

[REFERENCES](#)

[6 Recertification and revalidation as concepts in pediatric endoscopy](#)

[REFERENCES](#)

[7 The role of the Global Rating Scale in pediatric endoscopy](#)

[Introduction](#)

[Pediatric endoscopy GRS](#)

[The future](#)

[REFERENCES](#)

[FURTHER READING](#)

[8 Quality indicators as a critical part of pediatric endoscopy provision](#)

[Introduction](#)

[Conclusion](#)

[REFERENCES](#)

9 e-learning in pediatric endoscopy

USEFUL WEBSITES

Part Two: Diagnostic Pediatric Endoscopy

10 Indications for gastrointestinal endoscopy in childhood

Introduction

Diagnostic endoscopy

Therapeutic indications for endoscopy

11 Diagnostic upper gastrointestinal endoscopy

Introduction

Indications for EGD

Assembling the equipment and preprocedure check-up

Endoscope handling

Preparation for esophageal intubation

Techniques of esophageal intubation

Exploration of the esophagus, stomach, and duodenum

Biopsy technique

pH and pH impedance probe placement

Complications

Uncommon, incidental, and rare findings during EGD

FURTHER READING

12 Pediatric ileocolonoscopy

Bowel preparation for colonoscopy

Indications for ileocolonoscopy

Contraindications for ileocolonoscopy

Equipment

Informed consent and preprocedure preparation

Specifics of sedation for colonoscopy.

Embryology of the colon relative to ileocolonoscopy.

Endoscopic anatomy of the colon and terminal ileum

Torque steering technique - the key to successful ileocolonoscopy.

Technique of ileocolonoscopy.

Complications

Common pathology: rectal bleeding

Rare pathology.

FURTHER READING

13 Handling of specimens and orientation of biopsies

Introduction

Specimen handling in the endoscopy unit

Specimen handling in the histopathology laboratory.

REFERENCES

14 Enteroscopy.

Introduction

Double-balloon enteroscopy technique

Single-balloon enteroscopy.

Spiral enteroscopy.

Intraoperative or laparoscopy-assisted enteroscopy

General complications

Conclusion

FURTHER READING

15 Wireless capsule endoscopy

Introduction

Practical approach

Pediatric experience and pathologies

Recent developments

Conclusion

REFERENCES

16 Endoscopic ultrasonography

Introduction

Instruments and technique

Indications in children

EUS features in pediatric diseases

REFERENCES

17 Chromoendoscopy

Indications

Application technique

Recognition of lesions

FURTHER READING

18 Confocal laser endomicroscopy in the diagnosis of pediatric gastrointestinal disorders

Contrast agents

Upper GI tract

Lower GI tract

Conclusion

FURTHER READING

19 High-risk pediatric endoscopy

Introduction

[Patients at high risk for cardiopulmonary and sedation-related events](#)

[Patients at high risk for bleeding](#)

[Patients at high risk for perforation](#)

[Patients at high risk for endoscopy-related infections](#)

[Risk factors for procedure-related infections](#)

[REFERENCES](#)

[Part Three: Pediatric GI Pathologies and the Role of Endoscopy in Their Management](#)

[20 Esophagitis](#)

[Introduction](#)

[Infectious esophagitis](#)

[Epidermolysis bullosa](#)

[Esophagitis in Crohn's disease](#)

[Chemotherapy and radiotherapy-induced esophagitis](#)

[Final considerations](#)

[REFERENCES](#)

[21 Eosinophilic esophagitis](#)

[Introduction](#)

[Mucosal biopsy procurement](#)

[Assessment of esophageal gross findings](#)

[Therapeutic uses for endoscopy](#)

[Future alternative devices for mucosal assessment](#)

[Acknowledgments](#)

[REFERENCES](#)

[22 Gastritis and gastropathy](#)

[Introduction](#)

[Infective gastropathy](#)

[Reactive gastropathy](#)

[Conclusion](#)

[REFERENCES](#)

[23 Celiac disease](#)

[Introduction](#)

[Visual diagnosis, biopsy sampling, handling, and histopathology](#)

[Future of endoscopy in pediatric CD](#)

[REFERENCES](#)

[24 Role of endoscopy in inflammatory bowel disease including scoring systems](#)

[Introduction](#)

[Diagnosis](#)

[Monitoring](#)

[Scoring systems](#)

[REFERENCES](#)

[Part Four: Therapeutic Pediatric Endoscopy](#)

[25 Endoscopic management of esophageal strictures](#)

[Stricture presentation](#)

[Classification](#)

[Diagnosis](#)

[Differential diagnosis](#)

[Treatment](#)

[REFERENCES](#)

[26 Endoscopic management of caustic ingestion](#)

[Introduction](#)

[Pathophysiology](#)

[Clinical presentation](#)

[Assessment and management](#)

[Endoscopy](#)

[Treatment](#)

[Long-term complications](#)

[REFERENCES](#)

[27 Pneumatic balloon dilation and peroral endoscopic myotomy for achalasia](#)

[Introduction](#)

[Diagnosis and management of achalasia](#)

[Therapeutic options](#)

[Peroral endoscopic myotomy](#)

[REFERENCES](#)

[28 Endoscopic approaches to the treatment of gastroesophageal reflux disease](#)

[Introduction](#)

[Endoscopic suturing devices](#)

[EsophyX®](#)

[Delivery of radiofrequency energy \(Stretta® system\)](#)

[Gastroesophageal biopolymer injection](#)

[Conclusion](#)

[FURTHER READING](#)

[29 Foreign body ingestion](#)

[Introduction](#)

[Diagnostic evaluation](#)

[Esophageal impaction of a foreign body](#)

[Foreign bodies in the stomach and small bowel](#)

[Food bolus impaction](#)

[Equipment and management approaches for foreign body removal](#)

[REFERENCES](#)

[30 Non-variceal endoscopic hemostasis](#)

[Introduction](#)

[General considerations](#)

[Choice of endoscope](#)

[Techniques of endoscopic hemostasis](#)

[REFERENCES](#)

[31 Variceal endoscopic hemostasis](#)

[Portal hypertension and variceal formation](#)

[Diagnosis, classification, and risk stratification of varices](#)

[Primary prophylaxis](#)

[Secondary prophylaxis](#)

[Gastric varices](#)

[REFERENCES](#)

[32 Endoscopic approach to obscure gastrointestinal bleeding lesions](#)

[Introduction](#)

[Classification](#)

[Evaluation and management of obscure gastrointestinal bleeding](#)

[Diagnostic and therapeutic approach with enteroscopy](#)

[Conclusion](#)

[REFERENCES](#)

[33 Percutaneous endoscopic gastrostomy](#)

[Introduction](#)

[Indications](#)

[Contraindications](#)

[Decision to proceed with PEG and
preprocedure evaluation](#)

[Technique](#)

[Postprocedure management](#)

[Complications](#)

[New uses of the PEG technique](#)

[Conclusion](#)

[FURTHER READING](#)

[34 Single-stage percutaneous endoscopic
gastrostomy.](#)

[Introduction](#)

[Indications](#)

[Contraindications](#)

[Advantages of single-stage PEG](#)

[Drawbacks](#)

[Technique](#)

[Postprocedure management](#)

[Complications](#)

[Useful tips](#)

[Materials](#)

[Consent](#)

[REFERENCES](#)

[35 Pediatric laparoscopic-assisted direct
percutaneous jejunostomy.](#)

[Introduction](#)

[Conclusion](#)

FURTHER READING

36 Naso-jejunal and Gastro-jejunal tube placement

FURTHER READING

37 Endoscopic retrograde
cholangiopancreatography

Introduction

Duodenoscopes and accessories

Performing ERCP in children

Adverse events in pediatric ERCP

Biliary indications for diagnostic and
therapeutic ERCP

Pancreatic indications for diagnostic and
therapeutic ERCP

Functional biliary sphincter disorder
(previously sphincter of Oddi dysfunction; SOD)

Conclusion

FURTHER READING

38 Endoscopic drainage of pancreatic pseudocysts

Pancreatitis

Pancreatic pseudocysts

REFERENCES

39 Duodenal web division by endoscopy

FURTHER READING

40 Polypectomy

Principles of electrosurgery

Snare loops

Routine polypectomy

Complications

FURTHER READING

41 Endomucosal resection

Introduction

High-magnification chromoscopic colonoscopy

Endoscopic mucosal resection

Clinical recommendations and conclusions

42 Endoscopic management of polyposis syndromes

Introduction and classification

Familial adenomatous polyposis

Juvenile polyposis syndrome

Peutz-Jeghers syndrome

43 Transnasal gastrointestinal endoscopy

Introduction

Preendoscopy preparation

Views and image quality

Duration

Success rates

Patient comfort and preference

Complications and safety profile

Therapeutic use

Future considerations

Conclusion

REFERENCES

44 Endoscopic bariatric approaches

Introduction

Intragastric balloons

Duodenojejunal bypass liner

Conclusion

FURTHER READING

[45 Over-the-scope clip and full-thickness resection device](#)

[FURTHER READING](#)

[46 Endoscopic treatment of gastrointestinal bezoars](#)

[REFERENCES](#)

[47 Natural orifice transendoluminal surgery](#)

[Index](#)

[End User License Agreement](#)

List of Tables

Chapter 7

[Table 7.1 Pediatric GRS domains and standards \(www.thejag.org.uk\)](#)

Chapter 10

[Table 10.1 Therapeutic indications for EGD](#)

[Table 10.2 Indications for therapeutic colonoscopy in children](#)

Chapter 12

[Table 12.1 Contraindications to ileocolonoscopy](#)

[Table 12.2 Technical specifications of new regular adult colonoscopes](#)

[Table 12.3 Technical specifications of new slim colonoscopes](#)

[Table 12.4 Technical specifications of new ultra-slim colonoscopes](#)

[Table 12.5 Complications associated with pediatric colonoscopy](#)

Chapter 13

[Table 13.1 Artefacts related to biopsy trauma and specimen processing in endo...](#)

Chapter 14

[Table 14.1 Diagnostic and therapeutic indications for enteroscopy.](#)

Chapter 15

[Table 15.1 Potential indications for capsule endoscopy in pediatric patients](#)

Chapter 16

[Table 16.1 Commercially available echo-endoscopes and miniprobes](#)

[Table 16.2 Indications for EUS in children](#)

[Table 16.3 EUS features in esophageal diseases](#)

[Table 16.4 EUS features in gastric pathology.](#)

[Table 16.5 EUS features of the cystic and mass lesions of the pancreas and bi...](#)

Chapter 17

[Table 17.1 Types of staining](#)

[Table 17.2 "Surface" guidelines for chromoendoscopy in ulcerative colitis](#)

Chapter 20

[Table 20.1 Endoscopic classification of esophageal candida](#)

Chapter 22

[Table 22.1 Classification of gastropathy. Gastritis and gastropathy can be cl...](#)

Chapter 26

[Table 26.1 Endoscopic classification of caustic injuries](#)

Chapter 29

[Table 29.1 Equipment compatible with a pediatric endoscope \(2 mm channel\)](#)

Chapter 31

[Table 31.1 Classification system for esophageal varices](#)

Chapter 32

[Table 32.1 Principal causes of obscure gastrointestinal bleeding in children](#)

Chapter 33

[Table 33.1 Tricks of the trade](#)

Chapter 34

[Table 34.1 Advantages of single-stage PEG](#)

Chapter 37

[Table 37.1 Duodenoscopes: specification](#)

[Table 37.2 Biliary indications for diagnostic and therapeutic ERCP](#)

[Table 37.3 ERCP findings in infants with suspected biliary atresia](#)

[Table 37.4 Todani classification of choledochal cyst \(based on the shape of a...](#)

[Table 37.5 Pancreatic indications for diagnostic and therapeutic ERCP](#)

[Table 37.6 Role of MRCP and ERCP in children with pancreatic disorders](#)

[Table 37.7 Steps of biliary and pancreatic sphincterotomy technique](#)

[Table 37.8 Steps of endoscopic marsupialization of duodenal duplication](#)

Chapter 41

[Table 41.1a Paris classification of endoscopic lesion morphology](#)

[Table 41.1b modified Kudo criteria for the classification of colorectal crypt...](#)

[Table 41.2 Classification of common chromoscopic dyes](#)

Chapter 42

[Table 42.1 Polyps and polyposis syndromes seen in childhood and associated ge...](#)

[Table 42.2 Endoscopic surveillance and screening strategies for polyposis syn...](#)

Chapter 43

[Table 43.1 Currently available ultrathin endoscopes](#)

List of Illustrations

Chapter 10

[Figure 10.1 Suggested diagnostic algorithm of chronic vomiting. PPI, proton ...](#)

[Figure 10.2 Suggested diagnostic algorithm of lower gastrointestinal bleedin...](#)

[Figure 10.3 Suggested diagnostic algorithm for chronic abdominal pain.](#)

[Figure 10.4 Suggested diagnostic algorithm of chronic diarrhea.](#)

[Figure 10.5 Suggested initial management of upper gastrointestinal bleeding....](#)

Chapter 11

[Figure 11.1 Control panel handling. The control panel is held by the left fo...](#)

[Figure 11.2 The connecting tube behind the thumb balances the weight of the ...](#)

[Figure 11.3 Manipulations with the R/L and U/D knobs. The thumb is the main ...](#)

[Figure 11.4 Technique of extensive rotation of the control knobs. The middle...](#)

[Figure 11.5 The initial phase of esophageal intubation. The endoscopist shou...](#)

[Figure 11.6 The root of the tongue appears as a cobblestone texture. It may ...](#)

[Figure 11.7 The initial view of the epiglottis. The epiglottis should be fou...](#)

[Figure 11.8 The endoscopic anatomy of the larynx: panoramic view.](#)

[Figure 11.9 Endoscopic appearance of the vocal cords. A close capture of the...](#)

[Figure 11.10 Close-up view of the crico-arytenoid cartilages. The esophageal...](#)

[Figure 11.11 Side-view of the groove between the lateral wall of the larynx ...](#)

[Figure 11.12 Appearance of the pharyngoepiglottic fold signals to reverse di...](#)

[Figure 11.13 Close-up view of the esophageal orifice.](#)

[Figure 11.14 The second physiological narrowing of the esophagus. It does no...](#)

[Figure 11.15 The distal esophagus. It tapers down toward the hiatal notch.](#)

[Figure 11.16 Z-line. The junction between the pale esophageal and richer col...](#)

[Figure 11.17 Prominent fold of the greater curvature of the stomach. Appeara...](#)

[Figure 11.18 Panoramic view of the gastric body. It can be achieved by clock...](#)

[Figure 11.19 Gastric angularis. The detailed image of the angularis can be e...](#)

[Figure 11.20 Panoramic view of the antrum. At this stage of the procedure, t...](#)

[Figure 11.21 Panoramic view of the duodenal bulb. This is useful for correct...](#)

[Figure 11.22 Endoscopic mapping of the duodenal bulb during the insertion ph...](#)

[Figure 11.23 Mapping of the walls of the duodenal bulb after reduction of th...](#)

[Figure 11.24 Appearance of the transitional zone between the duodenal bulb a...](#)

[Figure 11.25 Horizontal configuration of the transitional zone between the d...](#)

[Figure 11.26 The major duodenal papilla, the hallmark of the second portion ...](#)

[Figure 11.27 The major duodenal papilla. The side-viewing duodenoscope allow...](#)

[Figure 11.28 The endoscopic appearance of the duodenum at the level of the l...](#)

[Figure 11.29 View of the gastric body during the initial phase of the retrof...](#)

[Figure 11.30 Appearance of the cardia after partial withdrawal of the shaft ...](#)

[Figure 11.31 Detailed view of the cardia after further withdrawal of the sco...](#)

[Figure 11.32 Appearance of the Z-line signals the end of the withdrawal part...](#)

[Figure 11.33 Small squamous papilloma of the middle esophagus.](#)

[Figure 11.34 \(a\) Proximal edge of almost circumferential mass in the distal ...](#)

[Figure 11.35 Highly unusual appearance of the gastric mucosa: prominent and ...](#)

[Figure 11.36 \(a\) Acute phase of severe corrosive gastritis. \(b\) Multiple sca...](#)

[Figure 11.37 Pinpoint narrowing of the pylorus induced by the circular mass ...](#)

[Figure 11.38 Heterotopic pancreas in the greater curvature of the prepyloric...](#)

[Figure 11.39 \(a\) Sessile hyperplastic polyp in the antrum. \(b\) Inflammatory ...](#)

[Figure 11.40 Burkitt's lymphoma: multiple ulcerated mass lesions in the stom...](#)

[Figure 11.41 Razed, rounded ulcerated lesions with irregular base in the sto...](#)

[Figure 11.42 \(a\) A relatively large active ulcer on the posterior wall of th...](#)

[Figure 11.43 \(a\) Edematous and dilated folds of the duodenum. \(b\) Numerous w...](#)

Chapter 12

[Figure 12.1 Unusually wide-open anus. This finding is suspicious for spina b...](#)

[Figure 12.2 Squamocolumnar junction or dentate line.](#)

[Figure 12.3 The longitudinal folds in the distal rectum \(columns of Morgani\)...](#)

[Figure 12.4 Semilunar folds of Houston in the rectum.](#)

[Figure 12.5 Typical vascular pattern of the normal rectum.](#)

[Figure 12.6 The sigmoid colon. The endoscopic markers of normal sigmoid colo...](#)

[Figure 12.7 The angle is sharper when the descending colon extends down belo...](#)

[Figure 12.8 The descending colon. The shape of the descending colon is close...](#)

[Figure 12.9 The vascular pattern of the descending colon. The stems of the v...](#)

[Figure 12.10 The splenic flexure. It is marked by bluish discoloration.](#)

[Figure 12.11 The angle between the splenic flexure and transverse colon in r...](#)

[Figure 12.12 The transverse colon. The triangular shape is the endoscopic ha...](#)

[Figure 12.13 The hepatic flexure. The mucosa of this area is paler and has a...](#)

Figure 12.14 The hepatic flexure, which is dome shaped. The junction between...

Figure 12.15 Appendiceal orifice and “bow and arrow sign”: the imaginary arr...

Figure 12.16 A focal widening or bulging of the circular fold at the upper a...

Figure 12.17 Lumen as a clock face. (a) Scope straight. (b) Tip up deflectio...

Figure 12.18 Slightly depressed groove-like area and merging folds are the s...

Figure 12.19 The main submucosal veins and their branches. The main vessels ...

Figure 12.20 Common locations of the lumen. (a) The lumen is located at 9 o’...

Figure 12.21 Prominent taenia coli. An appearance of the taenia while approa...

Figure 12.22 Schematic images of: (a) alpha loop, (b) N-loop and (c) Scope G...

Figure 12.23 Gamma loop in the transverse colon.

Figure 12.24 The ileocecal valve. It is usually located between the 5 o’cloc...

Figure 12.25 The terminal ileum. Velvety texture, yellowish tinge, and lymph...

Figure 12.26 Ulcerative colitis. Diffuse inflammation is typical for ulcerat...

Figure 12.27 The “cecal patch”: a focal inflammation of the appendiceal orif...

Figure 12.28 Severe form of ulcerative colitis. (a) Narrowing of the lumen d...

Figure 12.29 Multiple pseudopolyps. (a,b) Acute phase. (c) Endoscopic remiss...

Figure 12.30 Aphthous ulcer. A small, 4-5 mm, shallow lesion with the rim of...

Figure 12.31 Deep longitudinal ulcers in a patient with Crohn's disease.

Figure 12.32 (a) Mucosal bridging. (b) Colonic stricture.

Figure 12.33 Allergic colitis. Multiple lymphoid follicles with rim of eryth...

Figure 12.34 Small aphthoid-like lesions can occasionally be induced by bowe...

Figure 12.35 Numerous lymphoid follicles in the sigmoid colon.

Figure 12.36 Multiple enlarged (more than 3 mm) lymphoid follicles in the te...

Figure 12.37 Six-year-old boy with recurrent ileocolonic intussusceptions. I...

Figure 12.38 Sessile juvenile polyp.

Figure 12.39 Pedunculated juvenile polyp.

Figure 12.40 Large juvenile polyp in the descending colon.

Figure 12.41 The "chicken skin" sign. The mucosa around a large juvenile pol...

Figure 12.42 Juvenile polyposis. Multiple juvenile polyps in the rectum and ...

Figure 12.43 Multiple colon polyps in a 5-year-old boy with FAP.

[Figure 12.44 Adenocarcinoma of the right colon in an 11-year-old boy with si...](#)

[Figure 12.45 Non-Hodgkin's lymphoma of the ileum. The indications for a colo...](#)

[Figure 12.46 Langerhans cell histiocytosis of the colon: multiple yellowish ...](#)

[Figure 12.47 Large hemangioma of the sigmoid colon in a 3-year-old girl with...](#)

[Figure 12.48 Angiodysplasia of the colon in a child with recurrent low GI bl...](#)

[Figure 12.49 Idiopathic colonic varices of the right colon in a 9-year-old b...](#)

[Figure 12.50 Congenital colonic varices in a 3-week-old baby with hematochez...](#)

Chapter 13

[Figure 13.1 \(a\) GIT biopsies embedded in multicassettes \(e.g., ABC\). The mac...](#)

[Figure 13.2 \(a\) Gastrointestinal sample embedded on edge, rendering a good v...](#)

Chapter 14

[Figure 14.1 Double-balloon enteroscope system configuration.](#)

[Figure 14.2 DBE technique.](#)

[Figure 14.3 Double-balloon tattoo.](#)

[Figure 14.4 Polyp detected \(a\) and removed \(b\).](#)

[Figure 14.5 Multiple angiomas in small bowel.](#)

[Figure 14.6 Meckel's diverticulum.](#)

[Figure 14.7 \(a\) Blue rubber bleb nevus syndrome lesions. \(b\) Blue rubber ble...](#)

[Figure 14.8 Single-balloon enteroscopy.](#)

[Figure 14.9 Spiral enteroscopy outside the patient.](#)

[Figure 14.10 Spiral enteroscope advancing intraluminally.](#)

[Figure 14.11 Extent of laparoscopic-assisted enteroscopy.](#)

[Figure 14.12 Intraoperative enteroscopy and transillumination of a discrete ...](#)

Chapter 15

[Figure 15.1 Occult bleeding from an angiodysplasia.](#)

[Figure 15.2 Jejunal Peutz-Jeghers polyp.](#)

[Figure 15.3 \(a\) Crohn's disease. \(b\) A follow-up study in a 16-year-old male...](#)

[Figure 15.4 CMUSE or diaphragm disease.](#)

[Figure 15.5 Lymphoma.](#)

[Figure 15.6 Meckel's diverticulum.](#)

[Figure 15.7 NSAID lesions.](#)

[Figure 15.8 Crohn's aphthoid ulcers and stricture.](#)

[Figure 15.9 Celiac disease.](#)

[Figure 15.10 Methods of "front-loading" the PillCamTM onto a gastroscope. \(a...](#)

[Figure 15.11 Intestinal lymphangiectasia.](#)

[Figure 15.12 Intestinal intussusception.](#)

[Figure 15.13 Images obtained with an esophageal capsule.](#)

[Figure 15.14 Colon capsule.](#)

[Figure 15.15 Mechanism for magnetic capsule propulsion.](#)

Chapter 16

[Figure 16.1 Ultrasound catheter probe.](#)

[Figure 16.2 Front-loading ultrasound probe.](#)

[Figure 16.3 Radial scan ultrasound. Distal tip of echo-endoscope with balloo...](#)

[Figure 16.4 Linear scan ultrasound video endoscope. Distal tip of echo-endos...](#)

[Figure 16.5 The linear probe with advanced aspiration/biopsy needle.](#)

[Figure 16.6 EUS of the needle \(*double arrow*\) advanced into a pancreatic pseu...](#)

[Figure 16.7 Orientation of a FNA needle advanced through the operative chann...](#)

[Figure 16.8 \(a\) Esophagus wall; the first inner hyperechoic \(bright\) layer i...](#)

[Figure 16.9 Esophageal anastomotic stenosis: thickening of concentric layers...](#)

[Figure 16.10 Esophageal duplication marked by arrow.](#)

[Figure 16.11 Congenital stenosis with aberrant cartilaginous remnants \(*white...*](#)

[Figure 16.12 Gastrointestinal stromal tumor \(GIST\) \(arising from submucosal ...](#)

[Figure 16.13 GIST-FNA. Arrow points toward the FNA within the labeled mass \(...](#)

[Figure 16.14 Gastric lymphoma \(distortion of the gastric wall and enlarged l...](#)

[Figure 16.15 Duodenal duplication.](#)

[Figure 16.16 Plicate hypertrophy of the stomach related to *Helicobacter pylo...*](#)

[Figure 16.17 Duodenal web.](#)

[Figure 16.18 Choledocholithiasis: two stones \(*arrow*\) in the dilated common b...](#)

[Figure 16.19 Autoimmune pancreatitis \(white arrow pointing at fullness in pa...](#)

[Figure 16.20 Pancreatic pseudocyst. \(a\) Hypoechoic/anechoic cyst \(*white arro...*](#)

Chapter 17

[Figure 17.1 The tip of a pediatric ERCP catheter pushed through the biopsy c...](#)

[Figure 17.2 Endoscopic view of Barrett's esophagus: \(a\) plain close view; \(b...](#)

[Figure 17.3 Endoscopic view of the distal duodenum in a patient with celiac ...](#)

[Figure 17.4 Immersion chromoendoscopy after methylene blue spray, without pr...](#)

[Figure 17.5 In a patient with familial adenomatous polyposis coli, flat \(a\)...](#)

[Figure 17.6 Colonic polyps before and after chromoendoscopy. \(a\) Hyperplasti...](#)

Chapter 18

[Figure 18.1 Confocal laser endomicroscope \(Pentax\).](#)

[Figure 18.2 Comparison of confocal images with conventional histological ima...](#)

[Figure 18.3 Comparison of confocal images with conventional histological ima...](#)

[Figure 18.4 \(a\) Inflammatory bowel disease showing bifid crypt pattern, cryp...](#)

[Figure 18.5 CLE of GVHD showing nuclear debris representing apoptotic bodies...](#)

Chapter 20

[Figure 20.1 Friability, edema, and erythema of varying degrees eventually as...](#)

[Figure 20.2 Endoscopic characteristics of herpes esophagitis including mucos...](#)

[Figure 20.3 Similar characteristics are shown in this figure.](#)

[Figure 20.4 In epidermolysis bullosa, narrowing of the esophagus is more pro...](#)

[Figure 20.5 Crohn's esophageal involvement is usually with aphthoid ulcerati...](#)

[Figure 20.6 Radiation- or chemotherapy-induced esophagitis can be significan...](#)

Chapter 21

[Figure 21.1 Exudate - whitish coating on the esophageal surface. Exudate rep...](#)

[Figure 21.2 Circumferential rings along the length of the esophagus. This fi...](#)

[Figure 21.3 Mucosal edema and linear furrows. These finding are representati...](#)

[Figure 21.4 Longitudinal rent. This split can occur with the passage of the ...](#)

[Figure 21.5 Food impaction present in the esophageal lumen. Mucosa is edemat...](#)

Chapter 23

[Figure 23.1 \(a\) Endoscopy with water immersion showing normal villus pattern...](#)

[Figure 23.2 \(a\) Duodenal biopsy specimen with bottom opened and oriented on ...](#)

Chapter 25

[Figure 25.1 Complex esophageal stricture secondary to caustic ingestion.](#)

[Figure 25.2 Congenital esophageal stenosis with tracheal remnants.](#)

[Figure 25.3 \(a\) Fluoroscopic appearance of a balloon waist. The arrow shows ...](#)

[Figure 25.4 Incisions of the scar performed using a needle knife and a cutti...](#)

[Figure 25.5 Two-year-old boy with complex esophageal stricture due to causti...](#)

[Figure 25.6 The Dynamic Stent®.](#)

[Figure 25.7 \(a\) The Dynamic Stent® in correct position. The two radiopaque b...](#)

Chapter 26

[Figure 26.1 Grade I corrosive esophagitis with diffuse erythema and minimal ...](#)

[Figure 26.2 Grade IIa corrosive esophagitis: extensive mucosal sloughing.](#)

[Figure 26.3 Grade IIb of corrosive esophagitis: multiple ulcerations.](#)

[Figure 26.4 Corrosive gastritis.](#)

[Figure 26.5 Esophageal stricture after lye ingestion.](#)

[Figure 26.6 Multiple esophageal strictures two months after caustic ingestio...](#)

Chapter 27

[Figure 27.1 Subtypes of achalasia on high-resolution manometry: \(a\) I, \(b\) I...](#)

[Figure 27.2 Diagnosis and treatment algorithm based on expert opinion and cu...](#)

[Figure 27.3 Rigiflex dilator.](#)

[Figure 27.4 Submucosal injection of methylene blue prior to mucosotomy.](#)

[Figure 27.5 Lineal mucosal incision.](#)

[Figure 27.6 Initial stage of tunnel development.](#)

[Figure 27.7 Creation of a tunnel using an electrical knife and pressure from...](#)

[Figure 27.8 Completion of the tunnel with exposed circular muscle.](#)

Chapter 28

[Figure 28.1 EndoCinch front-mounted on the endoscope.](#)

[Figure 28.2 Suction applied and full-thickness tissue capture followed by ne...](#)

[Figure 28.3 Endoscopic gastroplication. This figure shows the pattern of a z...](#)