

Applied Anatomy for Clinical Procedures at a Glance

**Jane Sturgess
Francesca Crawley
Ramez Kirollos
Kirsty Cattle**

WILEY Blackwell

Table of Contents

[Cover](#)

[Contributors](#)

[1 Scrubbing up](#)

[Equipment \(Figure 1.1\)](#)

[Antiseptic solutions](#)

[Procedure \(Figure 1.4\)](#)

[2 Setting up a sterile field and draping the patient](#)

[Equipment \(Figure 2.1\)](#)

[Procedure](#)

[Top tips](#)

[3 Three-way tap](#)

[Description of the three-way tap](#)

[Potential uses of the three-way tap \(Figure 3.3\)](#)

[Safe use of a three-way tap](#)

[After the procedure](#)

[Anatomical pitfalls](#)

[Top tips](#)

[4 Common equipment for core clinical procedures](#)

[Needles](#)

[Sampling devices](#)

[5 Local anaesthetic infiltration](#)

[Classes of local anaesthetics \(Figure 5.1\)](#)

[Mechanism of action](#)

[Dose](#)

[Side effects](#)

[Technique](#)

[Anatomical pitfalls](#)

[Top tips](#)

[6 Obtaining consent](#)

[Why do we obtain consent?](#)

[Principles of obtaining consent if the patient has capacity](#)

[Principles of obtaining consent if the patient does not have capacity](#)

[Obtaining consent](#)

[Responsibility for obtaining consent](#)

[Discussing side effects/risk](#)

[Verbal or written consent? \(Figures 6.2 and 6.3\)](#)

[Consent in children](#)

[7 Manometer for central venous pressure and lumbar puncture](#)

[What is a manometer line?](#)

[What is normal pressure?](#)

[Set-up of the CSF manometer line](#)

[Set-up of the CVP manometer line](#)

[Common anatomical pitfalls](#)

[8 Bladder irrigation sets](#)

[Equipment](#)

[Set-up](#)

[Common anatomical pitfalls](#)

[Top tips](#)

[9 Underwater seal for chest drains](#)

[Equipment \(Figure 9.1\)](#)

[Connection \(Figures 9.3 and 9.4\)](#)

[How does it work? \(see Figure 9.2\)](#)

[Anatomical pitfalls](#)

[Top tips](#)

[10 Male catheterisation](#)

[Equipment \(Figure 10.1\)](#)

[Procedure](#)

[Contraindications](#)

[Common problems](#)

[11 Female catheterisation](#)

[Indications](#)

[Equipment \(Figure 11.1\)](#)

[Pre-procedure](#)

[Procedure](#)

[Top tips](#)

[12 Arterial blood gases](#)

[Equipment \(Figure 12.1\)](#)

[Procedure](#)

[Post-procedure](#)

[Allen's test \(Figure 12.3\)](#)

[Brachial and femoral stabs](#)

[Common anatomical pitfalls](#)

[Top tips](#)

[13 Performing an electrocardiogram](#)

[Equipment \(Figure 13.1\)](#)

[Procedure](#)

[Anatomical \(and other\) pitfalls](#)

[Top tips](#)

[14 Oropharyngeal airway](#)

[Equipment \(Figure 14.1\)](#)

[Technique \(Figure 14.2\)](#)

[Aftercare](#)

[Common anatomical pitfalls](#)

[Top tips](#)

[15 Nasopharyngeal airway](#)

[Equipment \(Figure 15.1\)](#)

[Technique \(Figure 15.2\)](#)

[Aftercare](#)

[Common anatomical pitfalls](#)

[Top tips](#)

[16 Laryngeal mask airway](#)

[Equipment](#)

[Technique](#)

[Aftercare](#)

[Common anatomical pitfalls](#)

[Top tips](#)

[17 Central venous cannulation \(high approach internal jugular\)](#)

[How to insert a central venous line](#)

[Equipment \(Figure 17.1\)](#)

[Technique \(Figure 17.3\)](#)

[Landmarks for internal jugular vein \(Figure 17.4\)](#)

[Aftercare](#)

[Common complications](#)

[18 Central venous cannulation \(low approach internal jugular\)](#)

[How to insert a central venous line](#)

[Equipment \(Figure 18.1\)](#)

[Technique \(Figure 18.3\)](#)

[Landmarks for internal jugular vein \(Figure 18.4\)](#)

[Aftercare](#)

[Common complications](#)

[19 Central venous cannulation \(subclavian\)](#)

[How to insert a central venous line](#)

[Equipment \(Figure 19.1\)](#)

[Technique \(Figure 19.3\)](#)

[Aftercare](#)

[Common complications](#)

[Landmarks for subclavian vein \(Figure 19.4\)](#)

[Top tips](#)

[20 Direct current cardioversion](#)

[Indications](#)

[Equipment \(Figure 20.1\)](#)

[Contraindications](#)

[Pre-procedure](#)

[Procedure](#)

[Post-procedure](#)

[Top tip](#)

[Pitfalls](#)

[21 Intercostal drains](#)

[Requirements](#)

[Equipment \(Figure 21.1\)](#)

[Procedure - Seldinger technique](#)

[Procedure - Surgical technique](#)

[Anatomical \(and other\) pitfalls](#)

[22 Pleural tap](#)

[Requirements](#)

[Equipment \(Figure 22.1\)](#)

[Procedure](#)

[Anatomical \(and other\) pitfalls](#)

[Complications](#)

[23 Inserting a nasogastric tube](#)

[Equipment \(Figure 23.1\)](#)

[Procedure](#)

[Post-procedure](#)

[Contraindications to NGT insertion](#)

[Pitfalls](#)

[Top tips](#)

[24 Lumbar puncture](#)

[Equipment \(Figure 24.1\)](#)

[Technique](#)

[Aftercare](#)

[Common anatomical pitfalls](#)

[Top tips](#)

[25 Bone marrow aspirate](#)

[Equipment \(Figure 25.1\)](#)

[Pre-procedure](#)

[Procedure](#)

[Clotting requirements for a bone marrow aspirate](#)

[26 Ascitic tap](#)

[Equipment \(Figure 26.1\)](#)

[Contraindications](#)

[Pre-procedure](#)

[Procedure](#)

[Post-procedure](#)

[Top tips](#)

[27 Paracentesis](#)

[Indications](#)

[Equipment \(Figure 27.1\)](#)

[Pre-procedure](#)

[Procedure](#)

[Post-procedure](#)

[Complications](#)

[28 Knee aspiration](#)

[Equipment \(Figure 28.1\)](#)

[Indications](#)

[Procedure](#)

[Aftercare](#)

[Common anatomical pitfalls \(Figure 28.3\)](#)

[Anatomical top tips](#)

[29 Skin biopsy](#)

[Equipment \(Figure 29.1\)](#)

[Indications](#)

[Procedure](#)

[Anatomical pitfalls](#)

[Top tips](#)

[30 Basic suturing](#)

[Equipment \(Figure 30.1\)](#)

[Choice of suture](#)

[Factors determining the choice of sutures and needles](#)

[Technique](#)

[Variations in suturing techniques](#)

[Removal of sutures](#)

[Anatomical pitfalls](#)

[31 Basic anastomotic techniques](#)

[Equipment \(Figure 31.1a-c\)](#)

[Technique](#)

[Types \(Figure 31.2\)](#)

[Anatomical pitfalls: Bowel](#)

[Anatomical pitfalls: Vascular](#)

[Aftercare: Bowel](#)

[Aftercare: Vascular](#)

[32 Abscess drainage and debridement](#)

[Equipment \(Figure 32.1\)](#)

[Procedure \(Figure 32.2\)](#)

[Aftercare](#)

[Pitfalls](#)

[Anatomical top tips](#)

[33 Bag mask ventilation \(adults\)](#)

[Equipment \(Figure 33.1\)](#)

[Technique \(Figure 33.2\)](#)

[Aftercare](#)

[Common anatomical pitfalls](#)

[Top tips](#)

[34 Endotracheal intubation \(adults\)](#)

[Equipment \(Figure 34.1\)](#)

[Technique](#)

[Aftercare](#)

[Common anatomical pitfalls](#)

[Top tips](#)

[35 Needle cricothyroidotomy \(adults\)](#)

[Equipment \(Figure 35.1\)](#)

[Technique](#)

[Aftercare](#)

[Common anatomical pitfalls](#)

[Top tips](#)

[36 Surgical cricothyroidotomy](#)

[Equipment](#)

[Indications](#)

[Contraindications](#)

[Procedure \(Figure 36.2\)](#)

[Aftercare](#)

[Common anatomical pitfalls](#)

[Top tip](#)

[37 Defibrillation](#)

[Equipment \(Figure 37.1\)](#)

[Technique](#)

[Aftercare](#)

[Common anatomical pitfalls](#)

[Top tips](#)

[38 Spinal injection](#)

[Equipment \(Figure 38.1\)](#)

[Technique](#)

[Aftercare](#)

[Common anatomical pitfalls](#)

[Top tips](#)

[Difficulty aspirating CSF](#)

[Safety \(Figure 38.5\)](#)

[39 Epidural injection](#)

[Equipment \(Figure 39.1\)](#)

[Technique](#)

[Aftercare](#)

[Common anatomical pitfalls](#)

[Top tips](#)

[40 Procedure-related safety](#)

[The problem](#)

[Definitions \(as per the World Health Organisation\)](#)

[The response](#)

[Responsibilities for National Health Service \(NHS\) and staff](#)

[Top tips \(from the World Health Organisation\)](#)

[References](#)

[Additional reading](#)

[Index](#)

[End User License Agreement](#)

List of Illustrations

Chapter 1

[Figure 1.1 Equipment.](#)

[Figure 1.2 Before scrubbing, don hat, mask, eye protection.](#)

[Figure 1.3 Recommended handwashing technique.](#)

[Figure 1.4 Procedure. \(a\) Wash hands and arms three times \(b\) rinsing from f...](#)

Chapter 2

[Figure 2.1 Equipment.](#)

[Figure 2.2 Apply the antiseptic to the operating field in a radial or concen...](#)

[Figure 2.3 Cover the edges of the operating field with sterile drapes, adher...](#)

[Figure 2.4 Use of an antiseptic impregnated incise drape reduces surgical si...](#)

[Figure 2.5 Use sterile drapes to cover an operating trolley on which operati...](#)

Chapter 3

[Figure 3.1 Three-way tap. Note the arrows on the limbs to indicate flow of f...](#)

[Figure 3.2 Equipment. Three-way taps come individually or incorporated with ...](#)

[Figure 3.3 Different possible positions of a three-way tap and combinations ...](#)

Chapter 4

[Figure 4.1 Image to show the possible types of needle tip and position of th...](#)

[Figure 4.2 Butterfly needles. Note the needle length and injection port \(whi...](#)

[Figure 4.3 Spinal needles. Note the difference in needle diameter for each c...](#)

[Figure 4.4 Cannulas. Note the difference in needle diameter and length for e...](#)

[Figure 4.5 Syringes. Note the different tips of the 60 mL syringes. From lef...](#)

[Figure 4.6 Urinary catheters. From top to bottom 3 way, 2 way, Curved or Cou...](#)

[Figure 4.7 Urinary catheter bags. The most commonly used bag in hospital has...](#)

[Figure 4.8 Commonly used blood bottles.](#)

[Figure 4.9 Blood culture bottles.](#)

[Figure 4.10 Sample pots. The white capped pot is suitable to collect most sa...](#)

[Figure 4.11 Simple dressing pack, often used for small procedures.](#)

[Figure 4.12 Large sterile pack, for central lines and more invasive procedur...](#)

Chapter 5

[Figure 5.1 Local anaesthetics.](#)

[Figure 5.2 Skin layers.](#)

[Figure 5.3 Field block.](#)

[Figure 5.4 Digital block.](#)

[Figure 5.5 Supraorbital nerve block.](#)

Chapter 6

[Figure 6.1 The GMC provides advice on consent, available on their website: h...](#)

[Figure 6.2 Consent forms. Choose the correct form for the procedure and pati...](#)

[Figure 6.3 Decision making with regard to obtaining consent and which form t...](#)

Chapter 7

[Figure 7.1 A simple manometer line.](#)

[Figure 7.2 Standard CSF manometer line; note the hollow tube, connected to t...](#)

[Figure 7.3 Standard CVP manometer line showing the continuous column of fluid...](#)

[Figure 7.4 CSF manometer and three-way tap setup.](#)

[Figure 7.5 Equipment required for CVP.](#)

Chapter 8

[Figure 8.1 Setting up the irrigation set. The set is primed from a single ir...](#)

[Figure 8.2 Attaching the irrigation and catheter bag to the catheter. \(a\) At...](#)

[Figure 8.3 The entire irrigation set-up. \(a\) Open the flow switches on the p...](#)

Chapter 9

[Figure 9.1 Equipment.](#)

[Figure 9.2 \(a\) single, \(b\) double, \(c\) triple chamber underwater seals. The ...](#)

[Figure 9.3 Attaching the drain to the seal.](#)

[Figure 9.4 The complete set-up.](#)

Chapter 10

[Figure 10.1 Equipment required.](#)

[Figure 10.2 Patient positioning and draping.](#)

[Figure 10.3 Insertion of the catheter. Holding the penis in your non-dominan...](#)

[Figure 10.4 Male urethral anatomy.](#)

Chapter 11

[Figure 11.1 Equipment required.](#)

[Figure 11.2 Patient positioning.](#)

[Figure 11.3 Female perineal anatomy.](#)

[Figure 11.4 Female pelvic anatomy.](#)

Chapter 12

[Figure 12.1 Equipment required.](#)

[Figure 12.2 Anatomy of the radial artery at the wrist.](#)

[Figure 12.3 Allen's test. \(a\) Anatomy of the superficial and deep palmar arc...](#)

[Figure 12.4 Brachial artery anatomy.](#)

[Figure 12.5 Femoral artery anatomy.](#)

Chapter 13

[Figure 13.1 Equipment required.](#)

[Figure 13.2 Chest lead positions.](#)

[Figure 13.3 Surface anatomy of the heart.](#)

Chapter 14

[Figure 14.1 Equipment.](#)

[Figure 14.2 Sagittal anatomy of the upper airway.](#)

[Figure 14.3 Technique oropharyngeal airway: \(a\) size the airway, \(b\) open th...](#)

[Figure 14.4 Soft tissue trauma following poorly inserted oropharyngeal airwa...](#)

Chapter 15

[Figure 15.1 Equipment.](#)

[Figure 15.2 Technique nasopharyngeal airway: \(a\) size the airway, \(b\) making...](#)

[Figure 15.3 Sagittal anatomy of correctly placed nasopharyngeal airway.](#)

Chapter 16

[Figure 16.1 Different LMAs.](#)

[Figure 16.2 Patient position for insertion of LMA \(plus sagittal anatomy\).](#)

[Figure 16.3 How to hold the LMA.](#)

[Figure 16.4 Anatomical position of a correctly positioned LMA.](#)

[Figure 16.5 Soft tissue trauma following poorly inserted LMA.](#)

Chapter 17

[Figure 17.1 Equipment required.](#)

[Figure 17.2 Patient positioning.](#)

[Figure 17.3 Procedure - see text for explanation.](#)

[Figure 17.4 Internal jugular landmarks.](#)

[Figure 17.5 Chest X-ray showing central venous catheter in correct position....](#)

Chapter 18

[Figure 18.1 Equipment required.](#)

[Figure 18.2 Patient positioning.](#)

[Figure 18.3 Procedure.](#)

[Figure 18.4 Internal jugular landmarks.](#)

[Figure 18.5 Chest X-ray showing central venous catheter in correct position....](#)

Chapter 19

[Figure 19.1 Equipment required.](#)

[Figure 19.2 Patient positioning.](#)

[Figure 19.3 Procedure.](#)

[Figure 19.4 Subclavian vein landmarks.](#)

[Figure 19.5 Chest X-ray showing central venous catheter in correct position....](#)

Chapter 20

[Figure 20.1 Equipment.](#)

[Figure 20.2 Patient position.](#)

[Figure 20.3 Lead position.](#)

[Figure 20.4 Synchronising the cardioverter.](#)

[Figure 20.5 Charging the cardioverter.](#)

[Figure 20.6 ECG pre DC cardioversion.](#)

[Figure 20.7 ECG post successful DC cardioversion.](#)

Chapter 21

[Figure 21.1 Equipment.](#)

[Figure 21.2 Patient positioning and “window of safety”, bordered by pectoral...](#)

[Figure 21.3 Thoracic anatomy. Note the position of the neurovascular bundle ...](#)

Chapter 22

[Figure 22.1 Equipment.](#)

[Figure 22.2 Patient positioning and ‘window of safety’. Aspiration can be pe...](#)

[Figure 22.3 Connection of cannula to three-way tap and syringe with position...](#)

[Figure 22.4 Thoracic anatomy. Note the position of the neurovascular bundle ...](#)

Chapter 23

[Figure 23.1 Equipment.](#)

[Figure 23.2 Different NG types.](#)

[Figure 23.3 Patient position.](#)

[Figure 23.4 Estimate the length of insertion by holding the nasogastric tube...](#)

[Figure 23.5 Chest X-ray showing NGT in correct position, tip going below dia...](#)

Chapter 24

[Figure 24.1 Equipment.](#)

[Figure 24.2 Patient position.](#)

[Figure 24.3 Surface anatomy.](#)

[Figure 24.4 Three-way tap and manometer.](#)

[Figure 24.5 Anatomical structures the needle will pass.](#)

[Figure 24.6 Problems \(a\) bone only - articulated lumbar vertebrae, lordosis ...](#)

Chapter 25

[Figure 25.1 \(a\) Equipment trolley, including syringes, needles, cleaning pad...](#)

[Figure 25.2 Patient position for \(a\) iliac crest or \(b\) sternal aspirate.](#)

[Figure 25.3 Posterior aspect of bony pelvis.](#)

Chapter 26

[Figure 26.1 Equipment.](#)

[Figure 26.2 Landmarks for aspiration site.](#)

[Figure 26.3 Abdominal wall anatomy.](#)

Chapter 27

[Figure 27.1 Equipment.](#)

[Figure 27.2 Landmarks for aspiration site.](#)

[Figure 27.3 Abdominal wall anatomy.](#)

[Figure 27.4 'z' track to avoid overlapping skin and peritoneal puncture site...](#)

Chapter 28

[Figure 28.1 Equipment.](#)

[Figure 28.2 Knee surface anatomy with approaches for knee arthrocentesis.](#)

[Figure 28.3 Lateral anatomy of knee.](#)

[Figure 28.4 Bursae around the knee joint.](#)

Chapter 29

[Figure 29.1 Equipment.](#)

[Figure 29.2 Skin layers.](#)

[Figure 29.3 Shave biopsy. Holding the blade almost horizontal to the skin "s...](#)

[Figure 29.4 Punch biopsy. \(a\) The punch. \(b\) In use.](#)

[Figure 29.5 Excision biopsy. \(a\) Make an elliptical incision around the lesi...](#)

Chapter 30

[Figure 30.1 Equipment. Needle holder, suture scissors, appropriate suture ma...](#)

[Figure 30.2 How to mount a needle. Note the needle is mounted at the junctio...](#)

[Figure 30.3 Different suturing techniques. \(a\) Inverted/buried sutures. \(b\)...](#)

Chapter 31

[Figure 31.1a Equipment for bowel anastomosis.](#)

[Figure 31.1b Equipment for vascular anastomosis.](#)

[Figure 31.1c Stapling devices used for bowel anastomosis. © Ethicon, Inc....](#)

[Figure 31.2 Different configurations of possible anastomoses, e.g. \(a\) end t...](#)

[Figure 31.3 Posterior view of mesenteric vasculature.](#)

Chapter 32

[Figure 32.1 Equipment.](#)

[Figure 32.2 Procedure: \(a\) infiltrate region with local anaesthetic, \(b\) mak...](#)

[Figure 32.3 Breast anatomy, showing lactiferous ducts.](#)

[Figure 32.4 Park's classification of perianal abscesses: \(1\) Intersphincteri...](#)

Chapter 33

[Figure 33.1 Equipment.](#)

[Figure 33.2 \(a\) Patient position - 'sniffing the morning air'. \(b\) Technique...](#)

[Figure 33.3 Sagittal section of the open airway.](#)

Chapter 34

[Figure 34.1 Equipment.](#)

[Figure 34.2 'Sniffing the morning air' position.](#)

[Figure 34.3 Introduction of the laryngoscope blade and sweeping of the tongu...](#)

[Figure 34.4 Correct placement of the laryngoscope blade tip in the vallecula...](#)

[Figure 34.5 Diagram to show tissue displacement with elevation vs. levering ...](#)

[Figure 34.6 The laryngeal inlet.](#)

Chapter 35

[Figure 35.1 Equipment.](#)

[Figure 35.2 Ways to ventilate/ oxygenate post needle cricothyroidotomy: eith...](#)

[Figure 35.3 \(a\) Preparing the needle for insertion \(b\) preparing your trolle...](#)

[Figure 35.4 Patient position and surface anatomy.](#)

[Figure 35.5 Needle insertion and anatomical structures you pass.](#)

Chapter 36

[Figure 36.1 Anterior neck surface anatomy and interior anatomy.](#)

[Figure 36.2 Procedure. After locating and stabilising the cricothyroid membr...](#)

Chapter 37

[Figure 37.1 Equipment.](#)

[Figure 37.2 Defibrillator pad positions.](#)

[Figure 37.3 Cardiac action potential and the contribution of different parts...](#)

[Figure 37.4 Defibrillator showing \(a\) ventricular tachycardia and \(b\) ventri...](#)

Chapter 38

[Figure 38.1 Equipment.](#)

[Figure 38.2 Patient position and surface anatomy.](#)

[Figure 38.3 Needle direction and sagittal anatomy.](#)

[Figure 38.4 Problems with needle insertion.](#)

[Figure 38.5 Problems with safety.](#)

Chapter 39

[Figure 39.1 Equipment.](#)

[Figure 39.2 Features of the epidural needle \(a\) and catheter \(b\).](#)

[Figure 39.3 Continuous loss of resistance.](#)

[Figure 39.4 Sagittal section to show the anatomical structures the needle pa...](#)

Chapter 40

[Figure 40.1 List of 'Never Events', for which healthcare organisations have ...](#)

[Figure 40.2 The Surgical Safety Checklist elements included in the WHO paper...](#)

Applied Anatomy for Clinical Procedures at a Glance

**Jane Sturgess
Francesca Crawley
Ramez Kirollos
Kirsty Cattle**

WILEY Blackwell

This edition first published 2021
© 2021 John Wiley & Sons Ltd.

All rights reserved. No part of this publication may be reproduced, stored in a retrieval system, or transmitted, in any form or by any means, electronic, mechanical, photocopying, recording or otherwise, except as permitted by law. Advice on how to obtain permission to reuse material from this title is available at <http://www.wiley.com/go/permissions>.

The right of Jane Sturgess, Francesca Crawley, Ramez Kirollos, and Kirsty Cattle to be identified as the author(s) of this work has been asserted in accordance with law.

Registered Office(s)

John Wiley & Sons, Inc., 111 River Street, Hoboken, NJ 07030, USA
John Wiley & Sons Ltd, The Atrium, Southern Gate, Chichester, West Sussex, PO19 8SQ, UK

Editorial Office

111 River Street, Hoboken, NJ 07030, USA

For details of our global editorial offices, customer services, and more information about Wiley products visit us at www.wiley.com.

Wiley also publishes its books in a variety of electronic formats and by print-on-demand. Some content that appears in standard print versions of this book may not be available in other formats.

Limit of Liability/Disclaimer of Warranty

The contents of this work are intended to further general scientific research, understanding, and discussion only and are not intended and should not be relied upon as recommending or promoting scientific method, diagnosis, or treatment by physicians for any particular patient. In view of ongoing research, equipment modifications, changes in governmental regulations, and the constant flow of information relating to the use of medicines, equipment, and devices, the reader is urged to review and evaluate the information provided in the package insert or instructions for each medicine, equipment, or device for, among other things, any changes in the instructions or indication of usage and for added warnings and precautions. While the publisher and authors have used their best efforts in preparing this work, they make no representations or warranties with respect to the accuracy or completeness of the contents of this work and specifically disclaim all warranties, including without limitation any implied warranties of merchantability or fitness for a particular purpose. No warranty may be created or extended by sales representatives, written sales materials or promotional statements for this work. The fact that an organization, website, or product is referred to in this work as a citation and/or potential source of further information does not mean that the publisher and authors endorse the information or services the organization, website, or product may provide or recommendations it may make. This work is sold with the understanding that the publisher is not engaged in rendering professional services. The advice and strategies contained herein may not be suitable for

your situation. You should consult with a specialist where appropriate. Further, readers should be aware that websites listed in this work may have changed or disappeared between when this work was written and when it is read. Neither the publisher nor authors shall be liable for any loss of profit or any other commercial damages, including but not limited to special, incidental, consequential, or other damages.

Library of Congress Cataloging-in-Publication Data

Names: Sturgess, Jane, author. | Crawley, Francesca, author. | Kirollos, Ramez, author. | Cattle, Kirsty, author.

Title: Applied anatomy for clinical procedures at a glance / Jane Sturgess, Francesca Crawley, Ramez Kirollos, Kirsty Cattle.

Other titles: At a glance series (Oxford, England)

Description: Hoboken, NJ : Wiley-Blackwell 2021. | Series: At a glance series | Includes bibliographical references and index.

Identifiers: LCCN 2020015329 (print) | LCCN 2020015330 (ebook) | ISBN 9781119054580 (paperback) | ISBN 9781119054610 (adobe pdf) | ISBN 9781119054641 (epub)

Subjects: MESH: Surgical Procedures, Operative | Diagnostic Techniques and Procedures | Clinical Medicine--methods | Anatomy | Handbook

Classification: LCC RD37 (print) | LCC RD37 (ebook) | NLM WO 39 | DDC 617-dc23

LC record available at <https://lcn.loc.gov/2020015329>

LC ebook record available at <https://lcn.loc.gov/2020015330>

Cover Design: Wiley

Cover Image: © Stocktrek Images/Getty Images

Contributors

Kirsty Cattle

East of England Deanery
Cambridge, UK

Charles Crawley

Addenbrooke's Hospital
Cambridge University Hospitals NHS Trust
Cambridge, UK

Francesca Crawley

West Suffolk Hospital
Bury St Edmunds, UK

Olivia Kenyon

East of England Deanery
Cambridge, UK

Ramez Kirollos

Addenbrooke's Hospital
Cambridge University Hospitals NHS Trust
Cambridge, UK

Sherif Kirollos

Addenbrooke's Hospital
Cambridge University Hospitals NHS Trust
Cambridge, UK

Jane Sturgess

West Suffolk Hospital
Bury St Edmunds, UK

1

Scrubbing up

Sherif Kirollos and Ramez Kirollos

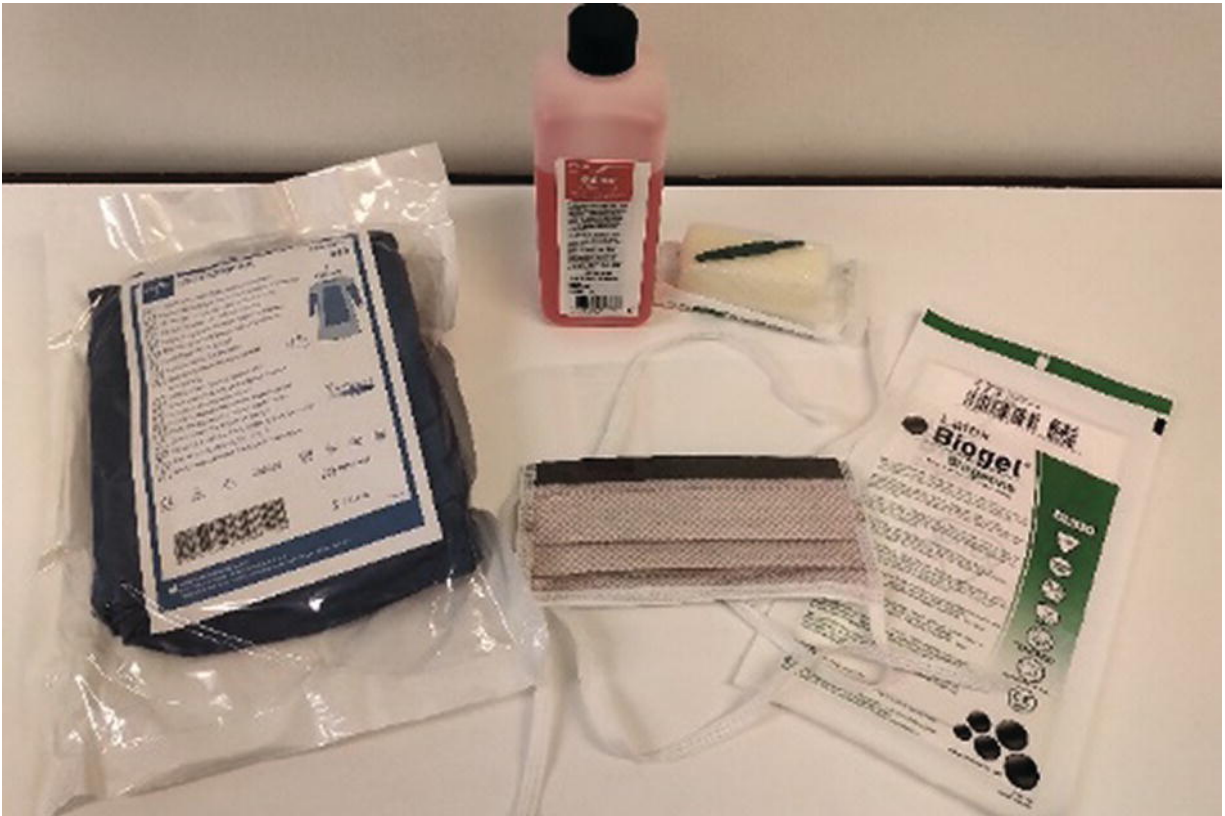


Figure 1.1 Equipment.

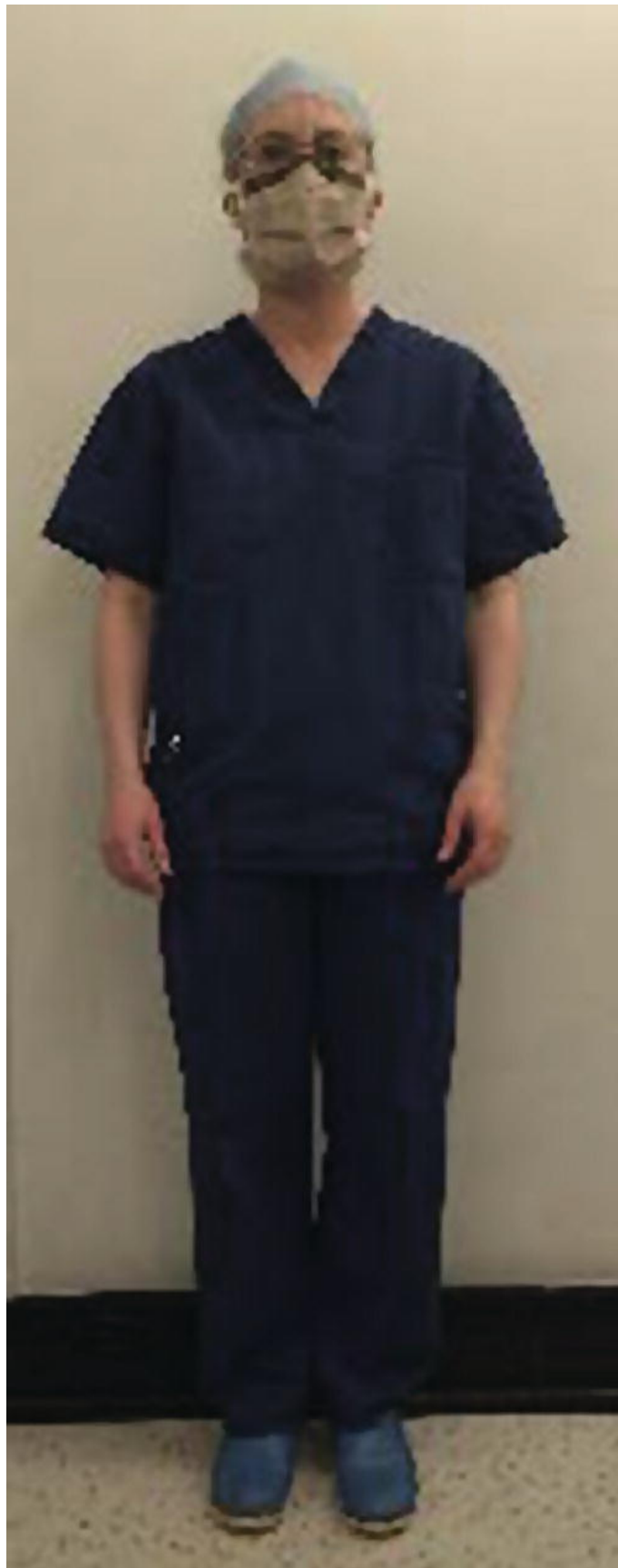

Figure 1.2 Before scrubbing, don hat, mask, eye protection.