

# Clinical Ophthalmic Oncology

## Uveal Tumors

Bertil E. Damato  
Arun D. Singh  
*Editors*

*Third Edition*

 Springer

---

# Clinical Ophthalmic Oncology

---

Bertil E. Damato • Arun D. Singh  
Editors

# Clinical Ophthalmic Oncology

Uveal Tumors

Third Edition

 Springer

*Editors*

Bertil E. Damato  
University of Oxford  
Oxford  
UK

Arun D. Singh  
Cole Eye Institute Cleveland Clinic  
Cleveland, OH  
USA

ISBN 978-3-030-17878-9      ISBN 978-3-030-17879-6 (eBook)  
<https://doi.org/10.1007/978-3-030-17879-6>

© Springer Nature Switzerland AG 2019

This work is subject to copyright. All rights are reserved by the Publisher, whether the whole or part of the material is concerned, specifically the rights of translation, reprinting, reuse of illustrations, recitation, broadcasting, reproduction on microfilms or in any other physical way, and transmission or information storage and retrieval, electronic adaptation, computer software, or by similar or dissimilar methodology now known or hereafter developed.

The use of general descriptive names, registered names, trademarks, service marks, etc. in this publication does not imply, even in the absence of a specific statement, that such names are exempt from the relevant protective laws and regulations and therefore free for general use.

The publisher, the authors, and the editors are safe to assume that the advice and information in this book are believed to be true and accurate at the date of publication. Neither the publisher nor the authors or the editors give a warranty, expressed or implied, with respect to the material contained herein or for any errors or omissions that may have been made. The publisher remains neutral with regard to jurisdictional claims in published maps and institutional affiliations.

This Springer imprint is published by the registered company Springer Nature Switzerland AG  
The registered company address is: Gewerbestrasse 11, 6330 Cham, Switzerland

---

## Preface

Ophthalmic tumors are rare and diverse so that their diagnosis can be quite complex. Treatment usually requires special expertise and equipment and, in many instances, is controversial. The field is advancing rapidly, because of accelerating progress in tumor biology, pharmacology, and instrumentation. Increasingly, the care for patients with an ocular or adnexal tumor is provided by a multidisciplinary team, consisting of ocular oncologists, general oncologists, radiotherapists, pathologists, psychologists, and other specialists.

For all these reasons, we felt that there was a need for the new edition of the textbook providing a balanced view of current clinical practice. Although each section of *Clinical Ophthalmic Oncology* now represents a stand-alone volume, each chapter has a similar layout with boxes that highlight the key features, tables that provide comparison, and flow diagrams that outline therapeutic approaches.

The enormous task of editing a multiauthor, multivolume textbook could not have been possible without the support and guidance by the staff at Springer: Caitlin Prim, Melanie Zerah, ArulRonika Pathinathan, and Karthik Rajasekar. Michael D. Sova kept the pressure on to meet the production deadlines.

It is our sincere hope that our efforts will meet the high expectation of the readers.

Oxford, UK  
Cleveland, OH, USA

Bertil E. Damato  
Arun D. Singh

---

## Acknowledgments

To my family, Frankanne, Erika, Stephen, and Anna (BED)

To my parents, who educated me beyond their means, and my wife, Annapurna, and my children, Nakul and Rahul, who make all my efforts worthwhile (ADS)

---

# Contents

<b>1 Uveal Tumors: Examination Techniques</b> .....	1
Bertil E. Damato and Iwona Rospond-Kubiak	
<b>2 Classification of Uveal Tumors</b> .....	11
Bertil E. Damato and Sarah E. Coupland	
<b>3 Benign Melanocytic Tumors of the Uvea</b> .....	17
Miguel Materin and Arun D. Singh	
<b>4 Uveal Melanoma: Epidemiologic Aspects</b> .....	53
Nakul Singh, Stefan Seregard, and Arun D. Singh	
<b>5 Uveal Melanoma: Clinical Features</b> .....	71
Leonidas Zografos and Ann Schalenbourg	
<b>6 Uveal Melanoma: Differential Diagnosis</b> .....	85
Bertil E. Damato and Armin R. Afshar	
<b>7 Uveal Melanoma: Histopathologic Features</b> .....	109
Tero T. Kivelä	
<b>8 Uveal Melanoma: Molecular Pathology</b> .....	121
Sarah E. Coupland, Helen Kalirai, Sophie Thornton, and Bertil E. Damato	
<b>9 Animal Models in Uveal Melanoma</b> .....	135
Julia V. Burnier, Christina Mastromonaco, Jade Marie Lasiste, and Miguel N. Burnier Jr.	
<b>10 Iris Melanoma</b> .....	155
Arun D. Singh and Bertil E. Damato	
<b>11 Management of Patients with Posterior Uveal Melanoma</b> .....	185
Bertil E. Damato	
<b>12 Uveal Melanoma: Brachytherapy</b> .....	201
Gustav Stålhammar, Stefan Seregard, and Bertil E. Damato	
<b>13 Uveal Melanoma: Proton Beam Radiation Therapy</b> .....	219
Anne Marie Lane, Ivana K. Kim, and Evangelos S. Gragoudas	

<b>14 Uveal Melanoma: Stereotactic Radiation Therapy</b> . . . . .	233
Karin Dieckmann, Roman Dunavoelgyi, Gerald Viktor Langmann, Roy Ma, Richard Pötter, Michael Sommer, Lisa Vajda, Werner Wackernagel, and Martin Zehetmayer	
<b>15 Uveal Melanoma: Phototherapy</b> . . . . .	241
Heinrich Heimann, Michael I. Seider, and Bertil E. Damato	
<b>16 Uveal Melanoma: Resection Techniques</b> . . . . .	249
Bertil E. Damato and Carl Groenewald	
<b>17 Uveal Melanoma: The Collaborative Ocular Melanoma Study</b> . . . . .	261
Ezekiel Weis, Tero T. Kivelä, and Arun D. Singh	
<b>18 Uveal Melanoma: Prognostic Factors</b> . . . . .	273
Robert Folberg and Jacob Pe'er	
<b>19 Uveal Melanoma: Prognostication Methods</b> . . . . .	279
Sarah E. Coupland, Azzam Taktak, Antonio Eleuteri, Helen Kalirai, Sophie Thornton, and Bertil E. Damato	
<b>20 Uveal Melanoma: Mortality</b> . . . . .	295
Bertil E. Damato and Azzam Taktak	
<b>21 Uveal Melanoma: Adjuvant Therapy</b> . . . . .	305
Jessica Yang, Elaine Binkley, Arun D. Singh, and Richard D. Carvajal	
<b>22 Uveal Melanoma: Metastases</b> . . . . .	317
Lucy T. Xu, Pauline Funchain, Ahmad A. Tarhini, and Arun D. Singh	
<b>23 Uveal Vascular Tumors</b> . . . . .	331
Masood Naseripour, Jørgen Krohn, Pukhraj Rishi, and Arun D. Singh	
<b>24 Uveal Neural Tumors</b> . . . . .	353
Victoria M. L. Cohen, Bertil E. Damato, and Arun D. Singh	
<b>25 Intraocular Manifestations of Hematopoietic Disorders</b> . . . . .	365
Bercin Tarlan and Hayyam Kiratli	
<b>26 Uveal Myogenic, Fibro-histiocytic, and Histiocytic Tumors</b> . . . .	379
Paul A. Rundle and Hardeep Singh Mudhar	
<b>27 Uveal Lymphoproliferative Tumors</b> . . . . .	391
Sarah E. Coupland and Arun D. Singh	
<b>28 Uveal Metastatic Tumors</b> . . . . .	403
Norbert Bornfeld and Arun D. Singh	

---

**29 Uveal Osseous Tumors** ..... 423  
Noel Horgan and Arun D. Singh

**30 Bilateral Diffuse Uveal Melanocytic Proliferation** ..... 441  
Elaine Binkley, Ilya Leskov, and Arun D. Singh

**Index** ..... 447

---

## Contributors

**Armin R. Afshar, MD, MBA, MAS** Ocular Oncology Service, Department of Ophthalmology, University of California, San Francisco, CA, USA

**Elaine Binkley, MD** Department of Ophthalmic Oncology, Cole Eye Institute, Cleveland Clinic, Cleveland, OH, USA

**Norbert Bornfeld, PhD** Klinik fuer Augenheilkunde, Universitaetsklinikum Essen, Essen, Germany

**Julia V. Burnier, PhD** Department of Oncology and Pathology, McGill University, MUHC-RI, Montreal, QC, Canada

**Miguel N. Burnier Jr., MD, PhD, FRCSC** Department of Ophthalmology and Pathology, The MUHC-McGill University Ocular Pathology & Translational Research Laboratory, Montreal, QC, Canada

**Richard D. Carvajal, MD** Division of Hematology/Oncology, Columbia University Medical Center, New York, NY, USA

**Victoria M. L. Cohen, MA, MB, BChir (Cantab), FRCOphth** Department of Ocular Oncology, Moorfields Eye Hospital, London, UK

**Sarah E. Coupland, MBBS, PhD, FRCPath** Department of Molecular and Clinical Cancer Medicine, Institute of Translational Medicine, University of Liverpool, Liverpool, Merseyside, UK

**Bertil E. Damato, MD, PhD, FRCOphth** Nuffield Department of Clinical Neurosciences, University of Oxford, John Radcliffe Hospital, Oxford, UK

**Karin Dieckmann** Department of Radiation Oncology, Medical University of Vienna/General Hospital of Vienna, Comprehensive Cancer Center, Vienna, Austria

**Roman Dunavoelgyi, MD** Department of Ophthalmology and Optometry, Medical University of Vienna, Vienna, Austria

**Antonio Eleuteri, PhD** Department of Medical Physics and Clinical Engineering, Royal Liverpool University Hospital, Liverpool, UK

**Robert Folberg, MD** Foundational Medical Studies, Pathology, and Ophthalmology, Oakland University William Beaumont School of Medicine, Rochester, MI, USA

**Pauline Funchain, MD** Taussig Cancer Center, Cleveland Clinic Foundation, Cleveland, OH, USA

**Evangelos S. Gragoudas, MD** Ocular Melanoma Center, Department of Ophthalmology, Massachusetts Eye and Ear Infirmary/Harvard Medical School, Boston, MA, USA

**Carl Groenewald, MD** Ocular Oncology Service, St Paul's Eye Unit, Royal Liverpool University Hospital, Liverpool, UK

**Heinrich Heimann, MD** Liverpool Ocular Oncology Service, Royal Liverpool University Hospital, Liverpool, Merseyside, UK

**Noel Horgan, MD, FRCSI, MRCOphth** Royal Victoria Eye and Ear Hospital, Dublin, Ireland

St. Vincent's University Hospital, Dublin, Department of Ocular Oncology and Medical Retina, Dublin, Ireland

**Helen Kalirai, BSc, PhD** Department of Molecular and Clinical Cancer Medicine, Institute of Translational Medicine, University of Liverpool, Liverpool, Merseyside, UK

**Ivana K. Kim, MD** Ocular Melanoma Center, Department of Ophthalmology, Massachusetts Eye and Ear Infirmary/Harvard Medical School, Boston, MA, USA

**Hayyam Kiratli, MD** Ocular Oncology Service, Department of Ophthalmology, Hacettepe University School of Medicine, Ankara, Turkey

**Tero T. Kivelä, MD** Ocular Oncology and Ophthalmic Pathology, Helsinki University Hospital, Helsinki, Finland

Department of Ophthalmology, University of Helsinki, Helsinki, Finland

**Jørgen Krohn, MD** Department of Clinical Medicine, Section of Ophthalmology, University of Bergen, Bergen, Norway

Department of Ophthalmology, Haukeland University Hospital, Bergen, Norway

**Anne Marie Lane, MPH** Ocular Melanoma Center, Department of Ophthalmology, Massachusetts Eye and Ear Infirmary/Harvard Medical School, Boston, MA, USA

**Gerald Viktor Langmann, MD** Comprehensive Cancer Center Graz (CCC), Medical University Graz, Graz, Austria

**Jade Marie Lasiste, MD, MSc** Department of Ophthalmology and Pathology, The MUHC-McGill University Ocular Pathology & Translational Research Laboratory, Montreal, QC, Canada

**Ilya Leskov, MD** Department of Ophthalmic Oncology, Cole Eye Institute, Cleveland Clinic Foundation, Cleveland, OH, USA

**Roy Ma, MD, FRCPC** Department of Radiation Oncology, British Columbia Cancer Agency, Vancouver, BC, Canada

**Christina Mastro Monaco, MSc, PhD Candidate** Department of Ophthalmology and Pathology, The MUHC-McGill University Ocular Pathology & Translational Research Laboratory, Montreal, QC, Canada

**Miguel Materin, MD** Ophthalmic Oncology, Duke University Eye Center, Duke Cancer Institute, Durham, NC, USA

**Hardeep Singh Mudhar, PhD, MBBChir (Cantab), FRCPath** Department of Histopathology, National Specialist Ophthalmic Pathology Service (NSOPS), Royal Hallamshire Hospital, Sheffield, South Yorkshire, UK

**Masood Naseripour, MD** Department of Ophthalmology/Ocular Oncology Service, Rassoul Akram Hospital/Iran University of Medical Sciences, Tehran, Iran

**Jacob Pe'er, MD** Department of Ophthalmology, Hadassah – Hebrew University Medical Center, Jerusalem, Israel

**Richard Pötter** Department of Radiation Oncology, Medical University of Vienna/General Hospital of Vienna, Comprehensive Cancer Center, Vienna, Austria

**Pukhraj Rishi, MS, FRCS, FRCSEd** Shri Bhagwan Mahavir Vitreoretinal Services, Sankara Nethralaya, Chennai, Tamilnadu, India

**Iwona Rospond-Kubiak, MD** Ocular Oncology Service, Department of Ophthalmology, Poznań University of Medical Sciences, Poznań, Poland

**Paul A. Rundle, MBBS, FRCOphth** Ocular Oncology Clinic, Department of Ophthalmology, Royal Hallamshire Hospital, Sheffield, South Yorkshire, UK

**Ann Schalenbourg, MD** Department of Ophthalmology, Jules-Gonin Eye Hospital, University of Lausanne, FAA, Lausanne, Switzerland

**Michael I. Seider, MD** Department of Ophthalmology, The Permanente Medical Group, San Francisco, CA, USA

University of California – San Francisco, San Francisco, CA, USA

**Stefan Seregard, MD, PhD** Ophthalmic Pathology and Oncology Service and Department of Clinical Neuroscience, St. Erik Eye Hospital and Karolinska Institutet, Stockholm, Sweden

**Arun D. Singh, MD** Department of Ophthalmic Oncology, Cole Eye Institute, Cleveland Clinic, Cleveland, OH, USA

**Nakul Singh, MS** School of Medicine, Case Western University, Cleveland, OH, USA

**Michael Sommer, MD** Department of Ophthalmology, Medical University of Graz, Graz, Austria

**Gustav Stålhammar, MD, PhD** Ophthalmic Pathology and Oncology Service and Department of Clinical Neuroscience, St. Erik Eye Hospital and Karolinska Institutet, Stockholm, Sweden

**Azzam Taktak, B.Eng (Hons)** Department of Medical Physics and Clinical Engineering, Royal Liverpool University Hospital, Liverpool, UK

**Ahmad A. Tarhini, MD** Taussig Cancer Center, Cleveland Clinic Foundation, Cleveland, OH, USA

**Bercin Tarlan, MD** Ocular Oncology Service, Department of Ophthalmology, Hacettepe University School of Medicine, Ankara, Turkey

**Sophie Thornton, BSc, PhD** Department of Molecular and Clinical Cancer Medicine, Institute of Translational Medicine, University of Liverpool, Liverpool, Merseyside, UK

**Lisa Vajda, MD, PhD** Department of Ophthalmology, Medical University of Graz, Graz, Austria

**Werner Wackernagel, MD** Department of Ophthalmology, Medical University of Graz, Graz, Austria

**Ezekiel Weis, MD, MPH** University of Alberta, Department of Ophthalmology, Edmonton, AB, Canada

University of Calgary, Department of Surgery, Calgary, AB, Canada

**Lucy T. Xu, MD** Department of Ophthalmic Oncology, Cole Eye Institute, Cleveland Clinic Foundation, Cleveland, OH, USA

**Jessica Yang, MD** Division of Hematology/Oncology, Columbia University Medical Center, New York, NY, USA

**Martin Zehetmayer, MD, PhD** Department of Ophthalmology, Medical University, General Hospital of Vienna, Vienna, Austria

**Leonidas Zografos, MD** Ophthalmology, University of Lausanne, Lausanne, Switzerland



# Uveal Tumors: Examination Techniques

1

Bertil E. Damato and Iwona Rospond-Kubiak

## Introduction

This chapter highlights procedures that are specific to the assessment of a patient with a uveal tumor. It is assumed that a full ophthalmic and systemic history is routinely obtained in all patients in addition to complete examination of both eyes and appropriate systemic assessment, consisting of clinically relevant ancillary investigations.

## History Taking

### Initial Assessment

The past medical history can sometimes provide diagnostic clues, for example, if the patient has been a heavy smoker for many years or if a previous mastectomy has been performed. While such information might suggest the source of an intra-ocular metastasis, it should not be relied upon to

distinguish between a metastasis and other types of tumor, such as melanoma and hemangioma, because dual pathology is not uncommon. The history provides an understanding of the patient's visual needs, which may help in the selection of the most appropriate form of treatment. The duration of the visual loss can have prognostic significance, for example, in patients with choroidal hemangioma in whom visual loss is irreversible if long-standing.

## Follow-Up

Routine use of a questionnaire ensures that at every follow-up visit, each patient is asked all relevant questions about general health, visual symptoms, ocular discomfort, and concerns about possible ocular complications and survival.

## Visual Acuity

If possible, the visual acuity should be measured using a LogMAR chart, which overcomes the limitations of the Snellen test, also facilitating statistical analysis of vision in any outcomes analysis [1]. If central vision is lost, the eccentric visual acuity should be measured using the optotype and, if necessary, finger counting before checking for hand movement vision.

B. E. Damato (✉)  
Nuffield Department of Clinical Neurosciences,  
University of Oxford, John Radcliffe Hospital,  
Oxford, UK  
e-mail: [bertil.damato@nhs.net](mailto:bertil.damato@nhs.net)

I. Rospond-Kubiak  
Ocular Oncology Service, Department of  
Ophthalmology, Poznań University of Medical  
Sciences, Poznań, Poland

## Slit-Lamp Examination

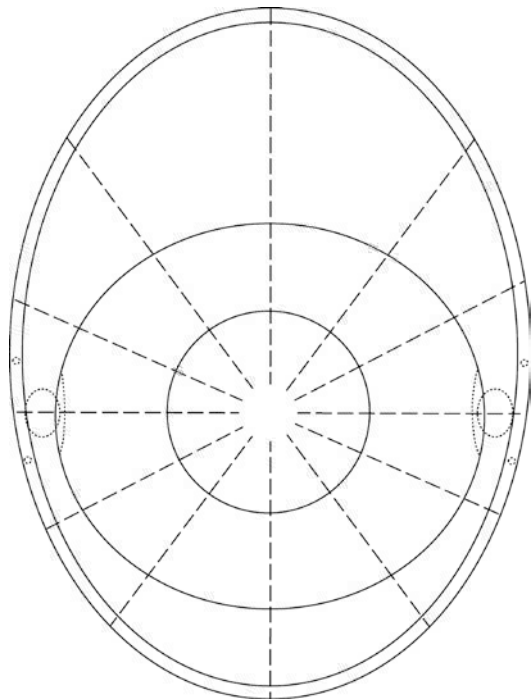
It is necessary to define the primary tumor, recognizing any secondary effects, predisposing factors, and concurrent disease (Box 1.1):

- (i) Site of origin (iris, ciliary body, choroid).
- (ii) Location (superior, supero-nasal, nasal, etc.).
- (iii) Circumferential spread, ideally in clock minutes in a clockwise direction (e.g., 5–30 or 55–5). This is easier than using degrees and more precise than clock hours. For iris tumors, there may be a scope for recording circumferential spread at pupil margin as well as the midperipheral and peripheral iris.
- (iv) Posterior margin (pars plicata, iris surface).
- (v) Anterior margin (iris surface, angle, cornea).
- (vi) Consistency (solid, cystic, multicystic).
- (vii) Shape (flat, dome, multinodular).
- (viii) Margins (diffuse, discrete).
- (ix) Color (pink, white, yellow, red, orange, tan, brown, black, etc.).
- (x) Vascularity (present or absent).
- (xi) Seeding (across iris, into angle, vitreous).
- (xii) Angle involvement (in clock minutes). The first author (BD) finds it useful to describe the angle in each clock hour as normal, scanty pigment dusting, dense pigment dusting, flat confluent pigment, bulky confluent pigment, tumor, and uncertain (because of closed angle or hyphema).
- (xiii) Extraocular spread (absent, nodular, diffuse).
- (xiv) Longitudinal and transverse basal dimensions, using the measure on the slit lamp.
- (xv) Secondary effects (dilated episcleral vessels, band keratopathy, glaucoma, hyphema, ectropion uveae and pupillary peaking, iris cyst formation, and lens abnormality such as cataract, deformity, and subluxation).
- (xvi) Predisposing factors (ocular or oculodermal melanocytosis, Sturge-Weber syndrome, and other vascular malformations).

### Box 1.1. Examination Techniques for Tumors

- History taking, slit-lamp examination, and ophthalmoscopy.
- Drawings complement photography, especially with peripheral tumors.
- Tumor dimensions can be estimated using charts and ophthalmoscopically.
- Three-mirror examination is useful in selected cases.
- Transillumination gives an approximate indication of tumor extent.

The author (BD) has designed a diagram to facilitate documentation of slit-lamp findings (Fig. 1.1). Although intended primarily for conjunctival tumors, it is useful also with iris and ciliary body tumors.



**Fig. 1.1** Template for documenting slit-lamp findings

## Indirect Ophthalmoscopy

It is essential to examine the entire fundus, with indentation if necessary, to identify any other pathology. Both eyes should be examined, ideally with mydriasis. The first author (BD) has devised the mnemonic, MELANOMA, to alert the clinician to the presence of an intraocular tumor in situations where the pupils are not routinely dilated (Box 1.2).

### Box 1.2. Symptoms and Signs Indicating Presence of an Intraocular Tumor

- *Melanoma* or other tumor visible externally in iris or episclera
- *Eccentric* visual phenomena, such as photopsia, floaters, and field loss
- *Lens* abnormalities, such as cataract, astigmatism, and coloboma
- *Afferent* pupillary defect, mostly caused by secondary retinal detachment
- *No* optical correction with spectacles because of blurring or metamorphopsia
- *Ocular* hypertension, especially if asymmetrical
- *Melanocytosis*, predisposing to melanoma
- *Asymmetrical* episcleral vessels, indicating a ciliary body tumor

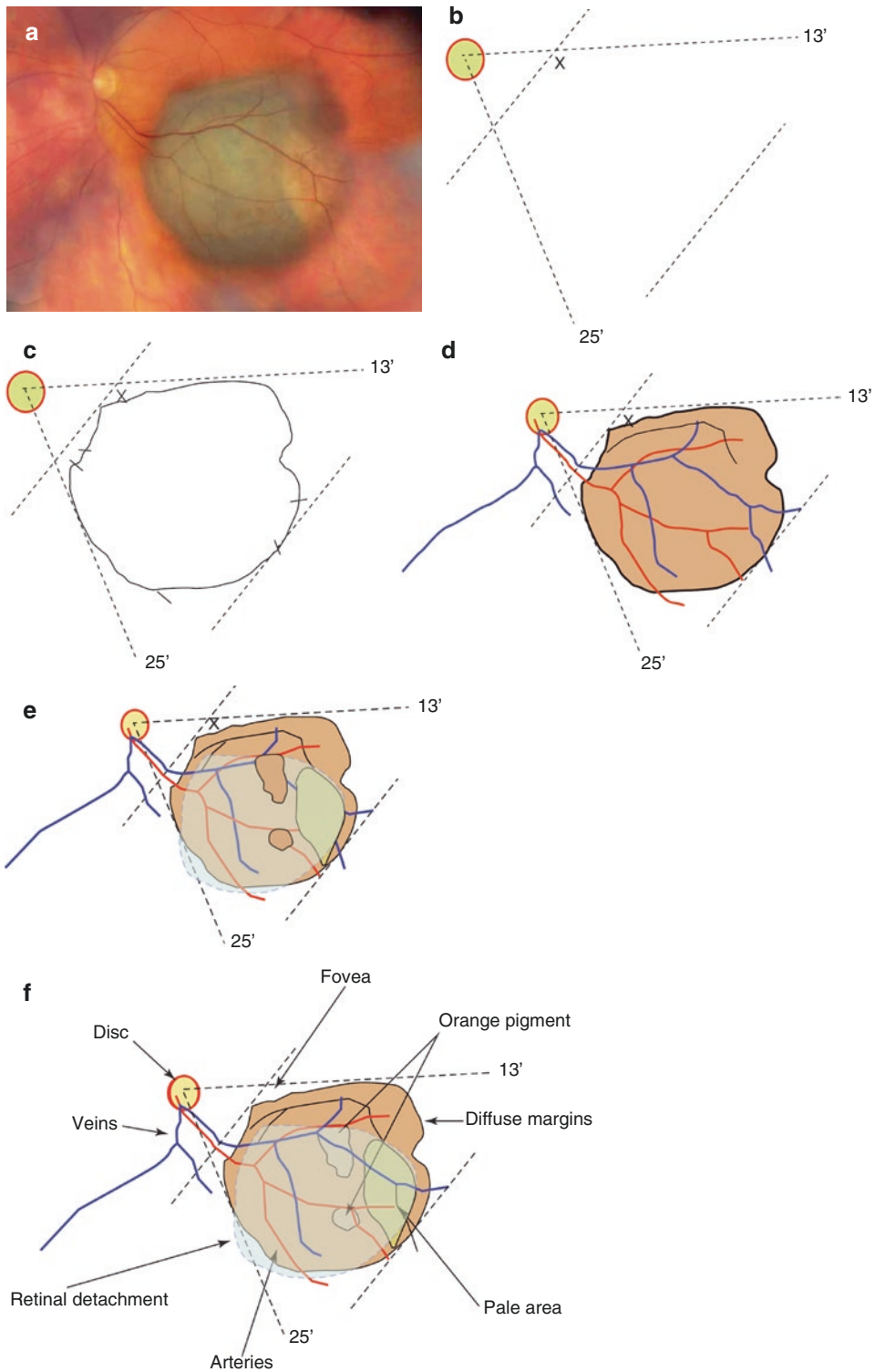
It is necessary to describe the primary tumor, any secondary effects, and any predisposing factors as follows:

- (i) Tissue of origin (choroid, retina, retinal pigment epithelium)
- (ii) Quadrant (superotemporal, superior, superonasal, etc.)
- (iii) Shape (flat, dome, collar stud)
- (iv) Margins (discrete, diffuse)
- (v) Color (pink, white, yellow, red, orange, tan, brown, black, etc.)
- (vi) Vascularity (vascular, avascular)
- (vii) Posterior extent, including distances to optic disc margin and fovea (disc diameters or mm)
- (viii) Anterior extent (post-equatorial, pre-equatorial, pars plana, pars plicata, etc.)
- (ix) Circumferential involvement of disc, ciliary body, and perhaps choroid (in clock minutes)
- (x) Internal spread (subretinal space, retina, vitreous)
- (xi) Secondary effects (RPE changes such as drusen and orange pigment over the tumor, RPE changes adjacent to the tumor, exudative retinal detachment, and hemorrhage)
- (xii) Predisposing factors (ocular melanocytosis, melanocytoma, diffuse choroidal hemangioma)

## Fundus Drawing

Fundus drawings complement photography in several ways, for example, allowing important features to be highlighted by means of notes and markers. The technique has been described in detail elsewhere (Fig. 1.2) [2].

- A. Ask the patient to lie supine on a couch or in a reclining chair.
- B. Stand at the head end of the patient and place the retinal chart on a tray next to the patient's head. The top of the chart should be facing toward the patient's feet. You should be able to move around so as to position yourself directly opposite the retinal quadrant being examined.
- C. Hold the indirect lens in the nondominant hand and a pencil in your dominant hand.
- D. Draw symbols for the optic disc and fovea, and then look at the fundus and rotate the drawing pad so that the optic disc and fovea are aligned in the same way as the fundus image.
- E. Identify the meridians, in clock hours, of the two lateral margins of the tumor, in relation to disc or fovea, and draw these lines on the chart.
- F. Estimate the distance between posterior tumor margin and disc or fovea and mark that point on the chart.
- G. Estimate the location of the anterior tumor margin in relation to equator or ora serrata and mark that point on the chart.
- H. Draw the profile of the tumor, using the marks already on the chart as guides.
- I. Starting at the tumor and working backward toward the optic disc, draw the major retinal blood vessels, placing conspicuous bifurca-



**Fig. 1.2** Drawing a choroidal tumor. Color photograph (a). Locating tumor margins with respect to disc and fovea (b), delineating tumor margins (c), drawing vascular

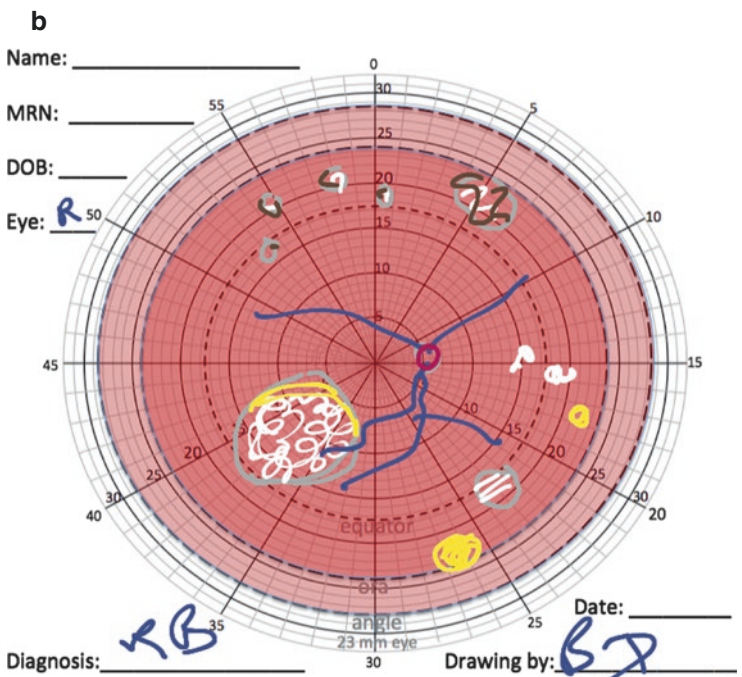
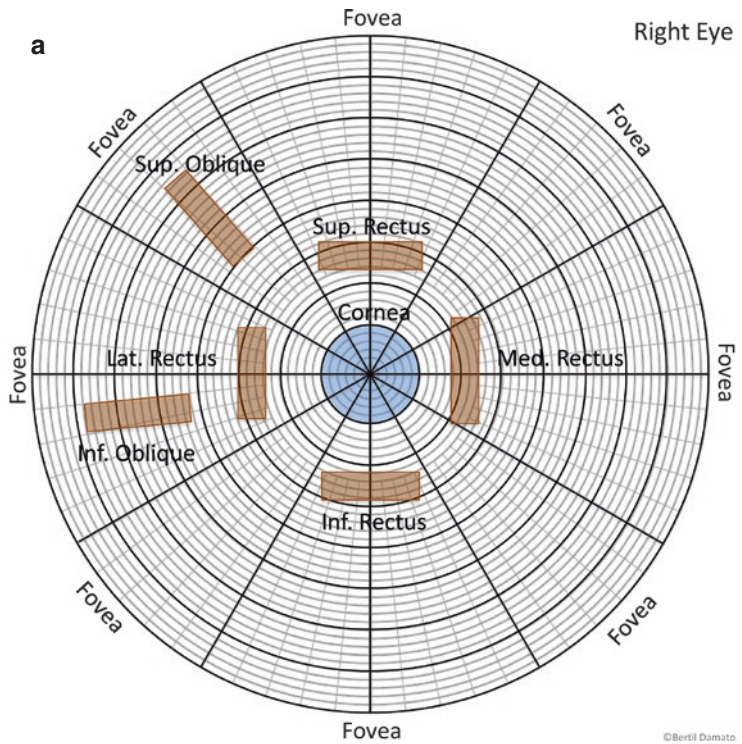
details (d), adding tumor features (e), and annotations (f). (Reprinted from Damato [2]. With permission from Elsevier)

tions and crossings in their correct positions in relation to tumor margins.

J. Fill in details, such as texture, tumor vessels, RPE changes, hemorrhages, exudates, and retinal detachment.

K. Ensure that the patient’s name and hospital number, the date of the examination, and your signature have all been documented. (Fig. 1.3a, b) shows an example of how fundus lesions are documented.

**Fig. 1.3** Chart showing outer ocular surface, designed to help plan insertion of radioactive plaque or tantalum markers for the treatment of posterior segment tumors (a). The fovea is represented by a large ring, its distance from the limbus varying with axial length. Chart designed by the first author with the fundus demarcated circumferentially in clock minutes and radially in millimeters (b). The use of this chart as a template on an electronic tablet allows digital drawings to be prepared accurately and ergonomically, also facilitating transmission by the Internet and uploading onto electronic records



## Estimation of Intraocular Tumor Basal Dimensions

Schematic diagrams have been prepared to facilitate estimation of ocular dimensions on clinical examination [2]. We have developed a system for drawing fundus diagrams on an iPad using a template we developed to enhance accuracy (Fig. 1.3b). The preparation of digital drawings with inexpensive programs is ergonomic, especially in a dark room, and allows easy modification and uploading onto electronic records. Basal dimensions of intraocular tumors can also be measured by indirect ophthalmoscopy. The chord length tumor basal diameters (anteroposterior or longitudinal and circumferential or latitudinal) are estimated while performing indirect ophthalmoscopy by assessing the proportion of a specific condensing lens field that is filled by the tumor's image. During this assessment, a 20D lens is considered to have a field diameter of approximately 12 mm, whereas a 28D lens is regarded to have a field diameter of 13 mm. For example, a tumor which fills one-half of the 20D lens field would be judged to have a diameter of approximately 6 mm, while a tumor filling two-thirds of a 28D lens field would be considered to be about 8.5 mm in diameter. Tumor dimensions can also be measured by ultrasonography, as described elsewhere.

---

## Three-Mirror Examination

Three-mirror examination is necessary to:

- A. Identify the cause of raised intraocular pressure.
- B. Determine whether a lesion behind the iris is solid or cystic.
- C. Find a small, retinal angioma.
- D. Determine the anterior extent of a pre-equatorial tumor.
- E. Measure the circumferential extent of ciliary body or angle involvement by a tumor, aligning in turn each lateral tumor margin with the center of the mirror.

## Transillumination

Transillumination can be used to detect or locate tumor margins. In general, pigmented tumors and intraocular hemorrhage block transmission of light. It must be realized that not all pigmented tumors are melanoma and, conversely, not all melanomas are pigmented. Various techniques of transillumination include (Fig. 1.4):

- A. Trans-pupillary, placing the illuminator on the cornea. Care must be taken not to overestimate posterior extension because of an oblique shadow cast by a thick tumor.
- B. Trans-ocular, with a right-angled transilluminator on the globe directly opposite to the tumor. This is less convenient than trans-pupillary transillumination but more accurate. This is the first author's preferred technique when identifying the lateral and posterior tumor margins intraoperatively, using a 20-gauge vitrectomy illuminator, which is bent 90°.
- C. Trans-scleral, with the light source on the sclera over the tumor. This only determines whether or not the tumor transmits light.

Transillumination is also useful for identifying scleral necrosis and iris atrophy.

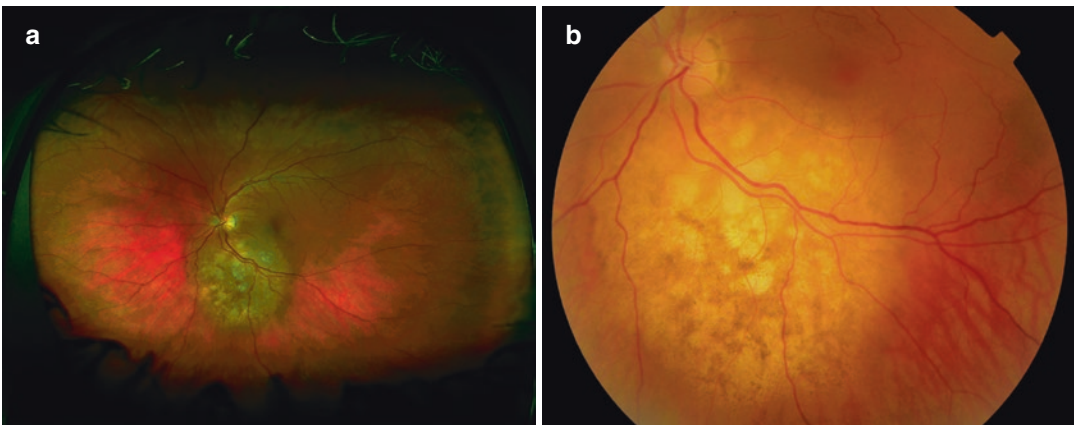
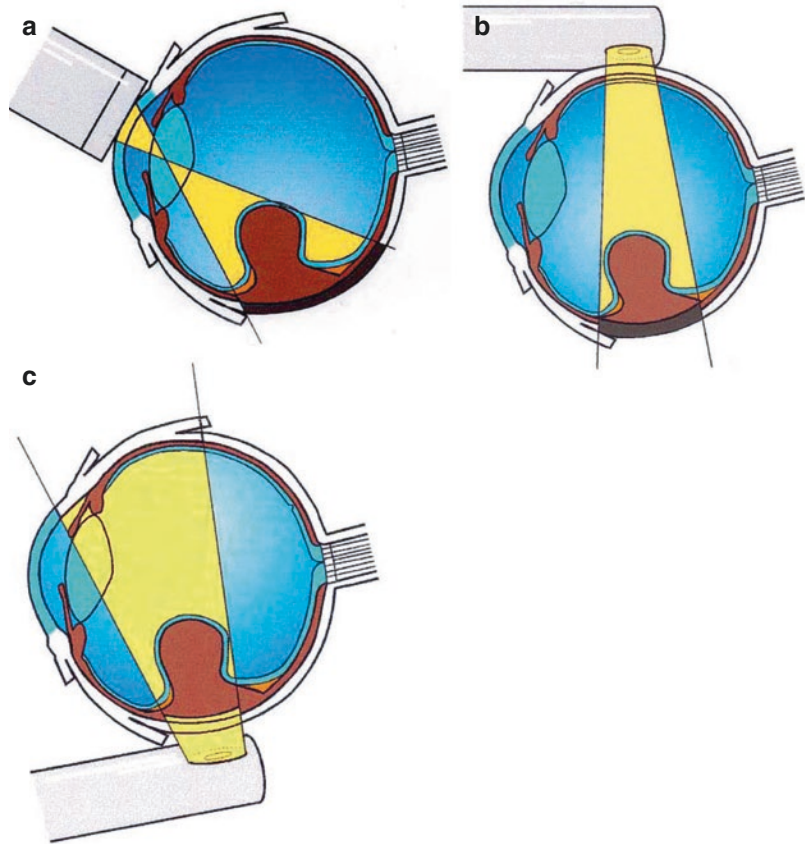
---

## Color Photography

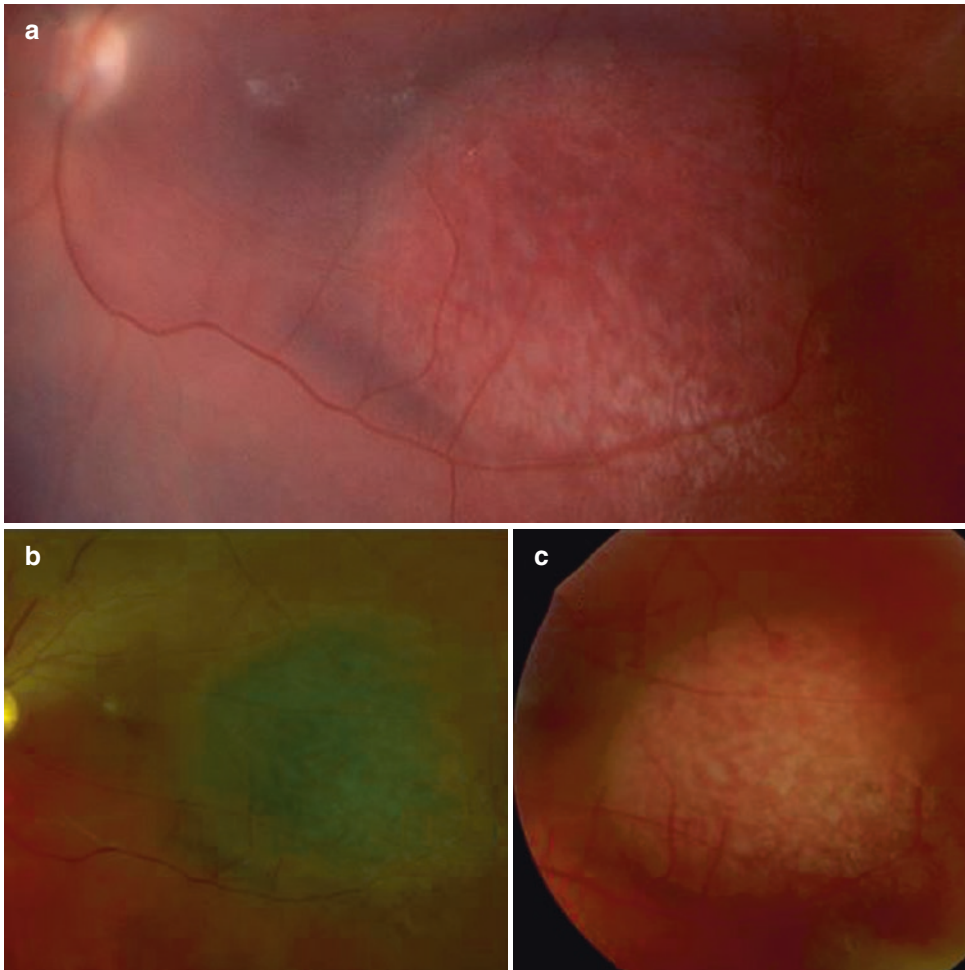
Color photography is useful for documenting the appearances of the tumor and other parts of the eye. The tumor color can vary greatly between cameras. For example, with the Optos camera, amelanotic metastases and hemangiomas may falsely appear pigmented (Figs. 1.5 and 1.6) [3, 4]. Tumor diagnosis should therefore not be based on color photographs.

Photography also defines the tumor extent in relation to adjacent landmarks, such as retinal blood vessels and pupil margin. Sequential photography is usually helpful in detecting tumor growth over time (Fig. 1.7). False impressions of growth can arise, however, as a result of inconsis-

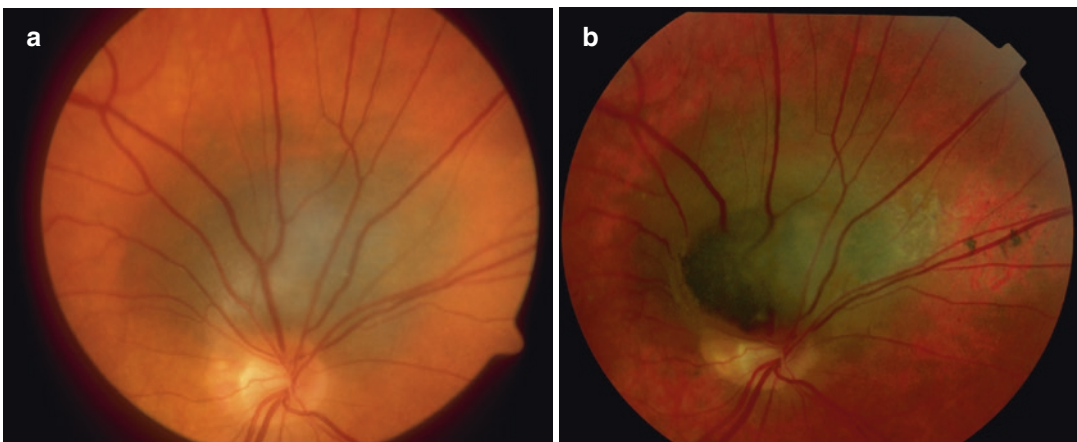
**Fig. 1.4** Techniques of transillumination. Tumor extension assessed by trans-pupillary transillumination (a), trans-ocular transillumination (b), and trans-scleral transillumination (c). Note the exaggeration of posterior tumor extension with trans-pupillary transillumination [Reprinted from Damato [2]. With permission from Elsevier]



**Fig. 1.5** Color photos of the metastasis from a lung adenocarcinoma in a 47-year-old woman. The tumor appears pigmented with the Optos camera (a) but not with the Topcon (b)



**Fig. 1.6** Color photos of a choroidal hemangioma photographed with the Panoret (a), Optos (b), and Topcon (c)



**Fig. 1.7** Sequential color photographs of the right fundus of a 60-year-old man showing growth of a melanocytic tumor over a period of 13 years. Tumor appearances in

2000 (a) and in 2013 (b), with rupture of Bruch's membrane and development of a collar-stud shape, with minimal lateral extension

tent magnification or light exposure. Pseudo-growth can also occur because of retinal flattening, scleral flattening, and extension of secondary changes in the overlying retinal pigment epithelium [5].

---

### Ancillary Tests

Ancillary investigations such as color photography, autofluorescence imaging, optical coherence tomography, angiography, and ultrasonography are discussed in detail elsewhere in this series [6].

---

### Conclusion

The different examination techniques described in this chapter need to be used selectively. Each requires special expertise in performing the test

and to ensure that the results are interpreted properly.

---

### References

1. Bailey IL, Lovie JE. New design principles for visual acuity letter charts. *Am J Optom Physiol Optic.* 1976;53(11):740–5.
2. Damato B. *Ocular tumours: diagnosis and treatment.* Oxford: Butterworth-Heinemann; 2000.
3. Kernt M, Schaller UC, Stumpf C, et al. Choroidal pigmented lesions imaged by ultra-wide-field scanning laser ophthalmoscopy with two laser wavelengths (Optomap). *Clin Ophthalmol.* 2010;4:829–36.
4. Heimann H, Jmor F, Damato B. Imaging of retinal and choroidal vascular tumours. *Eye (Lond).* 2013;27(2):208–16.
5. Schalenbourg A, Zografos L. Pitfalls in colour photography of choroidal tumours. *Eye (Lond).* 2013;27(2):224–9.
6. Singh AD, Damato B, editors. *Clinical ophthalmic oncology. Basic principles and diagnostic techniques.* 3rd ed. Berlin/Heidelberg: Springer; 2019.



## Classification of Uveal Tumors

2

Bertil E. Damato and Sarah E. Coupland

### Introduction

Tumors of the same class should share a unique combination of features, which distinguishes them from all other classes [1, 2]. Classification, therefore, is the process of defining different tumor entities and correlating these with each other in a hierarchical manner based on the putative cell of origin. Classification also involves “grading” of tumor cell morphological features and consideration of their immunohistochemical and genetic profiles. It does not include tumor “staging,” which determines the extent of tumor involvement and hence the type of treatment required (i.e., local versus systemic treatment).

Tumor classification has several uses. It can help the clinician to consider all relevant conditions when preparing a differential diagnosis. It can improve prognostication, by predicting how the tumor is likely to behave. This, in turn, can enhance treatment planning and enables proper evaluation of the results of treatment. Tumor classification also improves communication by

allowing standardization of disease categorization in multicenter studies. Classification is also valuable in research, contributing to investigations in tumor biology (Box 2.1).

### Box 2.1. Classification of Uveal Tumors

- Classification of tumors contributes to diagnosis, prognostication, treatment planning, evaluation of treatment results, communication between treatment centers, and oncological research.
- Tumors can be classified according to location, etiology, histopathology, histogenesis, and other methods.
- Each classification has its advantages and disadvantages in any particular situation so that different classification methods complement each other.
- Tumor classification must be distinguished from staging.

B. E. Damato (✉)  
Nuffield Department of Clinical Neurosciences,  
University of Oxford, John Radcliffe Hospital,  
Oxford, UK  
e-mail: [bertil.damato@nhs.net](mailto:bertil.damato@nhs.net)

S. E. Coupland  
Department of Molecular and Clinical Cancer  
Medicine, Institute of Translational Medicine,  
University of Liverpool, Liverpool, Merseyside, UK  
e-mail: [S.E.Coupland@liverpool.ac.uk](mailto:S.E.Coupland@liverpool.ac.uk)

### Classification of Uveal Tumors

Uveal tumors can be classified according to location, etiology, histopathology, histogenesis, genotype, and various other ontological methods. Each approach has its advantages and limitations.

A classification based on tumor location within the uvea would need to mention some tumors more than once if these can arise at different sites, and, furthermore, it can be impossible to locate the origin of an extensive tumor. A classification that is superior in one situation may not be useful in other circumstances. For example, a histopathologic classification is helpful in a pathology laboratory but of limited value in an ophthalmic clinic when the patient is first seen, that is, before the tissue has been examined histologically.

This chapter considers some conditions that are not strictly uveal, because these might be mistaken for a uveal tumor. For example, adenomas, adenocarcinomas, congenital hypertrophy of the retinal pigment epithelium, and iris cysts are all epithelial but need to be included in the differential diagnosis of several uveal tumors. For the same reasons, conditions, such as varix of the vortex vein ampulla, are mentioned, even if they are not neoplasms at all.

Strictly speaking, the lists provided are not classifications, because they include tumors that are not biologically, clinically, and histologically related. In any case, it is hoped that this review will make it easier for clinicians to recall all relevant conditions in the differential diagnosis when the need arises, a mental feat that is facilitated by categorizing the different tumors and “pseudotumors” into meaningful groups.

---

## Etiologic Classification

This system categorizes uveal tumors according to their underlying causes, that is, as congenital, traumatic, inflammatory, neoplastic, degenerative, and idiopathic (Table 2.1). This is by no means an exhaustive list. First, the anatomical listing is only approximate, because tumors can arise in atypical locations. Second, the etiology of some tumors is not known (e.g., choroidal osteomas) (Fig. 2.1). It is important to appreciate that terminology may also influence clinical management inappropriately. For example, the term “suspicious nevus” may encourage passive clinical management, whereas if the same lesion is called

“suspicious melanoma,” it is perhaps more likely to be treated. It may therefore be preferable to refer to an equivocal melanocytic tumor as an “indeterminate melanocytic tumor” or “melanocytic tumor of unknown malignancy.” Whether such a tumor is nevus, melanoma, or indeterminate is, of course, subjective if diagnosis is based on ophthalmoscopy alone. Finally, some tumors such as neurilemmoma, neurofibroma, and leiomyoma are classified separately despite being clinically indistinguishable.

---

## Histopathologic Classification

Histopathologic classification categorizes uveal neoplasms according to their cellular morphology, immunohistochemical, and genetic profiles. The World Health Organization (WHO) Classification of Tumours of the Eye has classified uveal tumors according to (a) anatomical site, (b) histologic type, and (c) genetic profiles [3]. This classification was developed by pathologists and ophthalmologists, specifically for diagnosing tumors based on histopathologic material. It provides differential diagnoses for each entity, including those that are nonneoplastic, such as inflammation or degenerative conditions. A summary of the WHO uveal tumor classification according to cell of origin is provided in Table 2.2.

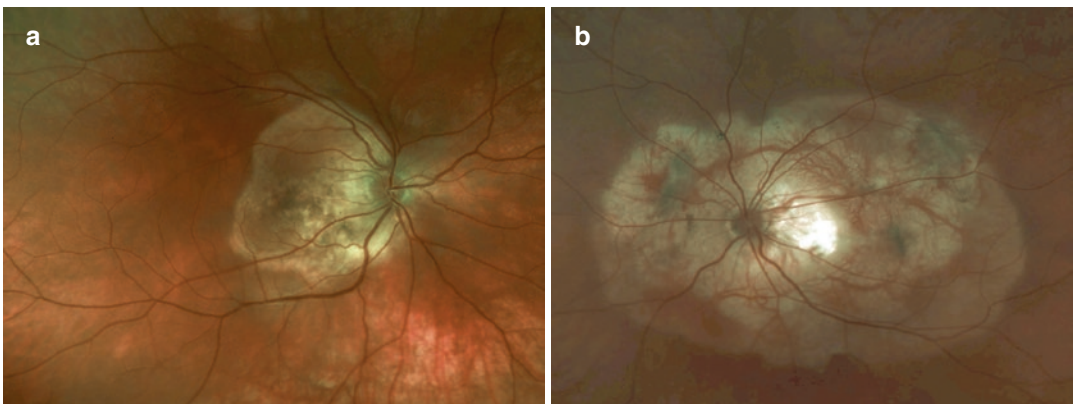
---

## Histogenetic Classification

Histogenetic classification groups tumors hierarchically according to their embryonic lineage, with tumors being subclassified according to whether they originate from ectodermal, endodermal, or mesodermal cells [2]. Tumors are further subclassified according to whether they arise from primitive cells (e.g., totipotent cells forming teratomas) or differentiated cells (e.g., melanocytes). Proponents of this biological system of classification argue that it is simple, comprehensive, and capable of developing as molecular biology improves knowledge about different tumor types. Another advantage of this classification is that tumors with the same lineage

**Table 2.1** Uveal tumors classified according to pathogenesis and location

Category		Subtype	Location		
			Iris	Ciliary body	Choroid
Congenital	Hamartoma	Lisch nodules	Y		
	Choristoma	Lacrimal gland choristoma	Y	Y	
		Osseous choristoma			Y
		Stromal iris cyst	Y		
Inflammatory	Infectious	Granuloma (e.g., Tuberculosis)	Y	Y	Y
	Noninfectious	Sarcoidosis	Y	Y	Y
		Juvenile xanthogranuloma	Y		
		Scleritis		Y	Y
		Uveal effusion		Y	Y
Neoplastic/ Hyperplastic	Melanocytes	Melanocytic nevus	Y	Y	Y
		Melanocytosis	Y	Y	Y
		Melanocytoma	Y	Y	Y
		Bilat. diffuse uveal melanocytic hyperplasia		Y	Y
	Blood vessels	Circumscribed hemangioma			Y
		Diffuse hemangioma		Y	Y
		Hemangiopericytoma	Y		
		Racemose angioma	Y		
	Fibroblasts	Neurofibroma		Y	Y
	Neural tissue	Neurilemmoma		Y	Y
	Muscle	Leiomyoma	Y	Y	Y
		Mesectodermal leiomyoma	Y	Y	
	Lymphocytes	Reactive lymphoid hyperplasia or chronic inflammation	Y	Y	Y
		Melanoma	Y	Y	Y
	Muscle	Rhabdomyosarcoma	Y	Y	
	Secondary	Melanoma/carcinoma	Y	Y	Y
	Hemopoietic	Lymphoma	Y	Y	Y
		Leukemia	Y	Y	Y
	Metastatic	Carcinoma/sarcoma	Y	Y	Y
	Traumatic	Foreign body	Y	Y	Y
Suprachoroidal hematoma				Y	
Degenerative	Disciform lesion (from choroidal neovascularization)			Y	
	Sclerchoroidal calcification			Y	
Idiopathic	Varicose vortex vein			Y	

**Fig. 2.1** Choroidal osteomas in the right eye (a) and left eye (b) of a 15-year-old woman. The etiology is not known as these tumors can be bilateral and have been reported in siblings

**Table 2.2** Pathologic classification of uveal tumors

Categories	Subtype		
	Benign	Malignant	
		Primary	Secondary
Melanocytes	Melanocytosis	Melanoma	Conjunctival melanoma
	Melanocytoma		
	Melanocytic nevus		
	Diffuse melanocytic hyperplasia		
Blood vessels	Hemangioma		
	Hemangiopericytoma		
Nerves	Schwannoma		
Smooth muscle	Leiomyoma		
	Mesectodermal leiomyoma		
Striated muscle		Rhabdomyosarcoma	
Fibroblasts	Neurofibroma		
Histiocytes	Juvenile xanthogranuloma		
Lymphocytes	Lymphocytic proliferation	Lymphoma	Lymphoma
Ectopic tissue	Lacrimal gland choristoma		Metastatic carcinoma
	Osteoma		Metastatic sarcoma

tend to share behavioral similarities. Histogenetic classification is not widely used for uveal tumors as the majority of uveal tumors are neuroectodermal or mesodermal in origin.

### Genotypic “Classification”

Tumors of the same class that seem identical on histology can behave very differently from each other. With developments in molecular biology, it has become possible to correlate tumor behavior with genetic aberrations and other novel characteristics. These advances have raised hopes of improving tumor classification.

Molecular studies and microarray technology reveal marked differences between uveal melanomas, which have differing metastatic potential [4, 7, 8]. For example, metastatic disease from uveal melanoma occurs almost exclusively in patients whose tumor shows chromosome 3 loss, *BAP1* mutations, and/or a class 2 gene expression profile [5–7]. Purists would argue that such categorizations or subgroupings actually constitute “discriminant analysis” rather than a “classification” [1]. This is because it appears that uveal melanomas may in rare cases undergo high-grade transformation from disomy 3 to monosomy 3 type, possibly as a result of a clonal

evolution and dominance [9]. A fundamental principle of tumor classification is that one class of tumor cannot transform into another class [1]. Categorization of uveal melanomas into different “classes” according to their gene expression profile [10] is, strictly speaking, incorrect, and perhaps should be considered as molecularly distinct subsets, as proposed by The Cancer Genome Atlas (TCGA) [7].

Different cancers can have the same genetic aberrations, so that they respond similarly to the same therapeutic agents. There is scope for classifying or subclassifying cancers according to their genetic makeup, as was put forward by the TCGA [7].

### TNM Staging

The TNM (Tumor, Node, Metastasis) staging system of the American Joint Committee on Cancer (AJCC) categorizes tumors anatomically according to the extent of the primary tumor and the presence or absence of lymph node involvement and metastasis [11, 12]. Clinical T staging of ciliary body and choroidal melanomas first groups tumors into size categories according to tumor thickness and basal diameter. The size categories are then integrated with ciliary body involvement and

extraocular spread to group tumors into seven prognostic stages (I, IIA–B, IIIA–C, and IV) according to 10-year survival rates [13].

The AJCC TNM staging system has recently been revised so as to incorporate nonanatomical factors, such as mitotic count, to enhance prognostication. Staging is therefore “clinical” or “pathologic” or both. The TNM staging manual recommends collecting data on key prognostic factors, such as chromosomal alterations, even though these are not included in staging algorithms.

The AJCC manual describes “Stage Classifications,” such as “Clinical,” “Pathologic,” “Post-therapy,” “Re-treatment,” and “Autopsy.” The manual therefore refers to “Clinical Classification,” “Pathologic Classification,” and so on. These different classifications enable patients to be grouped prognostically at different stages in their care pathway.

## Conclusions

Tumor classification is constantly evolving as advancing knowledge changes our perception about what makes a class of tumors unique and how that class relates to other groups in the hierarchy. Different classifications can complement each other, as seen with histologic and clinical groupings. Nevertheless, measures should be taken to ensure that alternative classifications match each other as closely as possible so that ambiguity and misunderstanding are avoided. There is no escaping the fact that terminology and semantics are important. It is essential to distinguish between factors such as class, grade, and stage of tumor, if the benefits of tumor groupings are to be maximized.

## References

1. Berman JJ. Tumor classification: molecular analysis meets Aristotle. *BMC Cancer*. 2004;4:10.
2. Berman J. Modern classification of neoplasms: reconciling differences between morphologic and molecular approaches. *BMC Cancer*. 2005;5:100.
3. Grossniklaus HE, Eberhart CG, Kivelä TT. WHO classification of tumours of the eye. 2018;12:4th ed. Lyon: WHO.
4. Coupland SE, Lake SL, Zeschnigk M, et al. Molecular pathology of uveal melanoma. *Eye (Lond)*. 2013;27(2):230–42.
5. Damato B, Dopierala JA, Coupland SE. Genotypic profiling of 452 choroidal melanomas with multiplex ligation-dependent probe amplification. *Clin Cancer Res*. 2010;16(24):6083–92.
6. Onken MD, Worley LA, Char DH, et al. Collaborative Ocular Oncology Group report number 1: prospective validation of a multi-gene prognostic assay in uveal melanoma. *Ophthalmology*. 2012;119:1596–603.
7. Cancer Genome Atlas Research Network. The Cancer Genome Atlas Pan-Cancer analysis project. *Nat Genet*. 2013;45(10):1113–20.
8. Robertson AG, Shih J, Yau C, et al. Integrative analysis identifies four molecular and clinical subsets in uveal melanoma. *Cancer Cell*. 2017;32(2):204–20.
9. Callejo SA, Dopierala J, Coupland SE, et al. Sudden growth of a choroidal melanoma and multiplex ligation-dependent probe amplification findings suggesting late transformation to monosomy 3 type. *Arch Ophthalmol*. 2011;129(7):958–60.
10. Onken MD, Worley LA, Ehlers JP, et al. Gene expression profiling in uveal melanoma reveals two molecular classes and predicts metastatic death. *Cancer Res*. 2004;64(20):7205–9.
11. Gospodarowicz MK, Miller D, Groome PA, et al. The process for continuous improvement of the TNM classification. *Cancer*. 2004;100(1):1–5.
12. American Joint Committee on Cancer. AJCC cancer staging manual. 7th ed. New York: Springer; 2010.
13. Kujala E, Damato B, Coupland SE, et al. Staging of ciliary body and choroidal melanomas based on anatomic extent. *J Clin Oncol*. 2013;31(22):2825–31.



# Benign Melanocytic Tumors of the Uvea

3

Miguel Materin and Arun D. Singh

## Iris Nevus

### Introduction

Iris nevus is a stromal lesion and therefore quite different from an iris freckle, in which melanocytes collect only superficially, without stromal involvement. Iris freckles can be seen in up to 60% of population, whereas nevi are less common (4–6%) [1]. Both iris freckles and nevi are more frequent in light-colored irises [1]. Patients with dysplastic nevus syndrome may have a tendency to develop iris nevi [2, 3]. Although an association between iris nevi and uveal melanomas has been reported, [4] it is doubtful whether these two conditions are genuinely associated [1]. Recent studies have shown a potential role of a number of pigmented iris lesions as biomarkers for sun exposure and risk for cutaneous malignancies with higher risk in younger patients (<40 years of age) [5, 6].

M. Materin  
Ophthalmic Oncology, Duke University Eye Center,  
Duke Cancer Institute, Durham, NC, USA

A. D. Singh (✉)  
Department of Ophthalmic Oncology, Cole Eye  
Institute, Cleveland Clinic, Cleveland, OH, USA  
e-mail: [singha@ccf.org](mailto:singha@ccf.org)

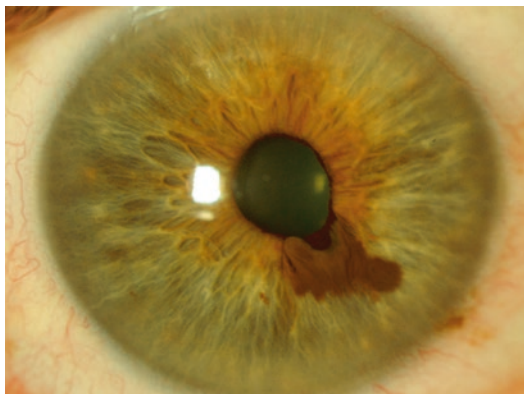
## Etiology and Pathology

Most circumscribed iris nevi are composed of intra-stromal, bland, spindle cells [7]. In some cases, the lesion breaks through to the iris surface, to form a plaque or nodule. The diffuse iris nevus represents hyperplasia and hypertrophy of stromal melanocytes without mass effect. Other variants include epithelioid cell nevus, which is composed of bland, hypopigmented, epithelioid cells with a clear vacuolated cytoplasm, [8, 9] and balloon cell nevus, composed of cells with a clear cytoplasm [10].

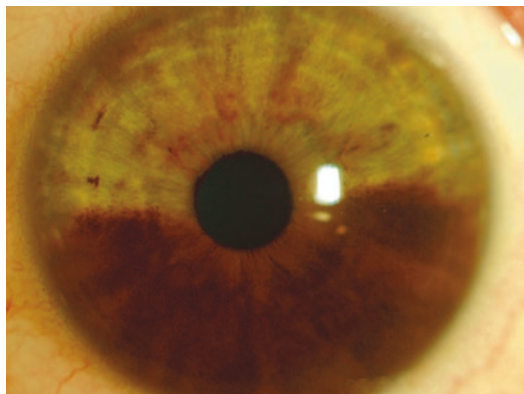
## Clinical Features

Iris nevus is typically solitary and circumscribed (Fig. 3.1). Most nevi are located in the lower quadrants of the iris. Their color varies from tan to dark brown. A nevus that is very dark and almost black is more likely to be a melanocytoma. Intrinsic vasculature may be visible if the tumor is only lightly pigmented.

Pupillary changes such as corectopia, irregularity of the margin, and ectropion iridis may occur with nevi involving the pupillary margin and do not imply malignancy. Both ectropion and corectopia represent signs of chronicity. Similarly, extension into the trabecular meshwork does not signify malignant change. There may be progressive accumulation of pigment in



**Fig. 3.1** Slit lamp photograph of a circumscripted iris nevus demonstrating localized iris thickening, pupillary distortion, and ectropion iridis



**Fig. 3.2** Slit lamp photograph of a diffuse iris nevus involving lower half of the iris in association with oculo (dermal) melanocytosis

the trabecular meshwork, especially with melanocytoma (see below). Such pigment in the angle may be localized to the vicinity of the tumor or may be diffuse, giving rise to secondary glaucoma. Pigment shedding appears smooth on gonioscopy, unlike tumor seeding from a melanoma, which tends to form irregular nodular elevations in the trabecular meshwork.

---

### Clinical Variants

In addition to commonly observed circumscripted iris nevi described above, several clinical variants of iris nevus are well recognized.

---

#### Tapioca Iris Nevus

This is a multinodular, amelanotic, or lightly pigmented iris nevus, which resembles tapioca grains.

---

#### Diffuse Iris Nevus

A diffuse iris nevus may be sectorial or may involve the whole iris (Fig. 3.2). This variety is usually observed in association with ocular melanocytosis [11].

---

#### Iris Nevus Syndrome

A rare variant of iridocorneal endothelial syndrome (Fig. 3.3), the iris nevus syndrome (Cogan-Reese syndrome), is the result of corneal

endothelial overgrowth across the angle and over the iris surface, which gives rise to multiple, small, iris nodules and secondary glaucoma [12, 13].

---

#### Iris Mammillations

The iris mammillations are multiple, dark-brown, nodular elevations on the iris seen commonly in darkly pigmented races or in association with oculo(dermal) melanocytosis (Fig. 3.4) [14, 15].

---

#### Lisch Nodules

Lisch nodules occur in patients with neurofibromatosis type 1. They consist of small collections of melanocytes and are histologically indistinguishable from common nevi, except that they are perhaps more superficial [16].

---

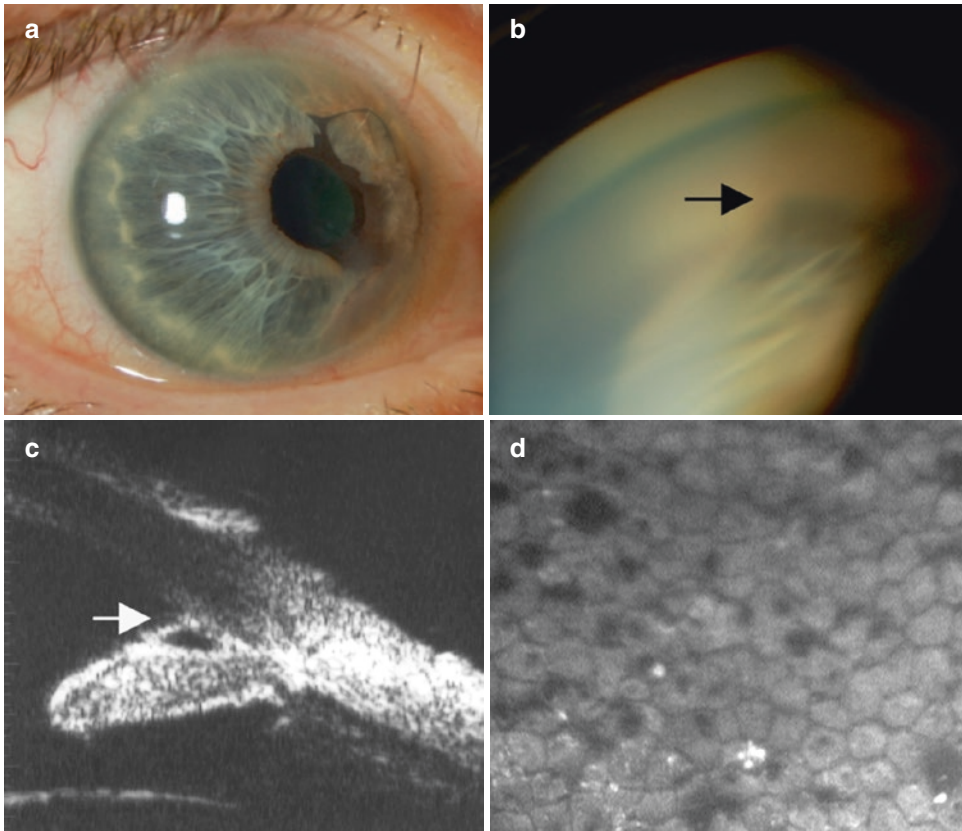
#### Aggressive Nevi of Childhood

As with similar lesions in other parts of the body, iris nevi in children can enlarge rapidly. Such lesions have been observed both sporadically [17] and in the familial setting [18].

---

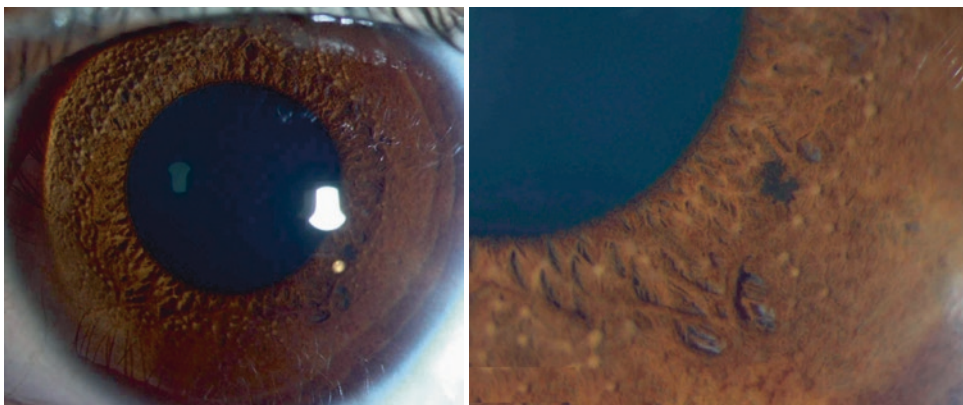
### Diagnostic Evaluation

Detailed anterior segment evaluation, including gonioscopy, is essential, with photographic documentation if possible. High-frequency ultrasound biomicroscopy (UBM) provides quantitative



**Fig. 3.3** A 76-year-old white male with abnormal iris pigmentation of the right eye initially noted 20 years ago. Visual acuity was 20/70 with normal IOP in the right eye. The right eye examination was remarkable for corectopia and oval elongation of the pupil (**a**). There was evidence of pigment migration from the posterior margin of the iris across the anterior surface into the nasal limbal cornea. The cornea appeared to be decompensated near the three o'clock limbus corresponding to an area of calcium deposits. Peripheral anterior synechiae extended from two to five o'clock position

with evidence of iridoschisis inferior nasally. Gonioscopic evaluation confirmed the presence of broad based anterior synechiae (**b**). Vascularization of the iris or angle was absent. Ultrasound biomicroscopy demonstrated anterior synechiae with iridoschisis (arrow). (**c**). Note absence of iris mass. Specular microscopy showed slightly pleomorphic endothelial cells but did not have the hyperreflective nuclei or dark-light reversal described in some patients with ICE syndrome (**d**). (Reprinted with permission from Bryn Mawr Communications: Aponte et al. [142])



**Fig. 3.4** Multiple dark-brown, nodular iris elevations (bilateral) in a Hispanic teenager