

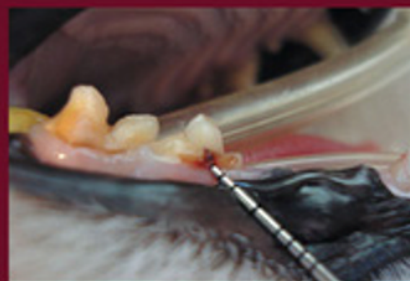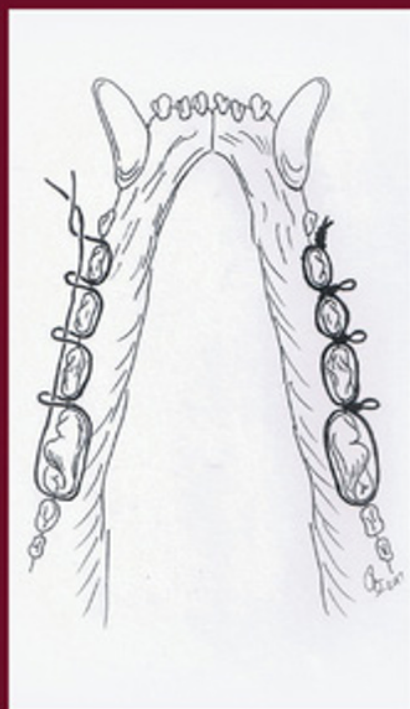
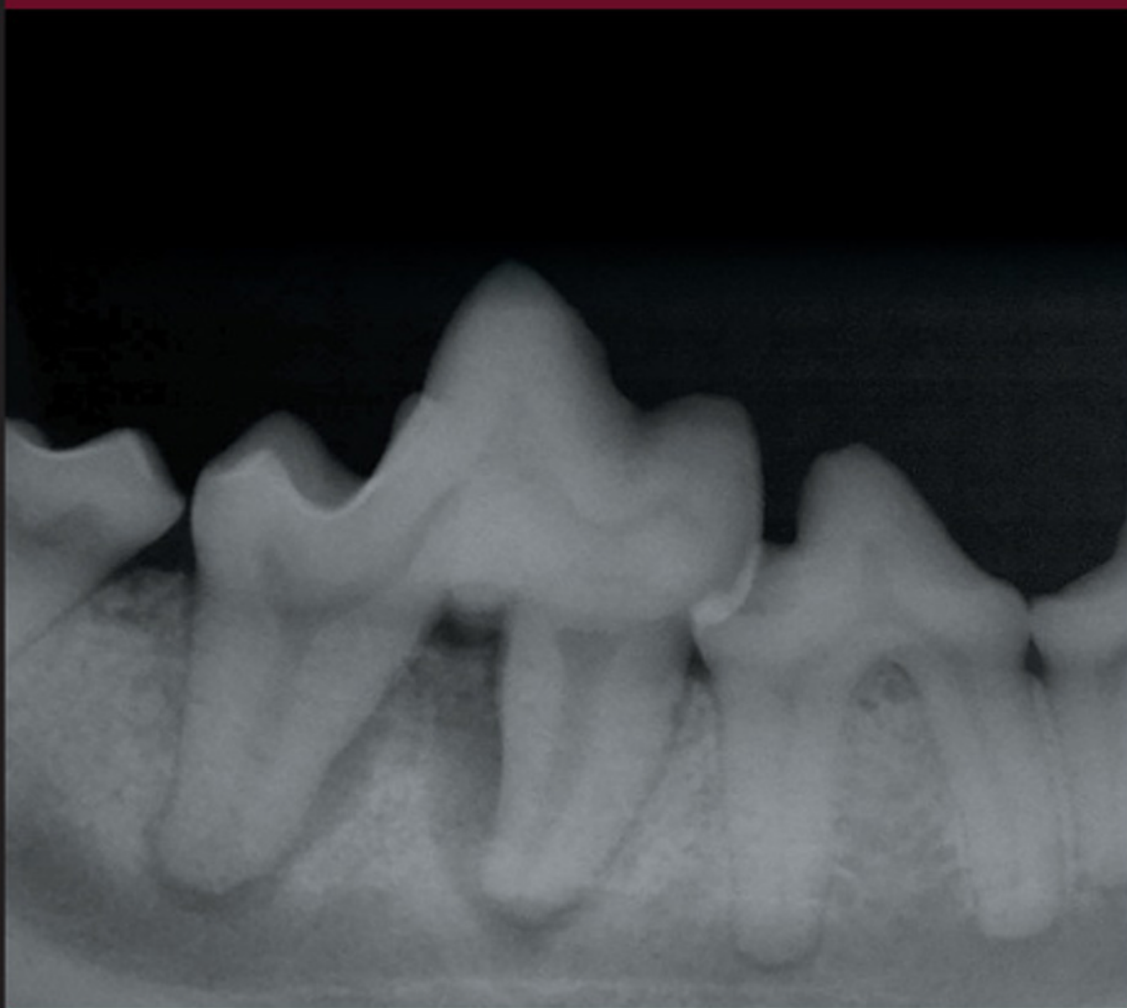# Wiggs's

Second Edition

# Veterinary Dentistry

Principles and Practice

Edited by Heidi B. Lobprise and Johnathon R. (Bert) Dodd



WILEY Blackwell



## Wiggs's Veterinary Dentistry



# Wiggs's Veterinary Dentistry

Principles and Practice

Second Edition

*Edited by*

*Heidi B. Lobprise, DVM, DAVDC*  
*Main Street Veterinary Hospital and Dental Clinic*  
*Flower Mound*  
*TX, USA*

*and*

*Johnathon R. (Bert) Dodd, DVM, FAVD, DAVDC*  
*Veterinary Dentistry*  
*Texas A&M University*  
*College Station*  
*TX, USA*

**WILEY** Blackwell

This edition first published 2019  
© 2019 John Wiley & Sons, Inc.

*Edition History*  
Lippincott (1e, 1997)

All rights reserved. No part of this publication may be reproduced, stored in a retrieval system, or transmitted, in any form or by any means, electronic, mechanical, photocopying, recording or otherwise, except as permitted by law. Advice on how to obtain permission to reuse material from this title is available at <http://www.wiley.com/go/permissions>.

The right of Heidi B. Lobprise and Johnathon R. (Bert) Dodd to be identified as the authors of the editorial material in this work has been asserted in accordance with law.

*Registered Office*  
John Wiley & Sons, Inc., 111 River Street, Hoboken, NJ 07030, USA

*Editorial Office*  
111 River Street, Hoboken, NJ 07030, USA

For details of our global editorial offices, customer services, and more information about Wiley products visit us at [www.wiley.com](http://www.wiley.com).

Wiley also publishes its books in a variety of electronic formats and by print-on-demand. Some content that appears in standard print versions of this book may not be available in other formats.

*Limit of Liability/Disclaimer of Warranty*

While the publisher and authors have used their best efforts in preparing this work, they make no representations or warranties with respect to the accuracy or completeness of the contents of this work and specifically disclaim all warranties, including without limitation any implied warranties of merchantability or fitness for a particular purpose. No warranty may be created or extended by sales representatives, written sales materials or promotional statements for this work. The fact that an organization, website, or product is referred to in this work as a citation and/or potential source of further information does not mean that the publisher and authors endorse the information or services the organization, website, or product may provide or recommendations it may make. This work is sold with the understanding that the publisher is not engaged in rendering professional services. The advice and strategies contained herein may not be suitable for your situation. You should consult with a specialist where appropriate. Further, readers should be aware that websites listed in this work may have changed or disappeared between when this work was written and when it is read. Neither the publisher nor authors shall be liable for any loss of profit or any other commercial damages, including but not limited to special, incidental, consequential, or other damages.

*Library of Congress Cataloging-in-Publication Data*

Names: Lobprise, Heidi B., editor. | Dodd, Johnathon R., editor.  
Title: Wiggs's veterinary dentistry : principles and practice / edited by Heidi B. Lobprise and Johnathon R. Dodd.  
Other titles: Veterinary dentistry  
Description: Second edition. | Hoboken, NJ : Wiley-Blackwell, 2018. |  
    Preceded by Veterinary dentistry / editors, Robert B. Wiggs, Heidi B. Lobprise. c1997. |  
    Includes bibliographical references and index. |  
Identifiers: LCCN 2018026806 (print) | LCCN 2018027769 (ebook) |  
    ISBN 9781118816165 (Adobe PDF) | ISBN 9781118816080 (ePub) |  
    ISBN 9781118816127 (hardcover)  
Subjects: LCSH: Veterinary dentistry. | MESH: Dentistry--veterinary |  
    Veterinary Medicine | Stomatognathic Diseases--veterinary  
Classification: LCC SF867 (ebook) | LCC SF867 .V47 2019 (print) | NLM SF 867 |  
    DDC 636.089/76--dc23  
LC record available at <https://lccn.loc.gov/2018026806>

Cover Design: Wiley  
Cover Images: © Jo Banyard; © Bonnie Shope; © Roberto Fecchio

Set in 10/12pt Warnock by SPi Global, Pondicherry, India

10 9 8 7 6 5 4 3 2 1

## Dedication

“Dentistry has emerged over the last twenty years as a distinct and significant part of clinical veterinary medicine. This emergence as a prominent and accepted science has not come easily nor without controversy in the modality of treatments and in organization. The veterinary dental pioneers faced numerous scientific and technical barriers, as well as lack of acceptance on occasion, by colleagues. However, science embraces and accepts science, and as research continues to link oral health with general health, dentistry is becoming more widely appraised and appreciated.”

This was the opening paragraph from the first edition of this book published by Robert B. Wiggs and Heidi B. Lobprise twenty years ago. So much of that paragraph is still true today; however, because of the foresight of dental pioneers like Bob Wiggs, Don Ross, Tom Mulligan, Sandy Manfra Maretta, Ben Colmery, Chuck Williams, Colin Harvey, Peter Emily, Steve Holmstrom, and Ed Eisner, the practice of veterinary dentistry today is “widely appraised and appreciated” over these last 40 years.

This book is dedicated to the memory of Robert Bruce (Bob) Wiggs for his vision, his knowledge, his perseverance, and his unending selflessness to advance the level of dentistry in private (and specialty) practice throughout the world. His memory is in the hearts of countless veterinarians whose personal knowledge and skills improved because of Bob’s willingness to share with anyone who would ask for help. Bob never asked for anything in return.

Mike Peak had this to say about Bob: “When I started my residency with Dr. Wiggs, I was pretty green and no doubt had a lot to learn. I had been ‘doing’ dentistry for 4–5 years before beginning the residency and knew ‘how’ to do procedures, but didn’t have the depth of understanding and knowledge ‘why’ certain procedures were done one way vs. another. I can remember Dr. Wiggs helping me understand certain oral pathologies and treatments, that at the time, in some cases seemed unorthodox. On more than one occasion, I thought for certain he was wrong about what he was telling me. I can

remember thinking, ‘this just can’t be right’ or ‘there’s no way he’s right about that’. However, once I researched the literature, or we saw the case through its entirety, it turned out he was right EVERY time. It is amazing, even to this day, I see diseases that have now been more thoroughly investigated and he continues to be right!”

Another colleague, Gregg DuPont, added, “Dr. Bob Wiggs, the lead co-author of the first edition of this book, inspired countless veterinarians to increase their knowledge of dentistry and to improve their level of dental care for their patients. He shared his skills and his wealth of knowledge readily and selflessly with anyone who wanted to learn more about veterinary dentistry. Bob was a good friend who possessed an uncommon combination of knowledge, generosity, and down-to-earth common sense that made time spent together delightful. The field of veterinary dentistry is a better one for his contributions, actions and interactions.”

According to Ed Eisner and Steve Holmstrom, Robert Bruce Wiggs was a renaissance man. He was a pioneer of the 1970s dental evolution in veterinary medicine. His closest friends saw many sides of Bob. He was, on the one hand, very proud of his Scottish heritage (Bruce the Fierce), and his Texas roots (1st generation Texas Ranger Ben Wills, known for his integrity as well as his toughness). As a member of one of the “Indian Companies”, Ranger Wills helped bring in alive the infamous Comanche renegade, Quantos Parker, in the 1860s.

Bob practiced with a high level of ethics and professional discipline, as well as being known for his dry sense of humor. In the 1980s, before the advent of internet “list serves”, Bob organized a dental support group that he nicknamed after one of his favorite comedy groups, The Three Stooges. There were actually five stooges, and this group shared the nuances of all stooges being Presidents of the newly forming American Veterinary Dental College, all were national and international speakers, and all were published authors. The Stooges also boasted a fierce professional football rivalry, Larry championing his Dallas Cowboys, Curly the Denver Broncos, Moe the SF 49ers, Shemp the Philadelphia Eagles, and Curly Joe

the Seattle Seahawks. On the occasion of a Cowboys loss, Larry was a good sport. The Stooges were also known for their practical jokes. Among other pranks, they traditionally, at the annual Veterinary Dental Conference, short-sheeted the bed of the incoming Dental College President. When it was Bob's turn, as incoming president, and he was cheerfully asked how he had slept the night before, Bob said "very soundly, thank you". He had slept on top of the covers, innocent of the ongoing shenanigans. There will never be another Bob, or "Larry".

On a more serious note, Dr. Wiggs was a meticulous innovator of dental instruments, hammering out the first set of winged elevators for his small animal dental practice. He also headed up the laboratory animal care unit at

the Baylor College of Dentistry in Dallas (now known as the Texas A & M College of Dentistry), and donated his time and expertise in providing dental care for the animals at the Dallas Zoo, the Fort Worth Zoo, and area wild animal sanctuaries. He had gifted hands for oral surgery and the high quality of his procedures were acknowledged both throughout the United States and abroad. Animals of all species benefited by his dental expertise and tireless efforts on their behalf.

Dr. Bob Wiggs' ability to personally share his knowledge of dentistry ceased on November 29, 2009, but his influence on all of us will continue indefinitely.

*Heidi B. Lobprise, DVM*  
*Johnathon R. (Bert) Dodd, DVM*



## Contents

- Foreword *ix*  
List of Contributors *xi*
- 1 **Oral Anatomy and Physiology** 1  
*Matthew Lemmons and Donald Beebe*
  - 2 **Oral Examination and Diagnosis** 25  
*Jan Bellows*
  - 3 **Oral Radiology and Imaging** 41  
*Brook Niemiec*
  - 4 **Developmental Pathology and Pedodontology** 63  
*Bonnie H. Shope, Paul Q. Mitchell, and Diane Carle*
  - 5 **Periodontology** 81  
*Kevin Stepaniuk*
  - 6 **Traumatic Dentoalveolar Injuries** 109  
*Jason Soukup*
  - 7 **Oral and Maxillofacial Tumors, Cysts, and Tumor-Like Lesions** 131  
*Jason Soukup and John Lewis*
  - 8 **General Oral Pathology** 155  
*Heidi B. Lobprise*
  - 9 **Anesthesia and Pain Management** 177  
*Lindsey C. Snyder, Christopher Snyder, and Donald Beebe*
  - 10 **Oral Surgery – Periodontal Surgery** 193  
*Heidi B. Lobprise and Kevin Stepaniuk*
  - 11 **Oral Surgery – Extractions** 229  
*Cynthia Charlier*
  - 12 **Oral Surgery – General** 247  
*Heidi B. Lobprise*
  - 13 **Oral Surgery – Fracture and Trauma Repair** 265  
*Kendall Taney and Christopher Smithson*

- 14 Oral Surgery – Oral and Maxillofacial Tumors 289**  
*Heidi B. Lobprise and Jason Soukup*
  
- 15 Basic Endodontic Therapy 311**  
*Robert C. Boyd*
  
- 16 Advanced Endodontic Therapy 335**  
*Michael Peak and Heidi B. Lobprise*
  
- 17 Restorative Dentistry 357**  
*Anthony Caiafa and Louis Visser*
  
- 18 Crowns and Prosthodontics 387**  
*Curt Coffman, Chris Visser, Jason Soukup, and Michael Peak*
  
- 19 Occlusion and Orthodontics 411**  
*Heidi B. Lobprise*
  
- 20 Domestic Feline Oral and Dental Diseases 439**  
*Alexander M. Reiter, Norman Johnston, Jamie G. Anderson, Maria M. Soltero-Rivera, and Heidi B. Lobprise*
  
- 21 Small Mammal Oral and Dental Diseases 463**  
*Loïc Legendre*
  
- 22 Exotic Animals Oral and Dental Diseases 481**  
*Roberto Fecchio, Marco Antonio Gioso, and Kristin Bannon*
  
- Index 501**

## Foreword

Twenty years is a long time to wait on a second edition, and it took nearly four years to organize the contents of this one. The first edition of *Veterinary Dentistry – Principles and Practice* came out in 1997, largely due in part to the tremendous knowledge and dedication of Dr. Robert Bruce Wiggs (1950–2009). Referred to by some as “the bible” of veterinary dentistry, with no irreverence intended, it was probably the most comprehensive book in that field of topic during that time. Not without its shortcomings, such as a lack of adequate figures and illustrations due to publishing restraints, as well as now aged reference listings, it still provided a wealth of information to many a “student”.

This edition is a melding of keeping as many of the timeless and true concepts and knowledge, with adding in updated and contemporary viewpoints. Of course, as with any text, by the time the ink dries, there will be newer data published electronically and in journals that will update the information provided. This edition literally rests on the shoulders of giants, from the first edition and stellar human dental resources, to the current knowledge provided by current guest contributors.

In particular, distinct efforts were made to further bolster information about anesthesia and pain management (Chapter 9), to examine traumatic dentoalveolar injuries more closely (Chapter 6), and to dedicate a chapter to Oral and Maxillofacial Tumors (Chapter 7, with a separate chapter on related surgery). Other chapters expand on newer techniques and resources such as restorative endodontic (Chapter 16) and periodontal therapy (Chapter 10) and data related to the application of crowns and prosthodontics for dogs (Chapter 18).

Whenever possible, updated terminology (based on the American Veterinary Dental College Nomenclature resources) was integrated, as seen in the feline chapter (Chapter 20), with appropriate abbreviations in tables throughout the book.

There are definitely more images and illustrations than the original edition, but there are still other texts that are known for more complete coverage of specific procedures, such as *Veterinary Dental Techniques* (Holmstrom, Frost, and Eisner) and *Oral and Maxillofacial Surgery in Dogs and Cats* (Verstraete and Lommer). The step-by-step feature of issues of the *Journal of Veterinary Dentistry* is also a good resource for pictorial descriptions, and was utilized in several places in this book as well.

Therefore, as these files are sent to the publisher (interestingly on the day 8 years after Dr. Wiggs’ passing), I look back at these four years with plans for when the next edition will be needed (certainly sooner than 20 years), as the future of veterinary dentistry continues to expand. I played a part in that first edition, though it was but a portion of Dr. Wiggs’ contribution, which is why, with great respect and fond remembrance, we are pleased to launch the modified name of this text – *Wiggs’ Veterinary Dentistry – Principles and Practice*, second edition. I am also pleased and proud to say that the veterinarians involved in this edition have agreed to donate proceeds to the Foundation for Veterinary Dentistry in Dr. Wiggs’ name and to the Robert B Wiggs endowed scholarship at Texas A&M University.

*Respectfully submitted*  
Heidi B. Lobprise, DVM, DAVDC



## List of Contributors

***Jamie G. Anderson, DVM, MS, DAVDC, DACVIM***

Sacramento Veterinary Dental Services  
Rancho Cordova  
CA, USA

***Kristin Bannon, DVM, FAVD, DAVDC***

Veterinary Dentistry and Oral Surgery of  
New Mexico, LLC  
Algodones  
NM, USA

***Donald Beebe, DVM, DAVDC***

Apex Dog and Cat Dentistry  
Englewood  
CO, USA

***Jan Bellows, DVM, Dipl. AVDC, ABVP (canine and feline)***

All Pets Dental  
Weston  
FL, USA

***Robert C. Boyd, DVM, DAVDC***

Montgomery  
TX, USA

***Anthony Caiafa, BVSc, BDS, MANZCVS***

School of Veterinary and Biomedical Sciences  
James Cook University  
Townsville, Queensland  
Australia

***Diane Carle, DVM, DAVDC***

Animal Medical Center of Seattle  
Seattle  
WA, USA

***Cynthia Charlier, DVM, DAVDC***

VDENT Veterinary Dental Education  
Networking and Training  
Elgin  
IL, USA

***Curt Coffman, DVM, FAVD, DAVDC***

Arizona Veterinary Dental Specialists  
Scottsdale  
AZ, USA

***Johnathon R. (Bert) Dodd, DVM, FAVD, DAVDC***

Veterinary Dentistry  
Texas A&M University  
College Station  
TX, USA

***Roberto Fecchio, DVM, MSc., PhD.***

Safari Co. – Zoo and Exotic Animals Dental  
Consultant  
São Paulo/SP  
Brazil

***Marco Antonio Gioso, DVM, DDS, DAVDC***

Laboratório de Odontologia Comparada da FMVZ  
University of São Paulo  
São Paulo, Brazil

***Norman Johnston, FRCVS, DAVDC, DEVDC***

DentalVets  
North Berwick  
Scotland, UK

***Loïc Legendre, DVM, DAVDC, DEVDC***

Northwest Veterinary Dental Services Ltd  
North Vancouver  
British Columbia, Canada

***Matthew Lemmons, DVM, DAVDC***

MedVet Medical and Cancer Centers for Pets  
Indianapolis  
IN, USA

***John Lewis, VMD, FAVD, DAVDC***

Veterinary Dentistry Specialists  
Chadds Ford, PA

**Heidi B. Lobprise, DVM, DAVDC**

Main Street Veterinary Hospital and Dental Clinic  
Flower Mound  
TX, USA

**Paul Q. Mitchell, DVM, DAVDC**

Veterinary Dental Services  
North Attleboro  
MA, USA

**Brook Niemiec, DVM, DAVDC**

Veterinary Dental Specialties and Oral Surgery  
San Diego  
CA, USA

**Michael Peak, DVM, DAVDC**

Tampa Bay Veterinary Specialists  
Largo  
FL, USA

**Alexander M. Reiter, Dipl. Tzt., Dr. med. vet., DAVDC, DEVDC**

School of Veterinary Medicine  
University of Pennsylvania  
Philadelphia  
PA, USA

**Bonnie H. Shope, VMD, DAVDC**

Veterinary Dental Services, LLC  
Boxborough  
MA, USA

**Christopher Smithson, DVM, DAVDC**

The Pet Dentist at Tampa Bay  
Wesley Chapel  
FL, USA

**Christopher Snyder, DVM, DAVDC**

School of Veterinary Medicine  
University of Wisconsin-Madison  
Madison  
WI, USA

**Lindsey C. Snyder, DVM, MS, DACVAA**

School of Veterinary Medicine  
University of Wisconsin-Madison  
Madison  
WI, USA

**Maria M. Soltero-Rivera, DVM, DAVDC**

School of Veterinary Medicine  
University of Pennsylvania  
Philadelphia  
PA, USA

**Jason Soukup, DVM, DAVDC**

School of Veterinary Medicine  
University of Wisconsin-Madison  
Madison  
WI, USA

**Kevin Stepaniuk, DVM, FAVD, DAVDC**

Veterinary Dentistry Education and Consulting  
Services, LLC  
Ridgefield  
WA, USA

**Kendall Taney, DVM, DAVDC**

Center for Veterinary Dentistry and Oral Surgery  
Gaithersburg  
MD, USA

**Chris Visser, DVM, DAVDC, DEVDC, MRCVS**

Arizona Veterinary Dental Specialists  
Scottsdale  
AZ, USA

**Louis Visser, DDS**

Arizona Veterinary Dental Specialists  
Scottsdale  
AZ, USA

## 1

## Oral Anatomy and Physiology

Matthew Lemmons<sup>1</sup> and Donald Beebe<sup>2</sup>

<sup>1</sup> MedVet Medical and Cancer Centers for Pets, Indianapolis, IN, USA

<sup>2</sup> Apex Dog and Cat Dentistry, Englewood, CO, USA

Within this chapter, the dog will be discussed primarily, although some comparative information will be covered. Related anatomy and variations for other species will be discussed within chapters covering those. It is intended that this chapter serve to provide the foundation knowledge for the chapters that follow.

The practice of veterinary dentistry is concerned with the conservation, reestablishment and/or treatment of dental, paradental, and oral structures. In dealing with their associated problems a fundamental awareness of anatomy and physiology is essential for an understanding of the presence or absence of the abnormal or pathologic structure. Anatomy and physiology are acutely interactive, with anatomy considered the study of structure and physiology that of its function. These deal with bones, muscles, vasculature, nerves, teeth, periodontium, general oral functions, and their development.

### 1.1 General Terms

Dentes decidui – deciduous teeth.

Dentes permanentes – permanent teeth.

Dentes incisivi – incisor teeth.

Dentes canini – canine teeth.

Dentes premolares – premolar teeth.

Dentes molares – molar teeth.

#### 1.1.1 Three Basic Types of Tooth Development

*Monophyodont.* Only one set of teeth that erupt and remain in function throughout life (no deciduous teeth), such as in most rodents (*heterodont*) and dolphins (*homodont*), as currently accepted.

*Polyphyodont.* Many sets of teeth that are continually replaced. Most of these are homodonts. In sharks, the

replacement is generally of a horizontal nature with new teeth developing caudally and moving rostrally. In reptiles, the replacement is generally of a vertical nature with new teeth developing immediately apical to the teeth in current occlusion and replacing them when lost.

*Diphyodont.* Two sets of teeth, one designated deciduous and one permanent. Common to most domesticated animals and man.

#### 1.1.2 Common Terms Used with Diphyodont Tooth Development

*Deciduous teeth (Dentes decidui).* Considered to be the first set of teeth that are shed at some point and replaced by permanent teeth.

*Primary teeth (Dentes primarui).* Considered to be the first set of teeth that are shed at some point and replaced by permanent teeth. Some distractors feel this term is not totally correct because in some species primary teeth are also their permanent teeth, and even in diphyodonts some permanent teeth (i.e., the dog: first premolar and molars) may theoretically also classify as primary, since all teeth may eventually be exfoliated. The term primary is acceptable when speaking to the layperson, but not acceptable in the professional setting.

*Permanent teeth (Dentes permanentes).* The final or lasting set of teeth, that are typically of a very durable nature (opposite of deciduous).

*Nonsuccessional teeth (Nonsuccedaneous).* Permanent teeth that do not succeed a deciduous counterpart. Classically molars of dogs and cats.

*Successional teeth (Succedaneous).* Permanent teeth that replace or succeed a deciduous counterpart. Typically certain diphyodont incisors, canines, or premolars.

*Mixed Dentition.* The transient complement of teeth present in the mouth after eruption of some of the permanent teeth but before all the deciduous teeth are absent. Commonly seen in diphyodonts during the early stages of permanent tooth eruption, until all deciduous teeth have been exfoliated.

### 1.1.3 Two Basic Categories of Tooth Types or Shapes

*Homodont.* All teeth are of the same general shape or type, although size may vary, such as in fish, reptiles, sharks, and some marine mammals.

*Heterodont.* Functionally different types of teeth are represented in the dentition. The domestic dog and cat have heterodont dentition, characterized by incisors, canines, premolars, and molars.

### 1.1.4 Three Common Types of Vertebrate Tooth Anchorage

*Thecodont.* Teeth firmly set in sockets typically using gomphosis, such as dogs, cats, and humans.

*Gomphosis.* A type of fibrous joint in which a conical object is inserted into a socket and held.

*Acrodont.* Teeth are ankylosed directly to the alveolar bone without sockets or true root structure. This type of attachment is not very strong; teeth are lost easily and are replaced by new ones. This formation is common in the order Squamata (lizards and snakes) with the only other teeth formation in this order being pleurodont. Acrodontal tooth attachment is also seen in fish.

*Pleurodont.* Teeth grow from a pocket on the inner side of the jawbone that brings a larger surface area of tooth in contact with the jawbone and hence attachment is stronger, as in amphibians and some lizards. However, this attachment is also not as strong as thecodont anchorage.

### 1.1.5 Two Basic Tooth Crown Types

*Brachydont.* Dentition with a shorter crown to root ratio, as in primates and carnivores. A brachydont tooth has a supragingival crown and a neck just below the gingival margin, and at least one root. An enamel layer covers the crown and extends down to the neck. Cementum is only found below the gingival margin.

*Hypsodont.* Dentition with a longer crown to root ratio, as in cow, horses, and rodents. These teeth have enamel that extends well beyond the gingival margin, which provides extra material to resist wear and tear from feeding on tough and fibrous diets. Cementum and enamel invaginate into a thick layer of dentin.

*Radicular hypsodont* (subdivision of hypsodont). Dentition with true roots, sometimes called closed

rooted, that erupts additional crown through most of life. These teeth eventually close their root apices and cease growth. As teeth are worn down new crown emerges from the submerged reserve crown of the teeth, such as in the molars and premolars of the equine and bovine. Known as continually erupting closed rooted teeth.

*Aradicular hypsodont* (subdivision of hypsodont). Dentition without true roots, sometimes called open rooted, that produces additional crown throughout life. As teeth are worn down new crown emerges from the continually growing teeth, such as in lagomorphs and incisors of rodents. Known as continually growing teeth or open rooted teeth.

### 1.1.6 General Crown Cusp Terms of Cheek Teeth

*Secodont dentition.* Having cheek teeth with cutting tubercles or cusps arranged to provide a cutting or shearing interaction, such as premolars in most carnivores, especially the carnassial teeth.

*Bunodont dentition.* Having cheek teeth with low rounded cusps on the occlusal surface of the crown. Cusps are commonly arranged side by side on the occlusal surface for crushing and grinding, such as molars in primates (including man), bears, and swine.

*Lophodont dentition.* Having cheek teeth with cusps interconnected by ridges or *lophs* of enamel, such as in the rhinoceros and elephant.

*Selenodont dentition.* Having cheek teeth with cusps that form a crescent-shaped ridge pattern, such as in the even-toed ungulates, except swine.

### 1.1.7 Two Types of Jaw Occlusal Overlay

*Isognathous.* Equal jaw widths, in which the premolars and molars of opposing jaws aligned with the occlusal surfaces facing each other, forming an occlusal plane. Man is an imperfect isognathic, or near equal jaws.

*Anisognathous.* Unequal jaw widths, in which the mandibular molar occlusal zone is narrower than the maxillary counterpart, such as in the feline, canine, bovine, equine, etc.

### 1.1.8 The Dog and Cat Dentition

Dogs and cats have diphyodont development, heterodont teeth types, brachydont crown types, secondont teeth (all premolars, feline mandibular molar and a portion of the canine mandibular first molar), bunodont (feline maxillary molar, canine molars, including a portion of the mandibular first molar), thecodont tooth anchorage and anisognathic jaws.



## 1.2 Development

Note that the following section will give a brief overview of the embryologic development of the mouth and associated structures. The same tissues in the adult animal will be discussed later in the chapter.

Development of the gastrointestinal tract begins early in embryonic formation. The roof of the endodermal yolk sac enfolds into a tubular tract forming the gut tube, which will become the digestive tract. It is initially a blind tract being closed at both the upper and bottom ends. The bottom ultimately becomes the anal opening and the upper portion connects with the primitive oral cavity known as the stomodeum, or ectodermal mouth. The stomodeum and foregut are at this time separated by a common wall known as the buccopharyngeal membrane. It is located at a level that will become the oropharynx, located between the tonsils and base of the tongue. This pharyngeal membrane eventually disappears, establishing a shared connection between the oral cavity and the digestive tract.

Around day 21 of development, branchial arches I and II are present. By day 23 the paired maxillary and mandibular processes of branchial arch I have become distinct. The mandibular processes grow rostrally, forming the mandible and merging at the mandibular symphysis, which in the dog and cat normally remains a fibrous union throughout life. The paired maxillary processes form most of the maxillae, incisive, and palatine bones.

Initial development of the dental structures occurs during embryonic formation. Rudimentary signs of tooth development occur approximately at the 25th day of development when the embryonic oral (stratified squamous) epithelium begins to thicken. This thickening, known as the dental lamina, forms two U-shaped structures,

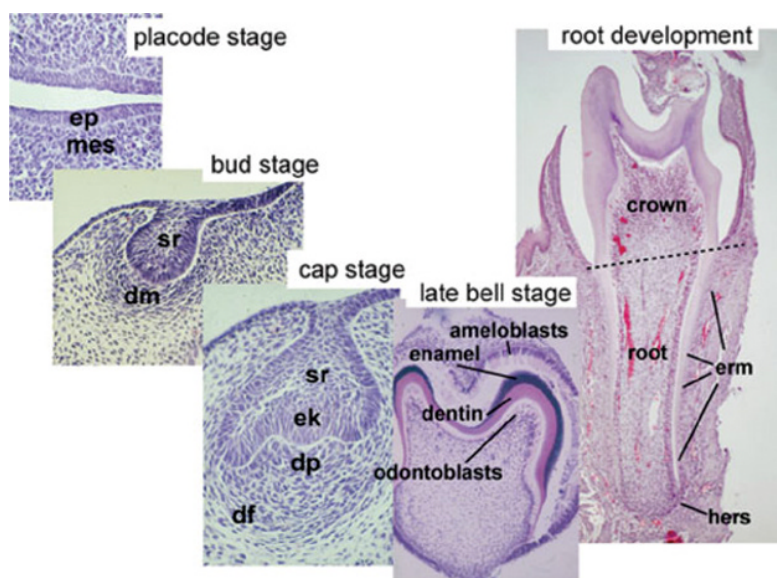
which eventually become the upper and lower dental arches. The enamel organ, which eventually is responsible for enamel formation and has a role in induction of tooth formation, arises from a series of invaginations of the dental lamina into the adjacent mesoderm. The oral epithelium, dental lamina, and enamel organ originate from the outer embryonic germ layer known as ectoderm. The dental papilla and sac appear in coordination with the enamel, but originate from mesoderm (ectomesenchyme of the neural crest).

The enamel organ develops through a series of stages known as the bud, cap, and bell (Figure 1.1). The bud stage is the initial budding off from the dental lamina at the areas corresponding to the deciduous dentition. The bud eventually develops a concavity at the deepest portion, noting the start of the cap stage. As the enamel organ enters this stage it is comprised of three parts: the outer enamel epithelium (OEE) on the outer portion of the cap, the inner enamel epithelium (IEE) lining the concavity, and the stellate reticulum within the cap. The onset of the bell stage occurs as a fourth layer to the enamel organ, the stratum intermedium, emerges between the IEE and the stellate reticulum.

Each layer of the enamel organ has specific functions to perform. The OEE acts as a protective layer for the entire organ. Stellate reticulum works as a cushion for protection of the IEE and allows vascular fluids to percolate between cells and reach the stratum intermedium. The stratum intermedium apparently converts the vascular fluids to usable nourishment for the IEE. The IEE goes through numerous changes, ultimately being responsible for actual enamel formation.

The dental lamina buds that form the primary dentition develop lingual extensions referred to as successional

**Figure 1.1** Histology of important stages of tooth development. Note that all early development is directed at creating the crown and only then root formation is initiated. Ameloblasts differentiate from the epithelium and odontoblasts from the mesenchyme and they deposit the matrices of enamel and dentin, respectively. Ameloblasts and enamel are missing on the root, which is covered by the softer dentin and cementum. Ep, epithelium; mes, mesenchyme; sr, stellate reticulum; dm, dental mesenchyme; dp, dental papilla; df, dental follicle; ek, enamel knot; erm, epithelial cell rests of malassez; hers, Hertwig's epithelial root sheath. Source: from Thesleff, I. and Tummars, M. Tooth organogenesis and regeneration: <http://stembook.org/node/551>; accessed November 2017.



lamina. The successional laminae progress through bud, cap, and bell stages to eventually form the successional permanent dentition. The non-successional teeth, those permanents not succeeding deciduous counterparts, develop directly from the dental lamina.

During the late bud stage, from an area adjacent to the IEE, mesenchymal cells begin development of the dental papilla and dental sac. The mesodermal cells of the dental papilla form the dentinal and pulpal tissues of the forming tooth. The dental sac is comprised of several rows of flattened mesodermal cells covering the dental papilla and attaching part of the way up the OEE of the bud. It gives rise to cementum, periodontal ligament (PDL), and some alveolar bone.

The frontal prominence, the forehead area of the embryo, occurs in coordination with the stomodeum and mandibular processes. Nasal pits, the beginning of the nasal cavities, are first revealed by two small depressions found low on the frontal prominence. On either side of the nasal pits are the medial and lateral nasal processes. The two medial nasal and two maxillary processes form the upper lip. The groove between the two fills with connective tissue in a process known as migration. If migration fails to occur the tissues will be stretched thin and will tear. This results in a separation between the medial nasal and maxillary process, which causes a cleft lip.

The left and right maxillary processes and the single medial nasal processes also form the palate. The incisal portion (maxilla) of the hard palate is the part from the maxillary incisor teeth back to the incisive foramen. The area of the incisive bone (the premaxilla in some species, and formerly in the dog) is also known as the primary palate and is formed solely by the medial nasal process. The medial nasal process forms the philtrum and helps form the nasal septum. The left and right maxillary processes form two palatal shelves that grow inward toward the midline, beginning rostrally, and then attaching to the primary palate and growing together. This is known as the secondary palate.

Cleft lips and palates are not uncommon. Clefts are generally designated as unilateral or bilateral. A unilateral cleft lip occurs when migration fails to occur between one of the maxillary processes and the medial nasal process. A bilateral cleft lip occurs when both maxillary processes fail to migrate. A unilateral cleft palate occurs when one of the palatal plates of the maxillary processes fails to fuse with the nasal septum. A bilateral cleft palate occurs when both palatal plates of the maxillary processes fail to fuse with the opposite plates at the nasal septum. Clefts of hard or soft palates develop in a wide range of varying degrees of severity.

### 1.2.1 Enamel, Dentin, and Pulp

These three structures have an intimate relationship during early development, although they do not all develop from the same foundation cells. Enamel is produced by the enamel organ, which is derived from ectoderm. In contrast, the dentin and pulp develop from the dental papilla, which is derived from mesoderm.

During the bell stage, the IEE cells evolve into a taller form and become preameloblasts. The peripheral cells of the dental papilla bordering the preameloblasts transform into low columnar or cuboidal shapes and form odontoblasts. As the newly formed odontoblasts move toward the center of the dental papilla and away from the preameloblasts they leave behind a secreted matrix of mucopolysaccharide ground substance and collagen fibers. This substance appears to stimulate a polarity shift in the preameloblasts of the nucleus from the center of the cell toward the stratum intermedium. It is thought that this shift in polarity is caused by an alteration in the nutritional supply route to the cells. With this shift in polarity, the cells now become ameloblasts and begin secretion of enamel matrix. As this enamel matrix (mucopolysaccharide ground substance and organic fiber) is laid down next to the dentinal matrix, the dentinoenamel junction (DEJ) is formed. As the ameloblasts lay down matrix they move away from the dentin and toward the OEE. Both the dentin and enamel begin to lay down crystal and mineralize at this point into hard tissue.

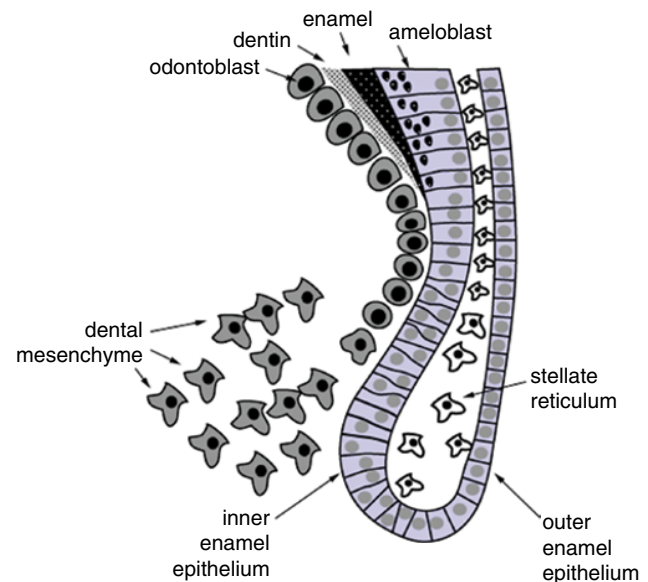
The enamel matrix is laid down at the end of the bell stage. All of the crystal placed within the rods are laid down at this time. This is known as the mineralization stage of calcification of the enamel rod. The next is the maturation stage of calcification. It is during this stage that the crystals grow in size, becoming tightly packed together within the enamel rod. Should the crystals fail to grow to full size, the rods will be poorly calcified and have less than 96% inorganic composition; this results in a condition known as hypomineralization. As enamel is produced by the ameloblasts, a change occurs in the enamel organ. The ameloblasts gradually begin to compress the two middle layers of the organ, the stratum intermedium and the stellate reticulum. The middle layers are eventually lost and the ameloblasts make contact with the OEE. This activates the final two functions of the ameloblasts to commence. First, a protective layer is laid down on top of the enamel known as the primary enamel cuticle or Nasmyth's membrane. This cuticle remains on the teeth for weeks to months, until it is worn away by abrasion. The cuticle is laid down upon the crown from the tip toward the cemento-enamel junction (CEJ). Once the cuticle is formed the ameloblasts merge with the OEE to form the reduced enamel epithelium.

The reduced enamel epithelium is produced on adhesive-like secretion known as the secondary enamel cuticle or epithelial attachment. The epithelial attachment functions to hold the gingiva and tooth together at the bottom of the gingival sulcus. During enamel development, several abnormalities may develop. These are sometimes found on clinical, radiological, or histological examination. Amelogenesis imperfecta is the general term that includes any genetic and/or developmental enamel formation and maturation abnormalities. Enamel hypoplasia refers to inadequate deposition of enamel matrix, i.e., when the density or mineralization is generally normal, but the enamel is thinner than normal. Enamel hypomineralization refers to inadequate mineralization of enamel matrix, resulting in white, yellow, or brown spots in the enamel. This often affects several or all teeth. The crowns of affected teeth may be soft and wear faster than normal teeth.

Mesodermal tissue from the dental papilla forms the pulp. Once developed, it consists of blood vessels, lymphatic vessels, nerves, fibroblasts, collagen fibers, undifferentiated reserve mesenchymal cells, other cells of connective tissue, and odontoblasts. Odontoblasts are an integral part of the dentin, but are also the peripheral cells of the pulp. The pulpal nerves are primarily sensory and transmit only the sensation of pain. There are some motor nerves that innervate the smooth muscles within the blood vessels. These result in constriction of the vessels in response to irritation. Young pulps have a large volume, which is considered primarily cellular, with a small concentration of fibers. The large number of cells allows for repair from trauma. As the pulp ages, it loses volume and reserve cell capacity. This loss of reserve cells is thought to be the reason that older patients are more susceptible to permanent pulpal damage.

### 1.2.2 Root Formation

Formation of the root begins after the general form of the crown has developed, but prior to its complete calcification. At the point where the OEE becomes the IEE, the stellate reticulum and stratum intermedium are missing from the enamel organ at this deepest point, and is referred to as the cervical loop. These two layers of cells become the epithelial root sheath or Hertwig's epithelial root sheath (Figure 1.2). This sheath begins to grow into the underlying connective tissue by rapid mitotic division, initiating root formation. This growth advanced deep into underlying connective tissue, but at some point, angles back toward the center of the forming tooth. The portion of the sheath that turns back in is known as the epithelial diaphragm. The growth pattern of the epithelial diaphragm determines the number of roots a tooth develops. The point at which



**Figure 1.2** Fate of the stem cell progeny in the epithelial stem cell niche of the continuously growing tooth, the cervical loop. Stem cells divide in the stellate reticulum compartment giving rise to cells that will become inserted to the basal layer of epithelium looping around the stellate reticulum. Here the cells proliferate, migrate toward the oral cavity and differentiate into ameloblasts, depositing enamel matrix. *Source:* From Thesleff, I. and Tummers, M. Tooth organogenesis and regeneration: <http://stembook.org/node/551> – animation; accessed November 2017.

the epithelial diaphragm meets will be the apex of a single rooted tooth but the furcation in multirooted teeth. As the root sheath makes contact with the dental papilla, it stimulates the peripheral contact cells to differentiate into odontoblasts. Once the odontoblasts begin to produce dentin, the root sheath trapped between the dental sac and the dentin begins to break up. As Hertwig's epithelial root sheath dissolves, the dental sac comes into direct contact with the newly formed dentin. Some of the dental sac cells differentiate into cementoblasts and initiate cementum formation. The cementum that contacts the dentin becomes the dentinocemental junction (DCJ).

The epithelial root sheath cells that move away from the dentin, but fail to dissolve, become entrapped in the PDL and are referred to as epithelial rests or epithelial rests of Malassez. These cell rests are a normal finding, but under the influence of various stimuli, they could proliferate later in life to form epithelial lining of various odontogenic cysts, such as the radicular cyst. When epithelial root sheath cells fail to dissolve and remain in contact with the dentin, they typically convert to ameloblasts. These may secrete enamel on the roots, forming what is known as enamel pearls. If the root sheath's epithelial diaphragm malfunctions, accessory roots may be formed.



### 1.2.3 Tooth Eruption

The emergence and movement of the crown of the tooth into the oral cavity is typically termed tooth eruption. The eruptive sequence is generally divided into three stages. The pre-eruptive stage commences with crown development and the formation of the dental lamina. With the onset of root development, the eruptive stage begins. This is also sometimes referred to as the pre-functional eruptive stage. When the teeth move into actual occlusion it is termed post-eruptive stage or functional eruptive stage. This stage is considered to continue until tooth loss occurs, or death. In the hypodont species, this stage may function to serve occlusion in several ways. As the jaws grow, the mandible and maxilla spatial relationship becomes further apart and the teeth continue to erupt to maintain occlusion. With time, attrition results in loss of dental occlusal contacts and it is this further eruption that maintains the occlusal balance. In some cases, this can cause an imbalance in occlusion when teeth are lost and supraeruption of the opposing teeth occurs. Supraeruption is when teeth erupt beyond the normal occlusal line.

Four major theories for eruption have been expounded upon in the literature. Most likely none are totally correct in themselves, but the most accurate picture is probably a combination of them. The theory of root growth is the belief that root growth pushes the crown into the oral cavity. Experiments of removing Hertwig's epithelial root sheath on developing teeth has stopped root formation. However, these rootless teeth still erupt, thus disproving this as a major factor in eruption. The theory of growth of pulpal tissue proposes that continued growth of the pulp tissue while the hard sides of the tooth are forming provides apical propulsion. Yet developing teeth in which the pulp dies or is removed will still erupt, also disproving this as a major factor in eruption. The theory of bone deposition in the alveolar crypt is the precept that bone deposition within the alveolar crypt forces the tooth to erupt. This deposition is not constant and even when the crypt undergoes resorption due to various factors teeth generally still erupt, making this theory a dubious major factor. The theory of PDL force is the hypothesis that it is the PDL's driving force that maintains occlusal contact also thrusts the tooth into the oral cavity. This is the most plausible postulate, although the exact mechanism is unknown. Eruption times are variable not only with size and breed but also within the breeds themselves. Average eruption times of deciduous and permanent teeth can be found in Table 4.1 in Chapter 4 – Developmental Pathology and Pedodontology.

Exfoliation of deciduous dentition is a complex function and not fully understood. It is believed that as the perma-

nent tooth root begins development, the crown makes contact with the deciduous tooth root structure. The pressure of the permanent tooth crown on the deciduous tooth root, and possibly the contact of the permanent tooth's dental sac or the OEE with the deciduous root, stimulates the resorptive process of the deciduous tooth root. Deciduous root resorption occurs in cycles or stages, and is not constant. Once sufficient root support is lost, the crown is shed or exfoliated. Although it is common for deciduous teeth to persist when a permanent successor does not develop, this is not always the case, indicating that other factors may play a part in root resorption.

Persistent deciduous teeth are commonly attributed to four causes. The first is the lack of a permanent successor. The second is ankylosis of the tooth to the alveolus. This may occur during root resorption when holes in Hertwig's root sheath develop and the tooth's cementum makes contact with the alveolar bone and fuses to it. In these cases, it is common to find teeth with almost the entire root structure dissolved, but with the crown still firmly in place. Once the ankylosis is relieved, typically the crown rapidly exfoliates. The third cause for persistent deciduous dentition is failure of the permanent crown to make contact with the deciduous root during eruption. This occurs if either tooth is in an improper position, in comparison to each other. Finally, the fourth reason is hormonal influences, which can affect growth or metabolism.

## 1.3 Basic Anatomy of the Dental-Periodontal Unit

### 1.3.1 Directional, Surface, and Ridge Nomenclature

Prior to discussing dental anatomy, a general understanding of directional, surface, and ridge nomenclature is required.

Rostral and caudal are anatomical terms of location applicable to the head in a sagittal plane in non-human vertebrates. Rostral refers to a structure closer to, or a direction toward, the most forward structure of the head. Caudal refers to a structure closer to, or a direction toward, the tail. Anterior and posterior are the synonymous terms used in human dentistry. The term caudal teeth refer to premolars and molars, as opposed to incisors and canines, which are rostral teeth. Incisors, canines, and premolars have four exposed surfaces and a ridge or cusp, making a total of five surfaces. Molars have five exposed surfaces. Sometimes a ridge may be referred to as a surface.

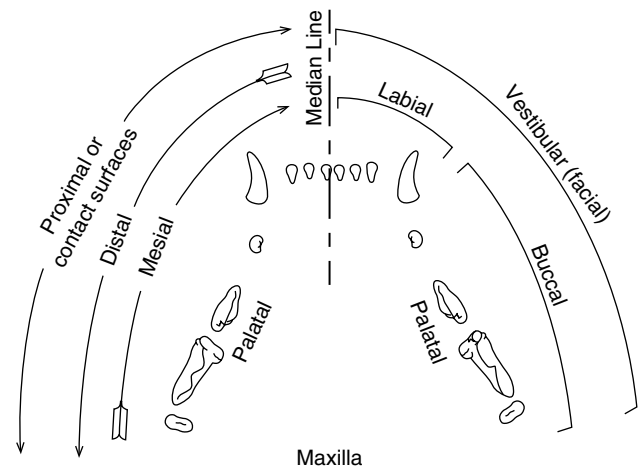
As a general rule, the surfaces of the teeth facing the vestibule or lips are the vestibular surfaces [1] (Figure 1.3). For the incisor and canine teeth, the surface directed toward the lips is commonly called the labial surface. With premolars and molars, the surface facing the cheek is known as the buccal surface. The term “facial” has been used traditionally in human dentistry to refer to the surfaces of the rostral teeth visible from the front. All surfaces facing the tongue are described as lingual, although for the maxillary teeth this surface is often described as the palatal surface. For premolars and molars, the surface making contact with the teeth in the opposite jaw during closure is known as the occlusal surface. The ridge of the premolars that does not make contact with opposing teeth is typically referred to as the occlusal ridge. For the incisors, the ridge along the coronal-most aspect is referred to as the incisal ridge. The cusp is the point or tip of the crown of a tooth. For the canine tooth, the cusp is generally called the cusp surface. Premolars and molars may have multiple cusps. Surfaces facing toward adjoining teeth within the same jaw quadrant or dental arch are collectively called the contact or proximal surfaces. Proximal surfaces may be either distal or mesial. The term distal indicates a proximal surface facing away from the median line of the face. In contrast, the term mesial designates the proximal surface facing toward the median line. The space between two facing proximal surfaces is known as the interproximal space. Apical is a term used to denote a direction toward the root tip. Coronal is a term used to indicate a direction toward the crown tip or occlusal surface. The terms incisal for incisors and occlusal for premolars and molars is also used to indicate the coronal direction. The term cervical either means the juncture of the tooth crown and root or a direction toward that point.

To further break down tooth locations, combinations of the above terms are sometimes used, with one additional term, middle (Figure 1.4). The term middle means at or toward the middle of a designated portion of the tooth and can indicate either a horizontal or vertical middle area.

### 1.3.2 Crown Line and Point Angles

For the purpose of identifying and classifying distinct areas on teeth in operative dental procedures, the coronal surfaces can be divided and classified by eight line angles and four point angles (see Chapter 17 – Restorative Dentistry). These lines and points are also sometimes used for identification of cavity prep areas.

There are five crown surfaces: vestibular, lingual/palatal, mesial, distal, and occlusal/coronal/incisal. The line angles are simply the dividing lines formed between



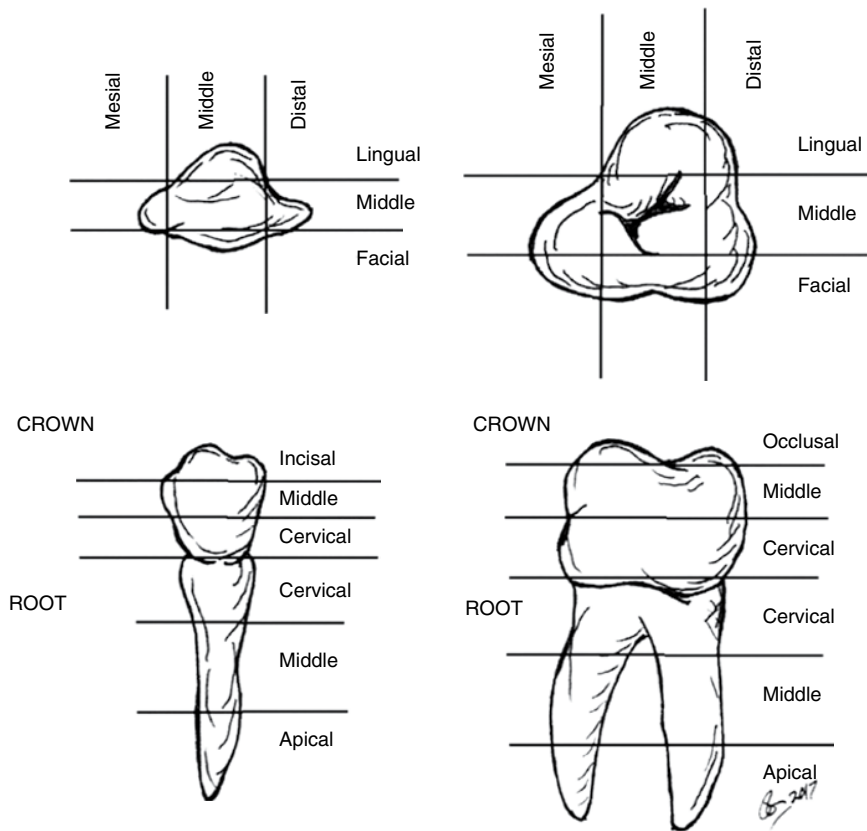
**Figure 1.3** Directional nomenclature of the maxillary teeth of the cat. Source: Courtesy of Josephine Banyard.

the surface areas. They are named from two of the five surfaces that divide them. Where the surface terms are joined, the “ar” or “al” ending is dropped and “o” is added. The eight line angles are (i) mesiovestibular (mesiolabial, mesiobuccal), (ii) mesiolingual (mesiopalatal), (iii) mesioincisal (mesiocoronal, mesio-occlusal), (iv) distovestibular (distolabial, distobuccal), (v) distolingual (distopalatal), (vi) distoincisal (distocoronal, disto-occlusal), (vii) linguoincisal (linguocoronal, linguo-occlusal), and (viii) vestibuloincisal (vestibulocoronal, vestibulo-occlusal).

The point angles are the junctures of three of the line angles. There are four coronal point angles, each named for the three surfaces that actually make the juncture or point. The four point angles are (i) mesiovestibuloincisal (mesiovestibulocoronal, mesiovestibulo-occlusal, mesiolabioincisal, mesiolabio-occlusal, mesiobuccocoronal, mesiobucco-occlusal), (ii) mesiolinguoincisal (mesiolinguocoronal, mesiolinguo-occlusal, mesiopalatoincisal, mesiopalato-occlusal), (iii) distovestibuloincisal (distovestibulocoronal, distovestibulo-occlusal, distolabioincisal, distolabio-occlusal, distobuccocoronal, distobucco-occlusal), and (iv) distolinguoincisal (distolinguocoronal, distolinguo-occlusal, distopalatoincisal, distopalato-occlusal).

### 1.3.3 Contact Points and Areas

Contact points and areas are the sites where adjacent or opposing teeth make contact. The term contact area is considered a more correct term than contact point, since an area is typically making contact rather than a specific point. Adjacent teeth have proximal contact areas, where opposing teeth have occlusal contact areas.



**Figure 1.4** Division into thirds. Source: Courtesy of Josephine Banyard.

### 1.3.4 Embrasures

Projecting away from the proximal contact areas are V-shaped areas termed embrasures. They are named for the surface from which they are derived and the direction they radiate toward. There are theoretically four embrasures between each tooth with proximal contacts. The embrasures are the (i) vestibulolingival (labioingival, buccolingival), (ii) vestibuloincisal (vestibulocoronal, vestibulo-occlusal, labioincisal, labiocoronal, labio-occlusal, buccocoronal, bucco-occlusal), (iii) linguolingival (palatolingival), and (iv) linguoincisal (palatoincisal, palatocoronal, palato-occlusal, linguocoronal, linguo-occlusal).

### 1.3.5 Tooth Function and Terms

Teeth are multifunctional organs that play an important part in overall animal health and activity. Their shape aids physiologically in protection of the oral mucosa, as well as reduction of stress forces on the teeth and the alveolar process. Teeth are used to catch, hold, carry, cut, shear, crush, and grind sustenance. Besides their masticatory functions, they are used in protection, aggression, and sexual attraction. Sexual dimorphism, such as length of tooth, may play a part in sexual attraction and social behavior for defense.

Each tooth has a crown and a root, except for aradicular hypsodonts (see Chapter 21 – Small Mammal Oral and Dental Diseases). Generally, the brachydont crown is covered with enamel and the root with cementum. Where the enamel of the crown and cementum of root meet is known as the CEJ. The line formed by the CEJ is commonly called the neck, cervix, or cervical line. In many cases, especially during eruption and in hypsodont dentition, not all of the crown may be fully exposed. The entire crown, whether exposed or not, is the anatomical crown. The supragingival portion of the crown is the clinical crown and the subgingival portion is the reserved crown. The reserved crown is occasionally referred to as the clinical root as compared to the anatomical or true root. The incisor teeth are designed to cut, scrape, scoop, pick at or up, and groom. The term incisor means “that which cuts.” The actual biting edge of the incisor is the incisal edge or ridge. The incisal edge picks up and cuts food, scrapes meat off bone, grooms the hair, and is used to catch parasites. The concave lingual surface acts as a scoop and, along with the tongue, aids in carrying food into the oral cavity. The canine teeth are designed to pierce and hold a victim. They can also be used to slash and tear when used as weapons in fighting. In the carnivores, canines have the longest crowns and roots. These large roots make them very stable and good anchorage points. Premolars resemble a cross

between canine teeth and molars. They are not as long as canine teeth and generally have multiple functional cusps. Being a cross between a canine tooth and a molar, they are designed to function similarly to both. They help to hold and carry, while also helping to break food down into smaller pieces. Molars have an occlusal surface that can be used to grind food or break it down into smaller pieces. The incisors and canine teeth are referred to as rostral teeth, while the premolars and molars are caudal teeth. The carnassial teeth are considered to be the largest shearing teeth in the upper and lower jaws. In the dog and cat these are the maxillary fourth premolars and the mandibular first molars. The term carnassial (commonly used, not an accepted anatomic term) means flesh cutting.

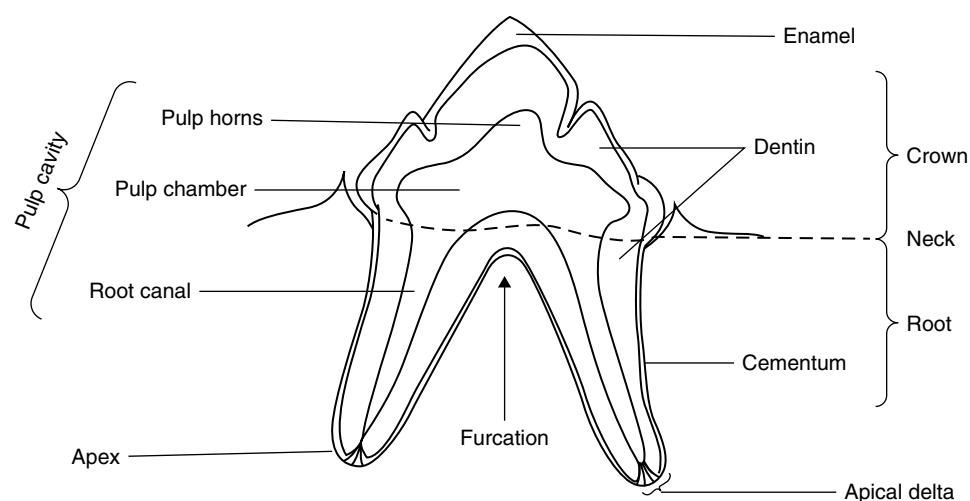
Crown formation generally occurs from four or more growth centers known as lobes. Their fusion, termed coalescence, can result in various depth grooves known as developmental grooves. Most incisors, canine teeth, and premolars develop from four lobes, three vestibular and one lingual. The two developmental grooves on the vestibular surface of the incisors are the coalescence or fusion points of the three vestibular lobes. The three protrusions along the incisal edge formed by the developmental grooves are the mamelons. The deep developmental grooves in many carnivores and some primates appear to help in cutting the flesh as it slides up the tooth and act as bleeding grooves, allowing for blood to escape from the punctures in the victim while still holding them in a firm grasp. The fourth lobe on the lingual surface typically forms the majority of the tooth bulk at the lingual cervical third and is called the cingulum. Just coronal to the incisor cingulum is a slight concavity known as the lingual fossa.

The proximal contacts are the points at which adjacent teeth make contact. These contacts aid in prevention of food being packed between the teeth from above, while the gingival papilla serve the same purpose from the vestibular and lingual surfaces. The contacts of the rostral teeth are located close to the incisal ridge, whereas they are located more apically in the caudal teeth. With the tooth spacings found in the dog and cat, proximal surfaces do not always make contact with the adjacent teeth. The bulge, curvature, or contour of the tooth aids in directing food away from the gingival sulcus, while using frictional movement of the food to clean the gingivae, cheeks, and lips.

## 1.4 General Anatomy of the Tooth and Periodontium

It is arbitrary to discuss the tooth and periodontium as separate parts as it is one functional unit. However, to more easily understand the anatomy and physiology, it will be separated into the crown, dentin and pulp, root, and periodontium.

The tooth is made up of basically four tissues, three hard and one soft. The hard tissues are enamel, cementum, and dentin; the soft is the pulp. The pulp tissue occupies the cavern within the tooth known as the pulp cavity. This cavity is further divided into pulp chamber, portion in the crown, and root canal, portion within the root. The bottom of the pulp chamber is referred to as the chamber floor and the most coronal part the chamber horns in which the pulp horns reside (Figure 1.5).



**Figure 1.5** Tooth anatomy. *Source:* Courtesy of Josephine Banyard.



### 1.4.1 Dental Formulas

The currently accepted designations of the dental formula for the dog is as follows:

Deciduous teeth:  $2 \times (3/3 \text{ i}, 1/1 \text{ c}, 3/3 \text{ pm}) = 28$ .

Permanent teeth:  $2 \times (3/3 \text{ I}, 1/1 \text{ C}, 4/4 \text{ PM}, 2/3 \text{ M}) = 42$ .

The currently accepted designations of the dental formula for the cat is as follows:

Deciduous teeth:  $2 \times (3/3 \text{ i}, 1/1 \text{ c}, 3/2 \text{ pm}) = 26$ .

Permanent teeth:  $2 \times (3/3 \text{ I}, 1/1 \text{ C}, 3/2 \text{ PM}, 1/1 \text{ M}) = 30$ .

(Additional dental formula information for the dog and cat can be found in Chapter 2 – Oral Examination and Diagnosis – and for other species in their related chapters.)

### 1.4.2 Crown

The crown is the portion of the tooth typically erupted through the gingiva. The brachydont crown is completely covered by enamel. Enamel is the hardest substance in the body and contains the highest percentage of mineral. It has a semi-translucent white color, although it may appear as other colors due to the refraction of the underlying dentin (e.g., intrinsic discoloration). Extrinsic staining and color changes of the enamel can occur with age. Enamel is approximately 96% inorganic in composition. This inorganic portion is calcium phosphate in the form of hydroxyapatite crystals. Fluoride, magnesium, strontium, and lead may also be present [1]. The remaining 4% of enamel composition is principally water and fibrous organic material. Enamel varies in thickness over the surface of the tooth, often thickest at the cusp and thinnest at its border with the cementum at the CEJ [1]. Despite its hardness, enamel is subject to wear attrition from friction of use. Fluorinated enamel has an improved resistance to degradation by acids generated from bacterial activity. Enamel is avascular and has no capability to regenerate itself when damaged; however, it is not a static tissue as it can undergo mineralization changes.

The basic building block of enamel is the enamel rod. Each rod is a column of enamel that extends from the DEJ to the coronal surface of the tooth. These rods are generally perpendicular both to the DEJ and the surface. Each rod is composed of two parts, the rod core and the rod sheath. The rod core is composed of hydroxyapatite crystals. The rod sheath, which surrounds the columnar side of the rod core, is composed mostly of the organic fibrous substance. Crystals are present between rod sheaths called interrod enamel. These crystals are not aligned in the same direction of rod enamel. The rod sheath is incomplete in circumference, allowing contact between the rod and interrod enamel. The shape of the

rods in the enamel is round to quad-lobed at the inner layer and hexagonal at the outer layer of enamel. Enamel rods have a round shape in the cat [2].

Three layers of enamel have been described in the cat and dog: a non-prismatic layer at the surface, a regular prismatic layer, and an inner layer with prominent bands of Hunter and Schreger, which may indicate multidirectional orientation of the rods [2]. Bands of Hunter and Schreger are not a true structure but an optical illusion produced by changes in direction between groups of rods [1]. The striae or stripes of Retzius are darker lines in the enamel that radiate out in a curve from the DEJ. These are areas of slight variation in the crystal content of the rods. It appears that approximately every fourth day in the ameloblast cycle, there is a change in the rod development or cycle of rest that results in these lines or striae. As these striae of Retzius are visible on the exposed surface enamel, they cause slight horizontal lines or ripples in the enamel. These are known as imbrication or perikymata lines. These perikymata are not present on the surface of dog or cat teeth, likely due to the angle of the striae of Retzius being nearly parallel to the tooth surface [2].

Enamel tufts are small, branched hypomineralized ribbon-like defects that run longitudinally to the tooth axis and extend from the DEJ one-fifth to one-third the way into enamel toward the enamel surface [3]. They are commonly found on histologic sectioning, especially in bunodont dentition of animals that crush hard materials such as nuts or mollusk shells. Although they have been noted to be a potential source of enamel fractures that arise after extended use or overloading, it appears that they then enable enamel to resist the further progression of these fractures, ultimately preventing mechanical failure [4]. This fracture resistance is one reason why tooth enamel is three times stronger than its constituent hydroxyapatite crystallites that make up its enamel rods [5]. Enamel tufts are frequently confused with enamel lamellae, which are also enamel defects, but which differ in two ways: lamella are linear, and not branched, and they exist primarily extending from the enamel surface, through the enamel and toward the DEJ, whereas enamel tufts project in the opposite direction. The most common form is that caused by trauma resulting in hairline cracks in the enamel. Lamellae can be of clinical significance depending on number and severity [6].

Enamel tufts should also not be confused with the similar enamel spindles. Enamel spindles are also linear defects, similar to tufts and lamellae. They are formed by entrapment of odontoblast processes between ameloblasts prior to and during amelogenesis. Like enamel tufts, spindles are found only at the DEJ; they are typically found histologically and have no known clinical significance.



There is evidence that the enamel of dogs and cats is much thinner than that found in man. In humans, the thickness is reported to be 2–4mm compared to 0.1–0.3mm in cats and 0.1–0.6mm in dogs [7]. Additionally, the cervical bulge often found at the level of the free gingiva does not represent a thickening in the enamel, but a general thickening in the tooth [7].

### 1.4.3 Root and Periodontium

The tooth root is covered by cementum and anchored to the jaws by the periodontium. The periodontium consists of the cementum, the PDL, the dental alveolus, and the gingiva. The periodontium exists to anchor the tooth, cleanse and protect the tooth, and to serve as sensory tissue.

The root surface is covered by cementum and is located apical to the attached gingiva in health. Teeth may have single or multiple roots. The point at which roots diverge is the furcation; this can be bifurcation, trifurcation, etc. Although there is individual variation, the number of roots is determined by species and type of tooth. In this chapter the dentition of the dog and cat will be the focus.

The incisors and canine teeth of the dog are all single-rooted teeth. The maxillary first and second and all three of the incisors in each mandible have relatively straight roots, which are round to triangular when examined in cross-section. The root of the maxillary third incisor is often triangular to trapezoidal in shape and has a curvature with the greater curvature being mesial to mesiobuccal and the lesser curvature being distal to distobuccal. This curvature may make closed extraction challenging. The root of the maxillary canine tooth is digitally palpable via the jugum. The apices of mandibular canine teeth are positioned lingual to the crowns. This functionally creates more buccal bone at the apical portion of the root and should be kept in mind during exodontia and related surgical procedures. The first premolar of each quadrant has a single root. The second and third premolars have two roots, typically with one root mesial to the other. In brachycephalic dogs the premolars may be rotated 90° such that one root is palatal to the other. Although not typical, a third root of the maxillary third premolar may be found; it is located palatally between the mesial and distal roots. In this case, a palatal cusp of the maxillary third premolar is often present. The maxillary fourth premolar has three roots, two mesial (mesiobuccal and mesiopalatal) and one distal. The maxillary first and second molars have three roots, two buccal (mesiobuccal and distobuccal) and one palatal. The second, third, and fourth premolars of the mandible are two-rooted (one mesial, one distal). The first and second molars are two-rooted (one mesial, one distal). The third molar

has a single root. A longitudinal groove may be present on the mesial and distal roots of the mandibular first molar and on the mesial surface of the distal root of the maxillary fourth premolar. These radicular grooves correspond with alveolar ridges in the alveoli and provide extra retentive surfaces and prevent rotation. The grooves may be appreciated radiographically giving the appearance of two PDLs and should be kept in mind during exodontic procedures [8]. Radicular grooves of the mandibular first molar may continue into the furcation, leading to a domed shape of the furcation. This shape should be kept in mind when performing periodontal therapy of this tooth [9]. Similarly, the maxillary fourth premolar has a domed shape at the furcation of the distal root and mesial root trunk as well as a fluted area just coronal to the furcation of the mesial roots [10].

The incisors and canine teeth of the cat are also all single-rooted. The maxillary first premolar is absent. The maxillary second premolar may have a single root, two individual roots, or two fused roots [11]. The maxillary third premolar has two roots and the maxillary fourth premolar has three roots, similar to the dog. The single maxillary molar may have a single root, two individual roots, or two fused roots [11]. The mandibular first and second premolars are absent. The mandibular third and fourth premolars and single mandibular molar each have two roots. The mesial root of the mandibular molar is approximately three times as wide (mesial to distal) as the distal root.

Cementum is an off-white or ivory colored hard substance that covers the root surface. Its composition is approximately 45–50% inorganic and 50–55% organic materials and water. The inorganic portion is primarily hydroxyapatite crystals and the organic part primarily collagen fibers and mucopolysaccharide ground substance.

Cementum formation begins at the neck or cervical circumference of the tooth, forming the CEJ. This junction is generally one of three types formed. These are cementum slightly overlapping the enamel, cementum meeting enamel evenly, or cementum failing to meet the enamel. In this third category, a cervical exposure of dentin occurs, which can result in tooth sensitivity should gingival recession occur.

Cementoblasts secrete cementum as they move away from the DCJ. In the cervical half to two-thirds of the root, the cementoblasts remain on the surface as the cementum is deposited and few if any of these cells become entrapped in the cementum, which is referred to as the acellular cementum. In the apical third, cementoblasts commonly surround themselves with cementum and become trapped. These trapped cells are referred to as cementocytes, and this portion of the cementum is identified as cellular cementum.

The cementoblast on the surface of the cementum deposits cementum around the ends of the PDL, making contact with them, and attaching them to the tooth. These fibers trapped within the cementum are known as Sharpey's fibers. The ends of the fibers entrapped in the alveolar bone are also known as Sharpey's fibers.

The cellular cementum of the root apex typically increases in thickness with time due to occlusal stresses of the tooth. This thickening is known as hypercementosis and is especially common in cats. Should this become excessive, a bulbous apex may form that can increase the difficulty of dental extraction.

Cementum is vital and has the ability to repair itself when injured. The cementoblasts on the surface and the embedded cementocytes receive nourishment from blood vessels of the PDL.

The bone of the jaws that form the socket support for the teeth is known as the alveolar bone. In the mature animal, the bone is approximately 65% inorganic and 35% inorganic in composition, and is mesodermal in origin. The alveolus is composed of three distinct layers. The compact bone on the inside of the socket next to the tooth is known as the cribriform plate and radiographically is termed the lamina dura. It has no periosteal covering, but is covered instead by the PDL. The fibers of the PDL embedded in the cribriform plate are called Sharpey's fibers (as are the Sharpey's fibers that are embedded within cementum). The compact bone rises to the top of the socket and then turns back to form the cortical plates. The top of the compact bone where the cortical and cribriform plates meet is known as the alveolar margin. The cortical plates are covered with periosteum. Between the two plates is spongy, cancellous, or trabecular bone. This is a form of bone marrow. The cribriform plate is constantly undergoing remodeling due to occlusal stresses. This may lead to additional bone being laid down on the plate, referred to as bundle bone.

The PDL is derived from the mesodermal cells of the dental sac. This formation begins after cementum deposition has been initiated. The dental sac on contact with the cementum forms fibroblasts, which produce collagen fibers at the same time other components of the PDL are developing. These are blood vessels, lymphatics, nerves, and various types of connective tissue cells. The nerves of the PDL are quite important in that they provide additional senses to the tooth. It has pain fibers, which the pulp has, but also pressure, heat, and cold fibers, which the pulp does not.

As the fibers of the PDL form, they begin to arrange themselves into three distinct categories, gingival, transseptal, and alveolodental. There are three types of gingival fibers, the dentogingival, alveologingival, and the circular gingival. Dentogingival fibers run from the cementum to either attached or free gingiva, providing a firm support

for these tissues. Alveologingival fibers run from the alveolar bone to either attached or free gingiva, providing further support for these tissues. The circular gingival fibers are found in the free gingiva running in a circular pattern around the tooth, providing additional support to hold it firmly against the tooth. Transseptal fibers extend from the cementum of one tooth, across the interproximal area to the cementum of an adjacent tooth. Alveolodental fibers run from the alveolar bone to the cementum and are typically divided into five types: alveolar crest, horizontal, oblique, apical, and interradicular. Alveolar crest fibers run from the crest in an apical-oblique direction to the cementum. These aid in resistance to extrusion and horizontal movement of the tooth. The horizontal fibers also run from the cementum to the alveolar crest, but horizontally, to resist horizontal tooth movements. Oblique fibers extend from the cementum in a coronal-oblique pattern to the alveolar bone and resist occlusal stresses. Apical fibers run from the apex to the alveolar bone and resist extrusional forces. The interradicular fibers are found only in multi-rooted teeth and go from the interradicular crestal bone to cementum, counteracting various types of movement according to their direction of attachment.

The gingiva is discussed in Section 1.5.1 on oral mucus membrane found below.

#### 1.4.4 Dentin and Pulp

Dentin and pulp should be thought as a single unit as the pulp produces the dentin throughout the life of the tooth and the dentin contains cellular units of the pulp.

Dentin is the hard yellow substance covered by the enamel and cementum. It is approximately 70% inorganic hydroxyapatite crystal (mucopolysaccharide ground substance) and about 30% organic (collagen fibers and water). Dentin grossly appears to be a solid structure, but is perforated by a multitude of openings. In microscopic cross-section, dentin has three distinct areas. The first is the dentinal tubule, which is a tube extending from the DEJ to the pulp. The odontoblastic process or Tomes' fiber is a cellular extension of the odontoblast within the dentinal tubule. The tubule is surrounded by the peritubular dentin. Intertubular dentin comprises the bulk of the dentinal substance and is located between dentinal tubules. The peritubular dentin is more highly mineralized than the intertubular dentin. In the dog the tubule is more ovoid at the periphery and circular toward the pulp. The tubule width has been measured to be 2.2 to 2.5  $\mu\text{m}$  in diameter in the dog and 1–2  $\mu\text{m}$  in the cat [12]. There are approximately 29 000 to 52 000 dentinal tubules per square millimeter of dentin cut in the maxillary canine of the dog [13]. The number increases with patient size and as the cut approaches the pulp.

Primary and secondary dentin are the two normal types of dentin. Primary dentin forms adjacent to the enamel prior to eruption of the tooth and secondary dentin forms after eruption. Primary dentin includes mantle dentin and the granular layer of Tomes. Mantle dentin is found adjacent to enamel and its organization differs from the rest of primary dentin [14]. The granular layer of Tomes is the area of primary dentin adjacent to cementum [14]. This layer is hypomineralized relative to dentin with a higher organic content and it has been hypothesized that the higher organic content may act to dissipate force transmitted through the PDL [15].

Secondary dentin is laid down in layers within the pulp cavity throughout life as long as the pulp is vital, resulting in the pulp cavity gradually decreasing in diameter with age via a process called pulp recession.

Tertiary dentin is formed in response to traumatic stimulation. This type of dentin differs histologically from the normal dentin in that it generally has few if any dentinal tubules present and appears to be very dense and unorganized. It forms immediately below the cause of the irritation and can result in alteration of normal pulp cavity anatomy. The amount of tertiary dentin formation is related to the amount of secondary dentin remaining after injury and the rate of formation appears to be dependent on the type of trauma [16]. Tertiary dentin may be subdivided into reactionary and reparative. Reparative dentin occurs when reserve mesenchymal cells differentiate into new odontoblasts which repair dentin in areas of trauma. Reactionary dentin occurs when existing odontoblasts are involved in the formation of tertiary dentin [1]. As tertiary dentin forms, odontoblasts may become trapped in the dentin, producing osteodentin [1]. Dead tract dentin occurs in an area of dentin in which the dentinal tubules are empty. This typically occurs due to some form of trauma that kills the odontoblasts, leaving the dentinal tubule empty. These open tubules are pathways for bacteria and other substances to make rapid access to the pulp. If the pulp remains viable, reparative dentin may close off the dead tract dentin [1].

Sclerotic dentin is dentin in which the tubule is mineralized. This process increases with age and trauma. This type of dentin increases the transparency of the dentin.

Interglobular dentin is areas of hypocalcified dentin found next to the mantle dentin. It is hypocalcified dentin that occurred during formation. Increased amounts of interglobular dentin occurs in cases of rickets and dental fluorosis [1]. Although Tomes' granular layer and interlobular dentin are both hypomineralized layers adjacent to the outer covering of the tooth, the layers differ more than by location only. The two layers also differ in individual mineral and proteoglycan content [17].

The pulp of the root is contained within the root canal. It consists of blood vessels, nerves, fibroblasts, collagen fibers, undifferentiated reserve mesenchymal cells, other cells of connective tissue, and odontoblasts. The pulp is divided into four zones: odontoblastic, cell-free or zone of Weil, cell-rich, and the pulp core. Odontoblasts are an integral part of the dentin, but are also the peripheral cells of the pulp, which is why pulp and dentin are often thought of as a complex versus individual tissues. As mentioned before, the odontoblastic process is an extension of the odontoblast found within the dentinal tubule. There has been speculation that the process may not typically reach the DEJ [18], but the current accepted theory is that, since components of the process are found through the whole tubule, the process must run the length of the tubule [1]. Odontoblasts do not undergo cell division and must be replaced by undifferentiated ectomesenchymal cells found within the cell-rich zone [1]. The potential for differentiation into new odontoblasts decreases with age and the veterinary dentist should consider this when deciding if vital pulp therapy and direct pulp capping are appropriate for a patient. The nerves are primarily sensory and transmit only the sensation of pain. There are some motor nerves that innervate the smooth muscles within the blood vessels. These result in constriction of the vessels in response to irritation.

The presence of lymphatics within the dental pulp of man and dog is controversial. While most historic studies in man demonstrate the presence of lymphatics, many studies in dogs do not. Recent studies using immunohistochemistry methods did not demonstrate the presence of classic lymphatics in man or the dog [19, 20].

When examined in medium sized dogs, the root canal topography roughly mirrors the external topography of the tooth. The exception is a mesiopalatal root of the maxillary fourth premolar that is compressed buccal to palatal [21]. The endodontist should consider this anatomy as the root canal may appear cylindrical when radiographs are studied, but may be oval, elliptical, or ribbon shaped.

The termination or apical end of the root is the apex. The apex can have a single opening, apical foramen, or multiple openings, the apical delta, through which vessels, nerves, and other structures may pass into the tooth to merge with the pulp. Canine and feline root anatomy is generally in the form of an apical delta. Each opening of the delta is known as an apical ramification. In one study the number of apical ramifications in the dog was found to be 5–20 with a decrease in the number of ramifications with increased age of the patient [22]. When a single apical foramen is present, cementum enters into the foramen. In the case of an apical delta, cementum does not enter into the apical ramifications [22]. The root canal terminus is several millimeters from the

surface of the root in the dog and cat and can be up to 6mm in the cat [23]. This distance increases with age [23].

Non-apical ramifications or accessory canals occur where there is a break in Hertwig's epithelial root sheath during development. This prevents formation of dental hard tissue in a focal area and allows the pulp to communicate with the periodontium. These canals are typically found in the apical 1/3 of the root. Studies of incisors, canines, and maxillary fourth premolars of dogs showed an incidence of lateral canals to only be 2.4%. Of the four teeth that had lateral canals, one was a canine tooth and the other three were maxillary fourth premolar teeth [24]. When examining the maxillary fourth premolar and mandibular first molar, accessory canals were present in 68% of maxillary fourth premolars and 28.4% of mandibular first molars [25]. It has been demonstrated that the canine tooth of the cat has an average of 12.5 apical ramifications [23]. The endodontist should consider the likelihood of accessory canals when performing standard and surgical root canal therapy.

## 1.5 Mouth

The mouth (*os*) is the entrance or the oral cavity. It is solely the opening between the lips, designating the beginning of the digestive tract. The most rostral extent of the oral cavity is secured by the lips (*labia oris*). The upper lip (*labium superius*) and lower lip (*labium inferius*) converge at the angles of the mouth (*angulus oris*), forming the commissures of the lip.

### 1.5.1 Oral Mucous Membrane

The stratified squamous epithelium that runs from the margins of the lips to the area of the tonsils and lines the oral cavity is known as the oral mucosa or oral mucous membrane. These oral mucous membranes are divided into three categories. The first is the specialized mucosa, which is found on the dorsum of the tongue. Second is the masticatory mucosa, which undergoes routine masticatory trauma and stress and is generally parakeratinized or keratinized. This is the tissue of the hard palate and gingivae. The third is the general or lining mucosa, which comprises the remaining oral mucosa. It is non-keratinized to parakeratinized with an underlying connective tissue containing fairly well-developed collagen fibers that provide support, but still allow substantial movement of the overlying epithelium.

An interdigitation exists between the epithelium and the underlying connective tissue. The interdigitation of the submucosal connective tissue into the epithelium is termed the dermal papilla. The pegs of epithelium that insert into the connective tissue are known as rete ridges

or pegs and cause small dimples in the gingival tissue known as gingival stippling. Stippling can be present or absent in healthy or diseased gingival tissue and therefore is not a reliable indication of gingival health [26–29]. The length of the pegs determines how tight or mobile the epithelium is attached to the underlying connective tissue. The lining mucosa has poorly developed pegs and is therefore fairly movable above the connective tissue. In comparison, the masticatory mucosa has well-developed rete pegs and consequently a tighter attachment.

The gingival masticatory mucosa is one of the most important support structures for the tooth. It is divided into two major parts, the attached gingiva and the free gingiva (marginal gingiva). The attached gingiva is attached to the alveolar bone via periosteum making it relatively immobile. It also has direct attachment to the cementum coronal to the alveolar bone. The width of the attached gingiva is important in planning periodontal treatment. It is widest on the maxilla at the canine teeth and generally thinner at the distal aspect of the fourth premolar and molars. On the mandible it is widest at the region of the first molar. The width of the attached gingiva is measured from the most apical aspect of the sulcus or periodontal pocket to the mucogingival junction.

The free gingiva projects in a coronal direction from the attached gingiva and is not attached to the tooth or alveolar bone. The free gingiva reflects toward the tooth to form shallow groove known as the gingival sulcus. The apical attachment of the sulcus is the epithelial attachment or the junctional epithelium, which directly attaches the gingiva to the tooth. In periodontal disease it is common for the sulcus depth to increase as attachment is lost. A peak of gingiva is found between proximal teeth known as the interdental papilla. The interdental papilla plays an important part in maintenance of gingival health by preventing food and debris from being impacted between the teeth. Between the vestibular and lingual aspects of the interdental papilla may be a peak or a valley of gingiva known as the col. The epithelium lining the sulcus, the col and the junctional epithelium are the very few areas of masticatory mucosa that are typically non-keratinized.

The mucogingival junction is the demarcation between the attached gingiva and alveolar mucosa, which is part of the general or lining mucosa. The mucogingival junction is also referred to as the mucogingival line or margin; it is most distinct on vestibular surfaces and less apparent on lingual and palatal surfaces.

### 1.5.2 Oral Cavity

The oral cavity (*cavum oris*) is typically considered to be the area extending from the lips to the oral pharynx at the level of the palatine tonsil. Rostrally it is bound by the lips, laterally by the cheeks (*buccae*), dorsally by the hard



and soft palates, and ventrally by the floor of the mouth. The oral pharynx is also the location where the digestive and respiratory tracts share a common, intersecting pathway.

The oral cavity is generally subdivided into two parts, the vestibule (*vestibulum oris*) and the oral cavity proper (*cavum oris proprium*). The vestibule is the theoretical space between the lips or cheeks and the teeth, gums, and alveolar ridges. The oral cavity proper extends from the alveolar ridge and teeth to the oral pharynx. It is additionally defined by the roof and floor of the mouth and is generally filled by the tongue.

#### 1.5.2.1 Vestibule

The lips are comprised of three components, one of which is the facial stratified squamous epithelium portion. The vestibular component is covered with oral mucosa that is non-keratinized to parakeratinized squamous epithelium. The juncture where the lips meet the surrounding skin is the vermilion border [30], and the pigmented area within the borders is called the vermilion zone (named after the typical red color in human lips). The transitional zone between facial and vestibular components is the vermilion zone of the lip. The facial or skin part of the upper lip at the midline has an indentation known as the philtrum. Cleft lips are most commonly seen to occur at the lateral board of the philtrum. The point at which the oral mucosa and the top or bottom of the vestibule turn toward the alveolar ridge is known as the mucobuccal or mucolabial fold. The attachment of the mucosa to the alveolar bone is loose and movable, and the point where it becomes tightly attached is the mucogingival junction.

Within the vestibule is also contained the frenula, which are areas where folds of alveolar mucosa form a noticeable ridge of attachment between the lips and the gum. The dog has three primary frenula: one upper and two lower. The upper extends from the midline of the lip to the gingiva immediately below the two central incisors. The lower two extend from the lip to the level of the mandibular canine teeth.

#### 1.5.3 Oral Cavity Proper

Within the oral cavity proper is contained a multitude of structures. Among those are the hard and soft palate, tongue, and floor of the mouth.

#### 1.5.4 Hard Palate

The hard palate (*palatum durum*) is the soft tissue covered, bony vault of the oral cavity proper. It has a median raphe dividing the left and the right sides. The transverse epithelial ridges that radiate out from the median raphe are known as rugae. The rugae should

meet symmetrically at the median raphe. Asymmetrical junctures of the rugae at the raphe may be an indication of poor migration of the left and right maxillary processes and a tendency toward cleft palate formation. It is not uncommon to find this asymmetrical rugal pattern in parents of cleft palate puppies. At the beginning of the raphe, immediately caudal to the two central incisor teeth, is a single rounded elevation of tissue known as the incisive papilla (*papilla incisiva*). At each lateral side of the incisive papilla are slit-shaped openings to the incisive ducts (*ductus incisivus*), which pass through the palatine fissure connecting the nasal and oral cavities. From the incisive papilla, the paired incisive ducts travel dorsocaudally to open into each nasal fossa; along their route they also communicate with the paired vomeronasal organs (*organum vomeronasale*). Deep to the incisive papilla is the incisive foramen through which the nasopalatine nerve travels to the soft tissue palatal to the rostral maxillary teeth.

#### 1.5.5 Soft Palate

The soft palate (*palatum molle* or *velum palatinum*) is the unsupported soft tissue that extends caudally from the hard palate, free of the support of the palatine bone. It is relatively thick at its attachment to the hard palate and thins at the margins. In a relaxed state it typically makes contact with the oral surface of the epiglottis, but may also make contact with the respiratory surface of the epiglottis. The hard and soft palates serve to separate the oral cavity from the nasal cavity.

### 1.6 Osseous Tissue

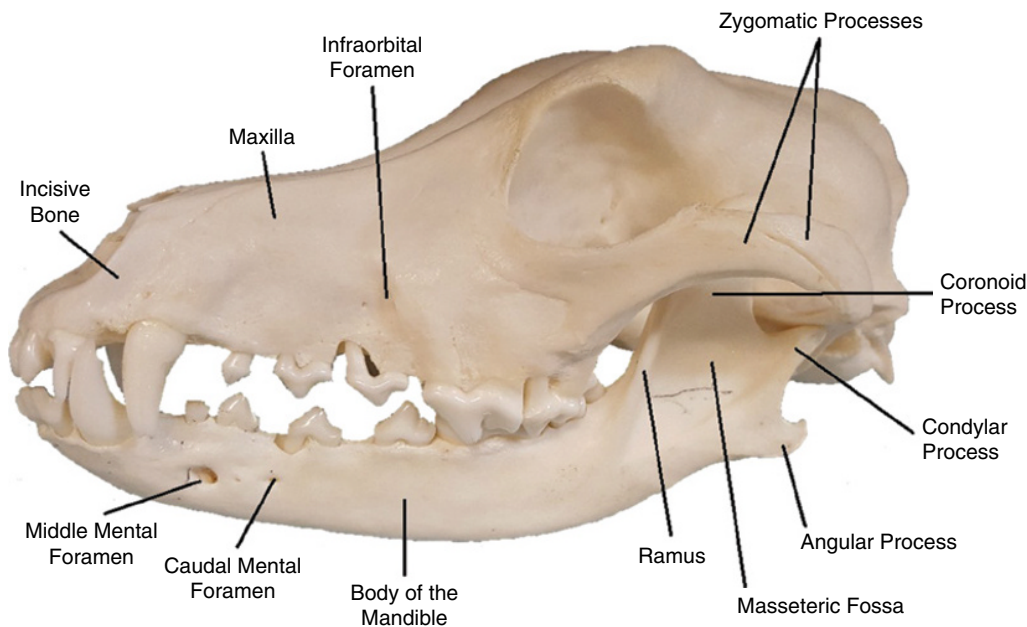
The head consisting of the skull and mandible support all the teeth. The incisive (formerly premaxillae in the dog and still considered such in some species), maxillary, and mandibular bones have sockets, in which the teeth are seated. This firm attachment of teeth to support is termed *thecodontia*. The alveolar process is that portion of these bones that encompass and support the tooth structure. It is comprised of a cortical plate, trabecular bone, and the cribriform plate. The cortical plate is the outside wall of the process. The cribriform plate, known radiologically as the lamina dura, is the thin layer of bone within the tooth socket. Trabecular bone acts as the support between the cortical plate and the lamina dura. The alveolar crest is the occlusal portion of the alveolar process near the neck of the tooth. The bony partitions between adjacent teeth are referred to as interalveolar septa. Partitions between roots of an individual tooth are known as interradicular septa. The mandibles and maxillae containing the teeth are known as the jaws.

The paired incisive bones accommodate the six maxillary incisor teeth. The bones meet at the mesial line and each articulates with the ipsilateral maxilla at the incisivomaxillary suture. The root of the maxillary canine tooth passes through this suture with the incisive bone housing a portion of the alveolus on the palatal side. The paired palatine fissures are situated in the palatine process of each maxillae directly caudal to the incisor teeth. The main branches of the palatine vessels pass through these fissures. The maxillae act as the mooring for the remainder of the upper dentition. This includes the bulk of the canine, four premolars, and two molars in each maxilla in the dog. The maxillae contain the canine, three premolars, and single molar in the cat. Its lateral wall is relatively thin. This results in prominences in the alveolar bone lateral to many of the tooth roots. These prominences, called alveolar juga, act as landmarks in certain surgical endodontic procedures. The palatine process of each mandible projects medially and along with the paired incisive and palatine bones, serve as the bony support of the hard palate. The mandibles are two bilateral bones attached rostrally at the midline by a strong fibrous joint, referred to as the mandibular symphysis. Each mandible is comprised of two major sections, the body, and ramus (Figure 1.6). The body is composed of the incisive part (*Pars incisiva*) containing the incisors and the molar part (*Pars molaris*), which contains the premolars and molars. On the medial surface of the body at the caudal extent the mandibular foramen is present, located at midpoint between the third molar and angular process in the dog. The mandibular artery, vein,

and nerve enter the mandibular canal through this foramen. The artery, vein, and nerve exit the mandibular canal via the rostral, middle, and caudal mental foramina. The rostral mental foramen is located in the incisive part of the mandible between the first and second incisors. The middle mental foramen is located in the molar part at about the level of the apex of the mesial root of the second premolar in the dog and at the level of the labial frenulum in the cat. The caudal mental foramen is located between the two roots of the third premolar.

The ramus constitutes the coronoid process, the condylar process, and the angular process and serves as the majority of insertion for the muscles of mastication. Projecting caudal from the ramus is the neck of the mandible, which supports the head, making the condylar process (<http://www.avdc.org/nomenclature.html>). The temporomandibular joint (TMJ) is formed by the condylar process of the mandible and the mandibular fossa of the temporal bone. This joint is sometimes referred to as the craniomandibular articulation (CMA). Depending on the species, the joint makes both translation and rotation movement capabilities, which allows for both rostral and lateral movement to a degree, as well as its rotation hinge action. The joint is separated into two compartments, the dorsal (temporal) and ventral (mandibular) by an articular disc. The disc attaches to the temporal bone caudomedially and to the condylar process laterally [31]. Fibrous tissue surrounds the joint capsule, which forms its strong lateral ligament.

A shallow concavity is present on the lateral aspect of the ramus named the masseteric fossa, which is the



**Figure 1.6** Normal skull anatomy of the dog.