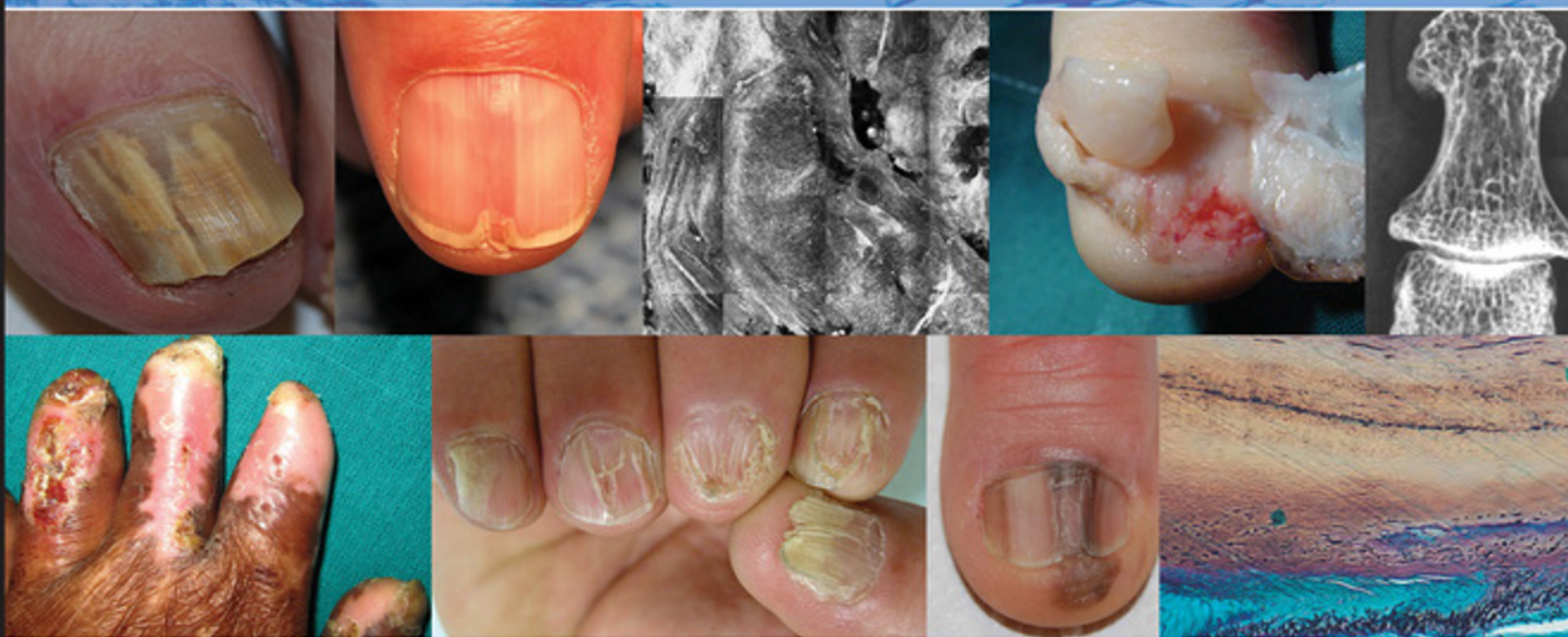

FIFTH EDITION

# BARAN & DAWBER'S Diseases of the Nails and their Management



EDITED BY

Robert Baran, David de Berker,  
Mark Holzberg, Bianca Maria Piraccini,  
Bertrand Richert, and Luc Thomas

WILEY Blackwell



**Baran & Dawber's Diseases of the Nails  
and their Management**





# Baran & Dawber's Diseases of the Nails and their Management

Fifth Edition

Edited by

*Robert Baran, MD, PhD*

*Hon. Pr. of the University of Franche-Comté; Nail Disease Centre, Cannes, France*

*David de Berker, BA, MBBS, MRCP, PhD*

*Bristol Dermatology Centre, Bristol Royal Infirmary, Bristol, UK*

*Mark Holzberg, MD, PhD*

*Department of Dermatology, Emory University School of Medicine, Atlanta, GA, USA*

*Bianca Maria Piraccini, MD, PhD*

*Division of Dermatology, Department of Experimental, Diagnostic and Specialty Medicine,  
University of Bologna, Bologna, Italy*

*Bertrand Richert, MD, PhD*

*Department of Dermatology, Brugmann, St Pierre and Queen Fabiola University Hospitals,  
Université Libre de Bruxelles, Brussels, Belgium*

*Luc Thomas, MD, PhD*

*Department of Dermatology, Centre Hospitalier Lyon Sud; Lyon Cancer Research Center  
(Pr Puisieux); Lyon 1 Claude Bernard University, Lyon, France*

**WILEY** Blackwell

This edition first published 2019  
© 2019 John Wiley & Sons Ltd

*Edition History*

John Wiley & Sons Ltd (4e, 2012); (3e, 2001); (2e, 1994); (1e, 1984)

All rights reserved. No part of this publication may be reproduced, stored in a retrieval system, or transmitted, in any form or by any means, electronic, mechanical, photocopying, recording or otherwise, except as permitted by law. Advice on how to obtain permission to reuse material from this title is available at <http://www.wiley.com/go/permissions>.

The right of Robert Baran, David de Berker, Mark Holzberg, Bianca Maria Piraccini, Bertrand Richert, and Luc Thomas to be identified as the authors of the editorial material in this work has been asserted in accordance with law.

*Registered Office(s)*

John Wiley & Sons, Inc., 111 River Street, Hoboken, NJ 07030, USA  
John Wiley & Sons Ltd, The Atrium, Southern Gate, Chichester, West Sussex, PO19 8SQ, UK

*Editorial Office*

9600 Garsington Road, Oxford, OX4 2DQ, UK  
The Atrium, Southern Gate, Chichester, West Sussex, PO19 8SQ, UK

For details of our global editorial offices, customer services, and more information about Wiley products visit us at [www.wiley.com](http://www.wiley.com).

Wiley also publishes its books in a variety of electronic formats and by print-on-demand. Some content that appears in standard print versions of this book may not be available in other formats.

*Limit of Liability/Disclaimer of Warranty*

The contents of this work are intended to further general scientific research, understanding, and discussion only and are not intended and should not be relied upon as recommending or promoting scientific method, diagnosis, or treatment by physicians for any particular patient. In view of ongoing research, equipment modifications, changes in governmental regulations, and the constant flow of information relating to the use of medicines, equipment, and devices, the reader is urged to review and evaluate the information provided in the package insert or instructions for each medicine, equipment, or device for, among other things, any changes in the instructions or indication of usage and for added warnings and precautions. While the publisher and authors have used their best efforts in preparing this work, they make no representations or warranties with respect to the accuracy or completeness of the contents of this work and specifically disclaim all warranties, including without limitation any implied warranties of merchantability or fitness for a particular purpose. No warranty may be created or extended by sales representatives, written sales materials or promotional statements for this work. The fact that an organization, website, or product is referred to in this work as a citation and/or potential source of further information does not mean that the publisher and authors endorse the information or services the organization, website, or product may provide or recommendations it may make. This work is sold with the understanding that the publisher is not engaged in rendering professional services. The advice and strategies contained herein may not be suitable for your situation. You should consult with a specialist where appropriate. Further, readers should be aware that websites listed in this work may have changed or disappeared between when this work was written and when it is read. Neither the publisher nor authors shall be liable for any loss of profit or any other commercial damages, including but not limited to special, incidental, consequential, or other damages.

*Library of Congress Cataloging-in-Publication Data*

Names: Baran, R. (Robert), editor.

Title: Baran & Dawber's diseases of the nails and their management / [edited by] Robert Baran, David A.R. de Berker, Mark J. Holzberg, Bianca Maria Piraccini, Bertrand Richert, Luc Thomas.

Other titles: Baran and Dawber's diseases of the nails and their management | Diseases of the nails and their management

Description: Fifth edition. | Hoboken, NJ : Wiley-Blackwell, 2019. | Includes bibliographical references and index. |

Identifiers: LCCN 2018038792 (print) | LCCN 2018039737 (ebook) | ISBN 9781119324256 (Adobe PDF) |

ISBN 9781119324225 (ePub) | ISBN 9781119323358 (hardback)

Subjects: | MESH: Nail Diseases | Nails—physiology | Nails, Malformed

Classification: LCC RL165 (ebook) | LCC RL165 (print) | NLM WR 475 | DDC 616.5/47—dc23

LC record available at <https://lccn.loc.gov/2018038792>

Cover Design: Wiley

Cover Images: On the top row, image 1, courtesy of Bianca Maria Piraccini; images 2 and 3, courtesy of Luc Thomas; images 4 and 5, courtesy of Bertrand Richert. On the bottom row, image 6, courtesy of Archana Singal; images 7 and 8, courtesy of Bianca Maria Piraccini; image 9, courtesy of Robert Baran

Set in 10/12pt Warnock by SPi Global, Pondicherry, India

## Contents

List of Contributors	vii
List of Abbreviations	ix
Foreword	xi
Preface	xiii
About the Companion Website	xiv

### Part I The Normal Nail and Nail Signs 1

- 1 Science of the Nail Apparatus 1  
*David de Berker, Beth S. Ruben, and Robert Baran*
- 2 Physical Signs 59  
*Adam Rubin, Mark Holzberg, and Robert Baran*

### Part II Imaging of the Nail Unit 105

- 3 Nail Photography 105  
*Paola Pasquali*
- 4 Dermoscopy 113  
*Luc Thomas, Sébastien Debarbieux, and Amélie Boespflug*
- 5 Ultrasound and Other Imaging Methods 140  
*Ximena Wortsman, Gregor B.E. Jemec, and Axel Villani*
- 6 Magnetic Resonance Imaging 175  
*Jean-Luc Drapé*
- 7 Nail Fold Capillary Microscopy or Capillaroscopy 201  
*Gregor B.E. Jemec*
- 8 Confocal Microscopy 204  
*Sébastien Debarbieux, Amélie Boespflug, Bruno Labeille, and Luc Thomas*

### Part III Nail Disorders Occurring Principally in Childhood 213

- 9 Hereditary and Congenital Nail Disorders 213  
*Smail Hadj-Rabia, Rudolf Happle, Bianca Maria Piraccini, and Robert Baran*
- 10 Nail Disorders in Childhood 297  
*David de Berker, Bianca Maria Piraccini, Beth S. Ruben, and Robert Baran*

**Part IV Nail Disorders in the Elderly 337**

- 11 The Aging Nail and Related Disorders 337**  
*Bertrand Richert*

**Part V Nail Infections 349**

- 12 Fungal (Onychomycosis) and Other Infections Involving the Nail Apparatus 349**  
*Roderick J. Hay, Boni Elewski, Bianca Maria Piraccini, Nikki Sullivan, Casey Wang, and Robert Baran*
- 13 Bacterial, Viral, and Other Infections 390**  
*Archana Singal and Bertrand Richert*

**Part VI The Nail in Dermatological Conditions 409**

- 14 Dermatological Disorders 409**  
*Bianca Maria Piraccini, Mark Holzberg, Marcel Pasch, and Dimitrios Rigopoulos*

**Part VII The Nail in Systemic Conditions 481**

- 15 The Nail in Systemic Disease 481**  
*Mark Holzberg and Bianca Maria Piraccini*
- 16 Drug-induced Nail Disorders 574**  
*Bianca Maria Piraccini*
- 17 Anticancer Therapies 604**  
*Vincent Sibaud, Robert Baran, Bianca Maria Piraccini, Mario E. Lacouture, and Caroline Robert*

**Part VIII The Nail in Occupational, Podiatric, and Cosmetic Conditions 617**

- 18 Occupational Abnormalities and Contact Dermatitis 617**  
*Robert Baran and An Goossens*
- 19 Cosmetics: the Care and Adornment of the Nail 646**  
*Douglas Schoon and Robert Baran*
- 20 Trauma from Footwear and Pedal Deformities 662**  
*Bertrand Richert*

**Part IX Nail Tumors and Surgery 675**

- 21 Tumors of the Nail Apparatus and Adjacent Tissues 675**  
*Marcel Pasch, Eckart Haneke, Robert Baran, Luc Thomas, and Bertrand Richert*
- 22 Nail Surgery 825**  
*Bertrand Richert, Eckart Haneke, Elvin G. Zook, and Robert Baran*

**Appendix 896**  
*Mark Holzberg*

**Index 949**



## List of Contributors

**Robert Baran, MD, PhD**

Hon. Pr. of the University of Franche-Comté;  
Nail Disease Centre, Cannes, France

**Amélie Boespflug, MD, PhD**

Department of Dermatology, Centre Hospitalier Lyon  
Sud; Lyon Cancer Research Center (Pr Puisieux);  
Lyon 1 Claude Bernard University, Lyon, France

**Sébastien Debarbieux, MD**

Department of Dermatology, Centre Hospitalier Lyon  
Sud; Lyon Cancer Research Center (Pr Puisieux);  
Lyon 1 Claude Bernard University, Lyon, France

**David de Berker, BA, MBBS, MRCP, PhD**

Bristol Dermatology Centre, Bristol Royal Infirmary,  
Bristol, UK

**Jean-Luc Drapé, MD, PhD**

Department of Radiology, Hôpital Cochin, University  
Paris Descartes, Sorbonne Paris Centre, France

**Boni Elewski, MD**

Department of Dermatology, The University of  
Alabama at Birmingham, Birmingham, AL, USA

**An Goossens, RPharm, PhD**

Professor Emeritus, Contact Allergy Unit, University  
Hospital K.U. Leuven, Leuven, Belgium

**Smail Hadj-Rabia, MD, PhD**

Department of Dermatology and Reference Center for  
Genodermatoses and Rare Skin Diseases; University  
Paris Descartes - Sorbonne Paris Cité; Institut Imagine,  
Paris, France

**Eckart Haneke, MD, PhD**

Department of Dermatology, University of Bern, Bern,  
Switzerland; Centro de Dermatología Epidermis, Porto,  
Portugal; Department of Dermatology, University of  
Ghent, Ghent, Belgium

**Rudolf Happle, MD**

Universitäts-Hautklinik, Freiburg, Germany

**Roderick J. Hay, DM, FRCP**

King's College London, London, UK

**Mark Holzberg, MD, PhD**

Department of Dermatology, Emory University School  
of Medicine, Atlanta, GA, USA

**Gregor B.E. Jemec, MD, DMSc**

Department of Dermatology, Zealand University  
Hospital, Roskilde; Health Sciences Faculty,  
University of Copenhagen, Copenhagen, Denmark

**Bruno Labeille, MD**

Dermatology Department, Hôpital Nord, Saint Etienne,  
France

**Mario E. Lacouture, MD, PhD**

Dermatology Service, Memorial Sloan Kettering  
Cancer Center, New York, NY, USA

**Marcel Pasch, MD, PhD**

Department of Dermatology, Radboud University  
Medical Center, Nijmegen, The Netherlands

**Paola Pasquali, MD**

Pius Hospital de Valls, Tarragona, Spain

**Bianca Maria Piraccini, MD, PhD**

Dermatology, Department of Experimental, Diagnostic  
and Specialty Medicine, University of Bologna,  
Bologna, Italy

**Bertrand Richert, MD, PhD**

Department of Dermatology, Brugmann, St Pierre and  
Queen Fabiola University Hospitals, Université Libre de  
Bruxelles, Belgium

***Dimitrios Rigopoulos, MD***

National and Kapodistrian University of Athens; Medical School, University Hospital “A. Sygros”; Department of Dermatology and Venereology, Athens, Greece

***Caroline Robert, MD, PhD***

Department of Dermatology, Institut Gustave Roussy, Villejuif; Department of Dermatology, Paris-Sud University, Orsay, France

***Beth S. Ruben, MD***

Dermatology/Dermatopathology, University of California, San Francisco; Dermatopathology, Palo Alto Medical Foundation, Palo Alto, CA, USA

***Adam Rubin, MD***

Departments of Dermatology, Pediatrics, and Pathology and Laboratory Medicine, Hospital of the University of Pennsylvania; Children’s Hospital of Philadelphia, Perelman School of Medicine at the University of Pennsylvania, Philadelphia, PA, USA

***Douglas Schoon, MS***

Schoon Scientific + Regulatory Consulting LLC, Dana Point, CA, USA

***Vincent Sibaud, MD***

Department of Oncodermatology, Institut Universitaire du Cancer – Toulouse Oncopole, Toulouse, France

***Archana Singal, MD, MNAMS***

Department of Dermatology and STD, University College of Medical Sciences, Delhi, India

***Nikki Sullivan, MD***

Department of Dermatology, University of Michigan, Ann Arbor, MI, USA

***Luc Thomas, MD, PhD***

Department of Dermatology, Centre Hospitalier Lyon Sud; Lyon Cancer Research Center (Pr Puisieux); Lyon 1 Claude Bernard University, Lyon, France

***Axel Villani, MD***

Dermatology Department, Edouard Herriot Hospital, Lyon 1 Claude Bernard University, Lyon, France

***Casey Wang, MD***

Department of Dermatology, The University of Alabama at Birmingham, Birmingham, AL, USA

***Ximena Wortsman, MD***

Institute for Diagnostic Imaging and Research of the Skin and Soft Tissues; Departments of Dermatology, University of Chile and Pontifical Catholic University of Chile, Santiago, Chile

***Elvin G. Zook, MD (Deceased)***

*Formerly*, Plastic Surgery Institute, Southern Illinois University, School of Medicine, Springfield, IL, USA

## List of Abbreviations

3D	three-dimensional	EO	endonyx onychomycosis
ACA	anticardiolipin antibody	FDA	US Food and Drug Administration
ACTH	adrenocorticotrophic hormone	FEF	forced expiratory flow
ADFK	acquired digital fibrokeratoma	FEV1	forced expiratory volume in 1 second
ADL	activities of daily living	GVHD	graft-versus-host disease
AER	apical ectodermal ridge	H&E	hematoxylin and eosin
AIDS	acquired immunodeficiency syndrome	HEMA	hydroxy-ethylmethacrylate
ALHE	angiolympoid hyperplasia with eosinophilia	HFMD	hand-foot-mouth disease
ALM	acrolentiginous melanoma	HIV	human immunodeficiency virus
AORN	Association of Operating Room Nurses	HOOD	hereditary osteonychodysplasia
APACHE	acral pseudolymphomatous angiokeratoma of children	HPV	human papillomavirus
APES	aminopropyltriethoxysilane	HSR	high spatial resolution
AVA	arteriovenous anastomoses	HSV	herpes simplex virus
AVF	arteriovenous fistula	HTLV	human T-cell leukemia virus
BDD	blistering distal dactylitis	IDS	International Dermoscopy Society
BMP	bone morphogenetic protein	ILM	incident light microscopy
BMZ	basement membrane zone	ILVEN	inflammatory linear verrucous epidermal nevus
BPNH	bilateral periventricular nodular heterotopia	IP	incontinentia pigmenti
CA	cyanoacrylate	IU	international units
CARI	congenital autosomal recessive ichthyosis	IVT	ischemic venous thrombosis
CDC	Centers for Disease Control	KA	keratoacanthoma
CEA	carcinoembryonic antigen	KID	keratosis, ichthyosis, and deafness
CMC	chronic mucocutaneous candidiasis	LE	lupus erythematosus
CMV	cytomegalovirus	LED	light-emitting diode
COIF	congenital onychodysplasia of the index fingers	LM	longitudinal melanonychia
CT	computed tomography	MES	multiple exostoses syndrome
DBP	dibutyl phthalate	MIC	minimum inhibitory concentration
DEB	dystrophic epidermolysis bullosa	MIM	Mendelian Inheritance in Man
DIP	distal interphalangeal	MIP	maximum intensity projection
DLSO	distal and lateral subungual onychomycosis	MMA	methylmethacrylate
DMPS	dimercapto-propane sulfonate	MRI	magnetic resonance imaging
DMSA	dimercaptosuccinic acid	MSH	melanocyte-stimulating hormone
DMSO	dimethyl sulfoxide	NAPSI	Nail Psoriasis Severity Index
EB	epidermolysis bullosa	NTOM	nerve territory-orientated macrodactyly
EBA	epidermolysis bullosa acquisita	PA	posteroanterior
ED	ectodermal dysplasia	PAI	plasminogen activator inhibitor
EGFR	epidermal growth factor receptor	PaO <sub>2</sub>	partial pressure of oxygen in arterial blood
EM	electron microscopy	PAS	periodic acid-Schiff
EMA	epithelial membrane antigen	PCB	polychlorinated biphenyl
		PCR	polymerase chain reaction
		PIU	pterygium inversum unguis
		PNF	proximal nail fold

PRP	pityriasis rubra pilaris	STIR	short time inversion recovery
PSO	proximal subungual onychomycosis	SWO	superficial white onychomycosis
PUVA	psoralen ultraviolet A	T	tesla
PVC	polyvinyl chloride	TAR	thrombocytopenia absent radius
PWSO	proximal white subungual onychomycosis	TDO	total dystrophic onychomycosis
RA	rheumatoid arthritis	TGF	transforming growth factor
ROS	reactive oxygen species	TNF	tumor necrosis factor
RV	residual volume	TOWL	transonychia water loss
SCC	squamous cell carcinoma	TTD	trichothiodystrophy
SE	spin echo	TUDDS	transungual drug delivery system
SLE	systemic lupus erythematosus	TUNEL	terminal deoxynucleotidyl transferase dUTP nick end labeling
SLN	sentinel lymph node	US	ultrasonography
SLR	single-lens reflex	UV	ultraviolet
SM	subungual melanoma	UVB	ultraviolet B
SNR	signal-to-noise ratio	VEGF	vascular endothelial growth factor
SO	subungual onychomycosis		
SSM	superficial spreading melanoma		

## Foreword

The fifth edition of *Baran & Dawber's Diseases of the Nails and their Management* is a lovely tribute to this fascinating and distinctive keratinized structure. Based upon the cumulative and vast experience of the authors, the book offers insights that are both well honed and practical. There is also an appreciation of the spectrum of clinical presentations of the various dermatological disorders that can affect the nail unit. Although overlapping clinical and histopathological features can be seen when a specific disease involves the skin versus the nail unit, this textbook succeeds in emphasizing those findings that are unique to the latter. An abundance of high-quality clinical photographs, combined with beautiful dermoscopic images and exceptional schematics, provide the reader with a wealth of useful information. I was particularly struck by the sophisticated nature of the discussion on trauma-induced nail changes, a topic that is sometimes erroneously viewed as mundane but has to be accurately diagnosed on a daily basis.

Patients with nail disorders, as well as the clinicians who care for those patients, will clearly benefit from the knowledge contained in these chapters, from logical approaches to diagnosis to effective therapeutic interventions. I speak for my colleagues when I say we are lucky to have such a body of worthwhile information so nicely organized for our consumption.

*Jean Bologna, MD*  
Professor of Dermatology  
Yale School of Medicine





## Preface

Diseases of the nail unit have fascinated physicians for centuries, beginning with Hippocrates. The nail is considered to be the window to the body, manifesting signs of internal disease and clues to one's health. Over time, more and more nail signs of skin disease and tumors arising in the nail apparatus have been studied and revealed.

The first edition of Drs. Baran and Dawber's textbook *Diseases of the Nails and their Management*, published in 1984, was a pioneering work. It became a much needed reference for physicians and students wanting a compendium on nail disease. With each edition, the text has become more comprehensive, making it the most complete and most read textbook on the subject – the authority on nail disease.

With the fifth edition, we are pleased to have increased our group of editors to include more diverse, experienced nail clinicians from Belgium and Italy. Textbooks, like this one, require unwavering, dedicated work from our contributors as well as from our publisher. Carefully chosen nail clinicians have authored each chapter, each of them a recognized leader in their subspecialty of nail disease. We wish to thank our

publisher, Wiley, for their support in our requests and our endeavor to ensure that the text remains the recognized leader in nail disease. We especially want to thank Dr. Robert Baran for his enthusiasm and dedication in ensuring that each of the five editions has been thoughtful and complete. He and his wife, Nicole – a dedicated, though behind-the-scenes, editor – make an unbeatable team.

The fifth edition of *Diseases of the Nails and their Management* has been expanded to include new diseases and updated treatments, improved chapter organization, and new online video supplements. It is our sincere hope that the fifth edition of *Diseases of the Nails and their Management* broadens your knowledge of nail disease and becomes your primary reference on this subject, as it has ours.

*David de Berker*  
*Mark Holzberg*  
*Bianca Maria Piraccini*  
*Bertrand Richert*  
*Luc Thomas*

## About the Companion Website

This book is accompanied by a companion website:

[www.wiley.com/go/BaranandDawber](http://www.wiley.com/go/BaranandDawber)

The website includes:

- Videos of ultrasound imaging of the nail
- All images from the book

## Part I

# The Normal Nail and Nail Signs

## Chapter 1

### Science of the Nail Apparatus

David de Berker<sup>1</sup>, Beth S. Ruben<sup>2,3</sup>, and Robert Baran<sup>3</sup>

<sup>1</sup>Bristol Dermatology Centre, Bristol Royal Infirmary, Bristol, UK

<sup>2</sup>Dermatology/Dermatopathology, University of California, San Francisco  
Dermatopathology, Palo Alto Medical Foundation, Palo Alto, CA, USA

<sup>3</sup>Hon. Pr. of the University of Franche-Comté; Nail Disease Centre, Cannes, France

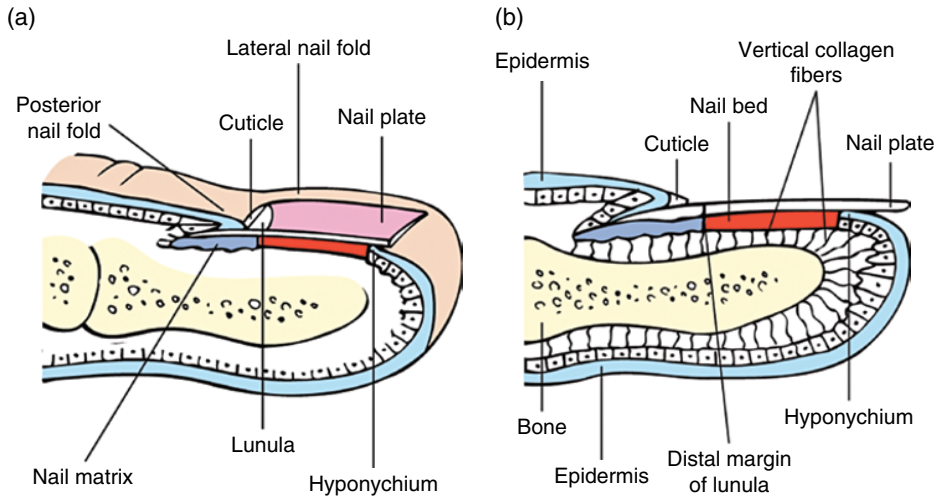
#### CHAPTER MENU

<b>Gross anatomy and terminology, 1</b>	Nail plate, 17	Phylogenetic comparisons, 28
<b>Embryology, 3</b>	<b>Vascular supply, 22</b>	<b>Physiology, 32</b>
Morphogenesis, 3	Arterial supply, 22	Nail production, 32
Tissue differentiation, 4	Venous drainage, 23	Normal nail morphology, 34
Factors in embryogenesis, 5	Effects of altered vascular supply, 23	Nail growth, 36
Histological preparation, 7	Nail fold vessels, 23	Nail plate biochemical analysis, 39
<b>Regional anatomy, 12</b>	Glomus bodies, 24	<b>Physical properties of nails, 42</b>
Nail matrix and lunula, 12	<b>Nerve supply, 25</b>	Strength, 42
Nail bed and hyponychium, 13	<b>Comparative anatomy and function, 26</b>	Permeability, 43
Nail folds, 15	The nail and other appendages, 26	Radiation penetration, 44

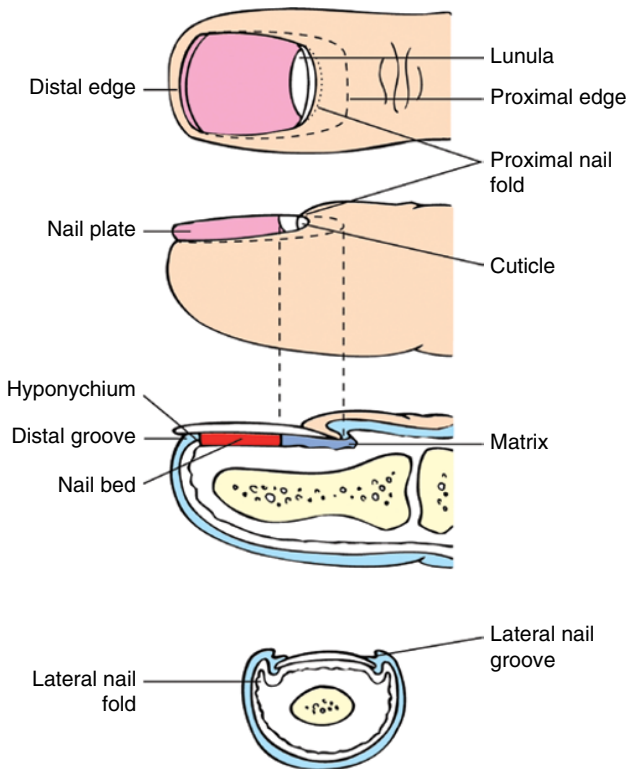
### Gross anatomy and terminology

Knowledge of nail unit anatomy and terms is important for clinical and scientific work [1, 2]. The nail is an opalescent window through to the vascular nail bed. It is held in place by the nail folds, origin at the matrix, and attachment to the nail bed. It ends at a free edge distally, overlying the hyponychium. These structures are illustrated in Figs 1.1–1.4. Definitions of the components of the nail unit are as follows.

- **Nail plate (nail):** durable keratinized structure which continues growing throughout life.
- **Lateral nail folds:** the cutaneous folded structures providing the lateral borders to the nail.
- **Proximal nail fold (posterior nail fold):** cutaneous folded structure providing the visible proximal border of the nail, continuous with the cuticle. On the under-surface this becomes the dorsal matrix.
- **Cuticle (eponychium):** the layer of epidermis extending from the proximal nail fold and adhering to the dorsal aspect of the nail plate.
- **Nail matrix (nail root):** traditionally, this can be split into three parts [3]. The dorsal matrix is synonymous with the ventral aspect of the proximal nail fold. The intermediate matrix (germinative matrix) is the epithelial structure starting at the point where the dorsal matrix folds back on itself to underlie the proximal nail. The ventral matrix is synonymous with the nail bed and starts at the border of the lunula, where the intermediate matrix stops. It is limited distally by the hyponychium.
- **Lunula (half moon):** the convex margin of the intermediate matrix seen through the nail. It is paler than the adjacent nail bed. It is most commonly visible on the thumbs and great toes. It may be concealed by the proximal nail fold.
- **Nail bed (ventral matrix, sterile matrix):** the vascular bed upon which the nail rests, extending from the lunula to the hyponychium. This is the major territory seen through the nail plate.
- **Onychodermal band:** the distal margin of the nail bed has a contrasting hue in comparison with the rest of the nail bed [4]. Normally, this is a transverse

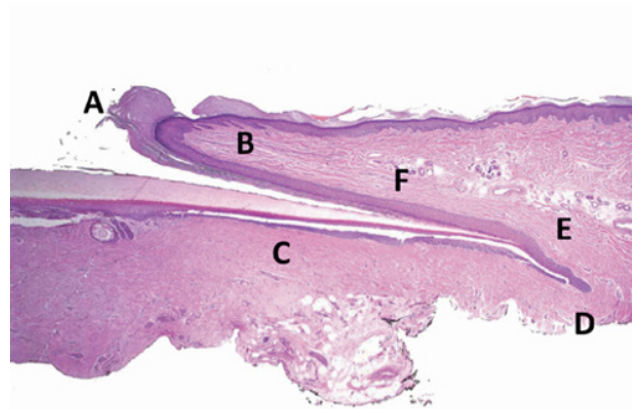


**Figure 1.1** (a,b) Longitudinal section of a digit showing the dorsal nail apparatus.



**Figure 1.2** The tip of a digit showing the component parts of the nail apparatus.

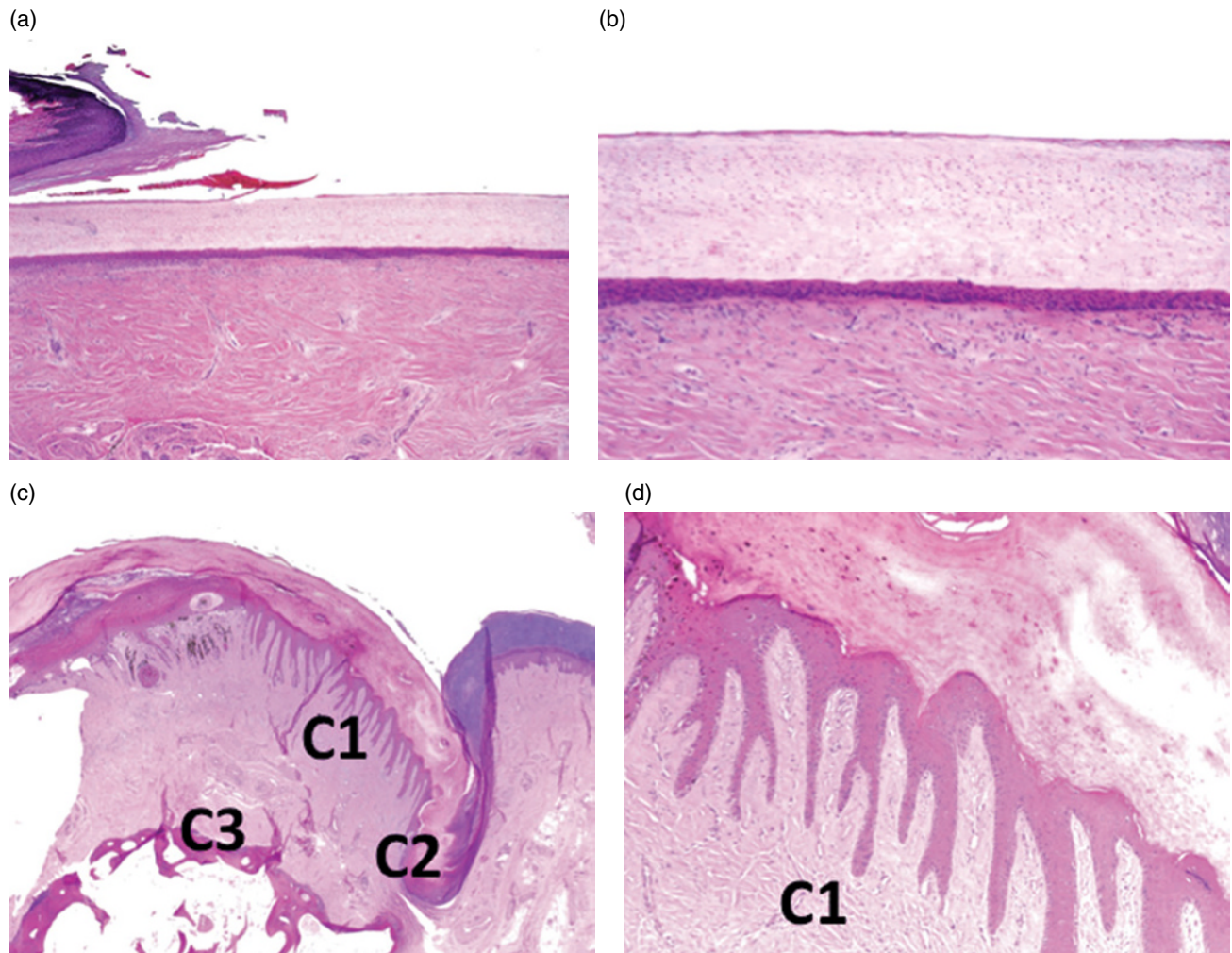
band of 1–1.5 mm of a deeper pink (white) or brown (Afro-Caribbean). Its color, or presence, may vary with disease or compression, which influences the vascular supply (Fig. 1.5). Sonnex et al. [5] examined 1000 nails from thumbs and fingers in 100 subjects, alive and dead. In addition to clinical observation, they obtained histology from cadavers. Their findings



**Figure 1.3** Proximal nail unit in longitudinal excision. Longitudinal view. A, Cuticle. B, Proximal nail fold. C, Distal matrix including keratogenous zone. D, Proximal matrix. E, Dorsal matrix. F, Ventral aspect of proximal nail fold.

are summarized in Table 1.1. The onychodermal band represents the first barrier to penetration of materials beyond the nail plate. Disruption of this barrier by disease or trauma precipitates a range of further events affecting the nail bed. The white appearance of the central band represents the transmission of light from the digit tip through the stratum corneum and up through the nail. If the digit is placed against a black surface, the band appears dark.

- **Hyponychium:** the cutaneous margin underlying free nail, bordered distally by the distal groove (Fig. 1.6).
- **Distal groove (limiting furrow):** a cutaneous ridge demarcating the border between subungual structures and the digit pulp.



**Figure 1.4** Distal nail matrix and nail bed in longitudinal excision. (a,b) Longitudinal view of the distal matrix and nail bed epithelium with overlying nail plate. (c,d) Transverse sections of the nail unit taken from an amputation for melanoma illustrating the nail bed longitudinal ridges in cross-section (C1), lateral nail groove (C2), and underlying phalanx (C3).

## Embryology

### Morphogenesis

#### 8–12 weeks

Individual digits are discernible from the 8th week of gestation [3]. The first embryonic element of the nail unit is the nail anlage, present from 9 weeks as the epidermis overlying the dorsal tip of the digit. At 10 weeks, a distinct region can be seen and is described as the primary nail field. This almost overlies the tip of the terminal phalanx, with clear proximal and lateral grooves in addition to a well-defined distal groove. The prominence of this groove is partly due to the distal ridge, thrown up proximally, accentuating the contour. The primary nail field grows proximally by a wedge of germinative matrix cells extending back from the tip of the digit. These cells are proximal to both the distal groove and ridge. The spatial relationship of these two latter structures remains

relatively constant as the former becomes the vestigial distal groove and the latter the hyponychium (Fig. 1.7).

#### 13–14 weeks

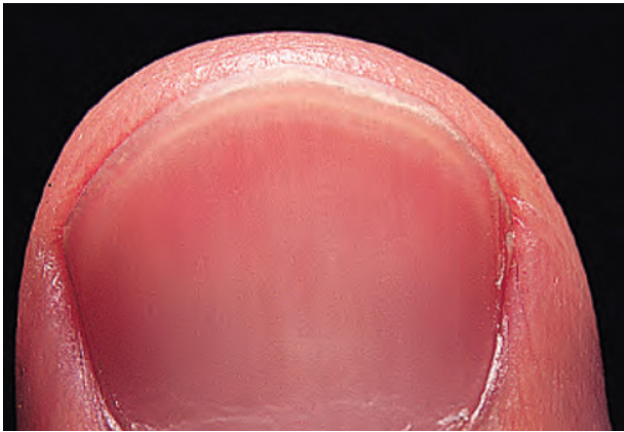
Differential growth of the slowly developing primary nail field and surrounding tissue results in the emergence of overhanging proximal and lateral nail folds. Depending on the point of reference, the nail folds may be interpreted as overhanging [6] or the matrix as invaginating. By 13 weeks the nail field is well defined in the finger, with the matrix primordium underlying a proximal nail fold. By 14 weeks the nail plate is seen emerging from beneath the proximal nail fold, with elements arising from the lunula as well as more proximal matrix.

#### 17 weeks to birth

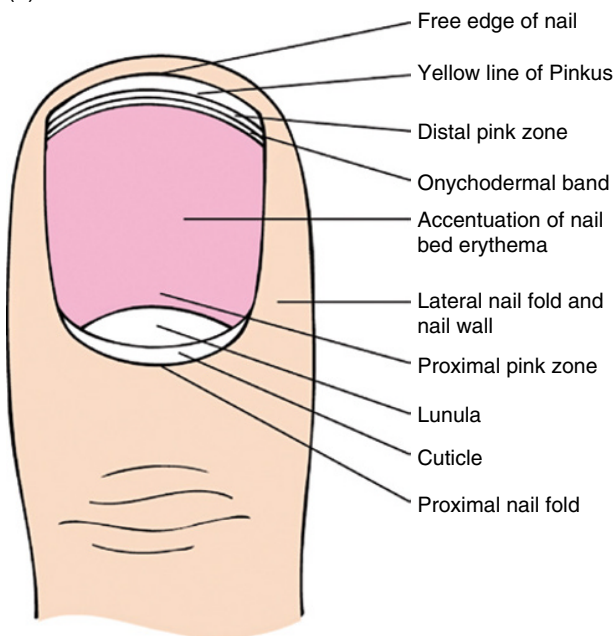
At 17 weeks, the nail plate covers most of the nail bed and the distal ridge has flattened. From 20 weeks, the nail unit and finger grow in tandem, with the nail plate



(a)



(b)



**Figure 1.5** (a) Onychodermal band. (b) Diagrammatic representation of the morphological features of the normal nail; detail of the distal physiological color bands are shown. Courtesy of T.S. Sonnex and W.A.D. Griffiths.

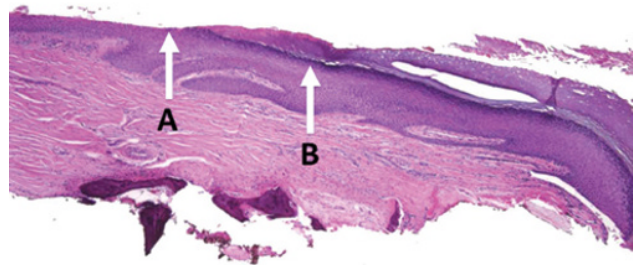
abutting the distal ridge. This is now termed the hyponychium. The nail bed epithelium no longer produces keratohyalin, with a more parakeratotic appearance. By birth the nail plate extends to the distal groove, which becomes progressively less prominent. The nail may curve over the volar surface of the finger. It may also demonstrate koilonychia. This deformity is normal in the very young and a function of the thinness of the nail plate. It reverses with age.

### Tissue differentiation

Keratins belong to the family of intermediate filament proteins. They are responsible for the tough resilient

**Table 1.1** Clinical appearance of distal zones of the nail bed.

Zone	Subzone	Appearance
Free edge	–	Clear gray
Onychocorneal band		
I	Distal pink zone	0.5–2 mm distal pink margin, may merge with free edge
II	Central white band	0.1–1 mm distal white band representing the point of attachment of the stratum corneum arising from the digit pulp
III	Proximal pink gradient	Merging with nail bed



**Figure 1.6** Distal nail unit in longitudinal excision. Onychodermal band (A) at the junction with the hyponychium (B) where a granular zone is again found along with acral compact stratum corneum.

quality of nail. They are found within the cytoplasm. There are 54 human keratin genes with their keratins divided into three categories:

- 1) epithelial keratins/genes
- 2) hair keratins/genes
- 3) keratin pseudogenes.

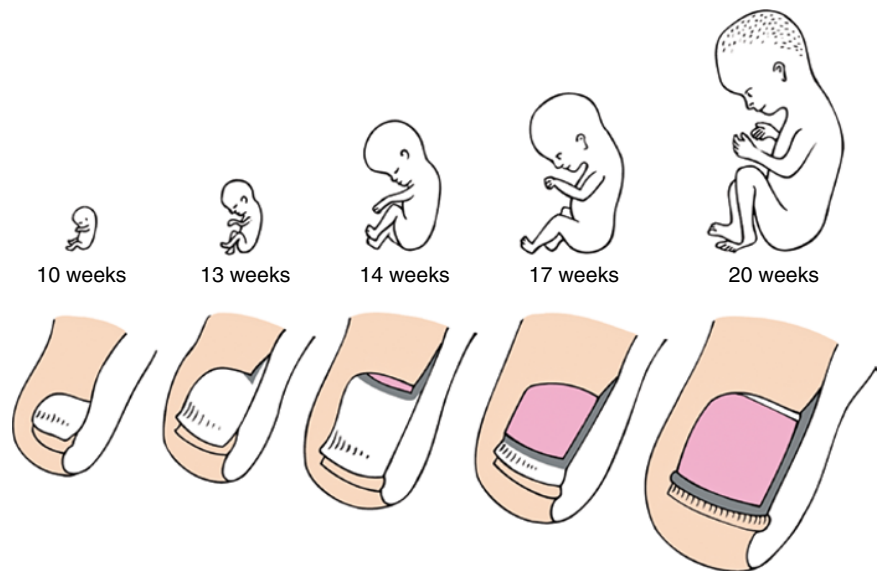
Schweizer et al. [7] devised the reclassification of keratins according to the system described below to accommodate the changing knowledge of keratins in the context of the previous system (Table 1.2).

The element of common ground between hair and nail biology is reflected in many shared keratins that lend physical characteristics to the tissue. Hence, although nail biology is not acknowledged in this scheme, where there is a designation of hair keratin, it is common for it also to be a nail keratin and for the higher level of sulfur amino acids in the keratin to afford a larger number of intramolecular cross-links and greater physical stability and strength.

Keratin synthesis can be identified in the nail unit from the earliest stages of its differentiation [8]. In 12- and



**Figure 1.7** Embryogenesis of the nail apparatus. 10 weeks, The primary nail field can be seen with proximal, lateral, and distal grooves. The latter is accentuated by a distal ridge. 13 weeks, A wedge of matrix primordium moves proximally, with the invagination of the proximal nail fold above. 14 weeks, The nail plate emerges. 17 weeks, The nail plate covers most of the nail bed and the distal ridge starts to flatten. 20 weeks, The nail plate extends to the distal ridge, now termed hyponychium. Finger and nail grow roughly in tandem from now on. Fetuses are one-fifth of the actual size.



**Table 1.2** Keratins and their former designations ([www.interfil.org/proteinsTypeInI.php](http://www.interfil.org/proteinsTypeInI.php)).

Category	Number range
Human type I epithelial keratins	9–28
Human type I hair keratins	31–40
Non-human type I epithelial and hair keratins	41–70
Human type II epithelial keratins	1–8 and 71–80
Human type II hair keratins	81–86
Non-human type II epithelial and hair keratins	87–120
Type II keratin pseudogenes	121–220
Type I keratin pseudogenes	221 →

13-week embryos, the nail–matrix anlage is a thin epithelial wedge penetrating from the dorsal epidermis into the dermis. This wedge is thought to represent the “ventral matrix primordium.” By week 15, hard keratins are seen throughout the nail bed and matrix. This could have significance concerning theories of nail embryogenesis and growth, where debate exists as to the contribution made by the nail bed to nail growth [3, 9–12]. However, at 22 weeks, the layer of hard keratin-positive cells remains very thin in the nail bed, whereas it is considerably thickened in the matrix. In the adult nail, there have been reports of both the presence [13] and absence [8, 14–16] of hard keratins in the nail bed.

Histological observation at 13 and 14 weeks reveals parakeratotic cells just distal to this nail plate primordium staining for sulfhydryl groups. This contrasts to adjacent epithelium, suggesting the start of nail plate differentiation. This early differentiation represents matrix formation and Merkel cells have been detected in the matrix primordium of human fetuses between weeks 9

and 15 [17]. Merkel cells may play a role in the development of epidermal appendages and are detectable using monoclonal antibodies specific to keratin 20 (K20). Their role in ontogenesis would explain their disappearance from the nail matrix after week 22 [17]. However, this is not a universal finding, with an abundance of Merkel cells identified in the matrix of young adult and cadaver nail specimens in one study [18].

At the 13–22-week stage there is a coincident increase in the expression of hard keratins and the development of keratohyalin granules.

By 25 weeks, most features of nail unit differentiation are complete. Changes may still occur in the chemical constitution of the nail plate after this date. A decrease in sulfur and aluminum and a rise in chlorine have been noted as features of full-term newborns in comparison with the nail plate of premature babies [19]. An elevated aluminum level may correspond to bone abnormalities which lead to osteopenia.

### Factors in embryogenesis

The nail plate grows from the 15th week of gestation until death. Many factors act upon it in this time and influence its appearance. Because it is a rugged structure, growing over a cycle of 4–18 months, it provides a record of the effects of these influences. To consider the different formative mechanisms, it is important to distinguish between:

- embryogenesis
- regrowth
- growth.

There is overlap between all these processes, with the main clues concerning embryogenesis deriving from fetal studies and analysis of congenital abnormalities.

Regrowth is the growth of the nail plate following its removal. This may be for therapeutic reasons or following accidental trauma with associated damage. Observation of this process adds to our understanding of both growth and embryogenesis. Growth is the continuous process of nail plate generation over a fully differentiated nail bed and hyponychium. Embryogenesis is the subject of this section.

In the chick limb bud formation, there is a complex interaction between mesoderm and ectoderm. Initially, the mesoderm induces the development of the apical ectodermal ridge (AER). The mesoderm then becomes dependent upon the AER for the creation of the limb. Removal of the AER results in a halt of mesodermal differentiation. Replacing the underlying mesoderm with mesoderm from another part of the limb primordium still results in normal differentiation [20]. However, the AER continues to be dependent upon the mesoderm, which must be of limb type. Replacement of limb mesoderm with somite mesoderm causes flattening of the AER. These morphogenetic interactions occur prior to cytodifferentiation [21]. In the human, cases of onychia secondary to phenytoin [22] might implicate the drug at this stage, prior to 8 weeks. Drugs have been suggested as contributing to congenital nail dystrophies mainly affecting the index finger [23]. Attempts at characterizing a putative nail mesenchyme have involved ectopic nail studies in the newborn and mature nail unit. A CD10-positive population of dermal cells is located in the submatrix and nail bed dermis, which is common to the finding in mesenchyme of the hair follicle [24, 25]. In addition, one compartment has been reported as CD34 positive, which differentiates it from the nail bed where CD10 alone is found [26]. This zone of specialized submatrix tissue has been referred to as the onychodermis and can be identified in specialized magnetic resonance imaging [27].

Subsequent work on limb bud biology has explored the significance of the transcription factor LIMX1B in the mouse embryo limb formation. This factor is implicated in the dorsal/ventral polarity of the evolving limb and has been confirmed to have a similar role in humans. Loss of effective LIM1X function results in duplication of structures such that there might be a ventral ventral digit rather than dorsal ventral where the finger pulp is repeated on both sides of the digit [28]. The LIMX1B system also acts on genes determining development of the eye and urogenital tract, which is the basis for involvement of all these systems in nail–patella syndrome. In this pathology, the differentiation messages from the mesenchyme to the ectoderm appear to be communicated in a manner that might formally be described in observational limb bud experiments.

LIMX1B is thought to be mediated through the spondin pathway, where spondins are a family of proteins

contributing to intracellular communication. In hereditary onychia, there is a defect in R-spondin 4 secretion, where this protein would normally determine the activity of the Wnt/ $\beta$  catenin signaling system that is thought in turn to play a part in the initiation of nail unit formation [29–31]. Frizzled-6 is a Wnt receptor gene. In its absence a knockout mouse manifests a range of changes in the claw, including the downregulation of four hard nail keratins, K86, -81, -34, and -31, two epithelial keratins of significance in the nail unit, K6a and 6b, and transglutaminase-1. These changes are seen with an altered phenotype [32]. Similarly, where  $\beta$  catenin is deleted in knockout mice, nail formation and fingertip regeneration is completely lost, suggesting that the interruption of the Wnt signaling pathway has direct effects. Similar blockade of Wnt signaling results in extension of high Ki67 and K17 expression throughout the matrix, albeit without clear nail production [33]. R-spondin 2 is expressed in the AER in normal mouse limb development [34]. Mice bred to be deficient in this spondin have substantial congenital limb anomalies, with lack of phalangeal development and no nail unit [34]. Consistent with the model of mesenchyme inducing the overlying ectoderm, spondins have been identified in fibroblast cultures but not keratinocyte cultures [35].

Multiple other biological pathways appear relevant to the formation of a normal nail unit. Leucine-rich repeat-containing G protein-coupled receptor 5 and 6 (Lgr5 and -6) are part of the Wnt signaling pathway and associated with stem cell populations in different appendages. Lgr6 is found in the nail matrix and is thought necessary for nail unit regeneration following loss in mice [36]. The concept of a stem cell population is found in other appendages and in the nail it has been relatively difficult to establish such cell populations with confidence. Human embryos between 14 and 23 weeks assessed for expression of three candidate stem cell markers in the evolving nail unit demonstrate markers validated through their expression in the hair follicle bulge. These include PHLDA1 (Pleckstrin homology-like domain, family A, member 1), which is a protein-coding gene, and K15 and -19. These markers are not found in the matrix or nail bed, but have a transient expression in the proximal element of the ventral aspect of the proximal nail fold [37], where they are considered characteristic of stem cell differentiation [38]. A population of K15 label-retaining cells indicative of low turnover is found in a ring-like distribution around the nail root. They have potential to contribute to the nail plate or the nearby epidermis. Nail avulsion creates a wound environment that disposes them to the former, and this in turn appears influenced by bone morphogenetic factors [39]. Proximal matrix cells are characterized by expression of K17 in addition to the normal K14, while having a high proliferation rate as demonstrated through Ki67 and

exhibiting a colony-forming ability *in vitro*; also features that fit with the role of stem cells [33].

Other small molecules with relevance include histone deacetylase and the transcription factor FOX1 (Forkhead box N1). Reduction of histone deacetylase 1 and 2 in the K14 promoter biopathways in mice leads to abnormal appendage formation in embryogenesis. This affects hair follicles and claw formation, with dystrophic hyperpigmented claws. This suggests a role for histone deacetylase in ectodermal differentiation and morphogenesis [40]. FOXN1 (Forkhead box N1) is a transcription factor of significance in thymus epithelium and T-cell differentiation. It is also found in the nail matrix. Mutations with significance to other embryological defects and altered hair are also seen with nail dystrophy. Typically this is koilonychia, which structurally usually corresponds to thinning of the nail [41].

Transgenic mice with changes to the Akt gene demonstrate absent nail and distal bone. Akt is a serine/threonine protein kinase implicated in cell signaling [42]. Although the spondins reside in the mesenchyme and appear relevant to the interaction between mesenchyme and ectoderm, Akt is epithelial and is thought to play a part in the action of bone morphogenetic protein (BMP). BMP is part of the transforming growth factor (TGF)- $\beta$  family of mediators. It is found in many different forms with a range of morphogenetic roles. In relation to the formation of the nail unit, it has been proposed that there is a two-way process whereby it is supportive of nail unit development, but equally that the nail unit plays a part in the regeneration of the distal phalanx when it is lost through trauma in infancy [43]; these processes may in part be mediated through BMP4.

Congenital abnormalities provide clinical examples of instances where the role of a BMP or similar factor appears central. Congenital onychodysplasia of the index fingers (COIF) is frequently associated with abnormalities of the terminal phalanges and interphalangeal joints [44]. The nail may be absent, small, or composed of several small nails on the dorsal tip of the affected finger. The bony abnormality varies, with the most marked change being bifurcation of the terminal phalanx on lateral radiographs [45]. However, a bony abnormality is not mandatory in this condition or other conditions with ectopic nail [46]. A normal nail may overlie an abnormal bone on other than the index finger [47]. COIF appears to demonstrate an association between abnormalities of bone and nail, rather than the presence of a strict relationship. It may represent a fault of mesoderm/ectoderm interaction at the stage when these layers are mutually dependent. It has been suggested that a vascular abnormality may provide the common factor between pathology in the two embryonic layers [47]. This would also be consistent with the part played by BMP in vascular development in embryogenesis [48]. If this is the case, it

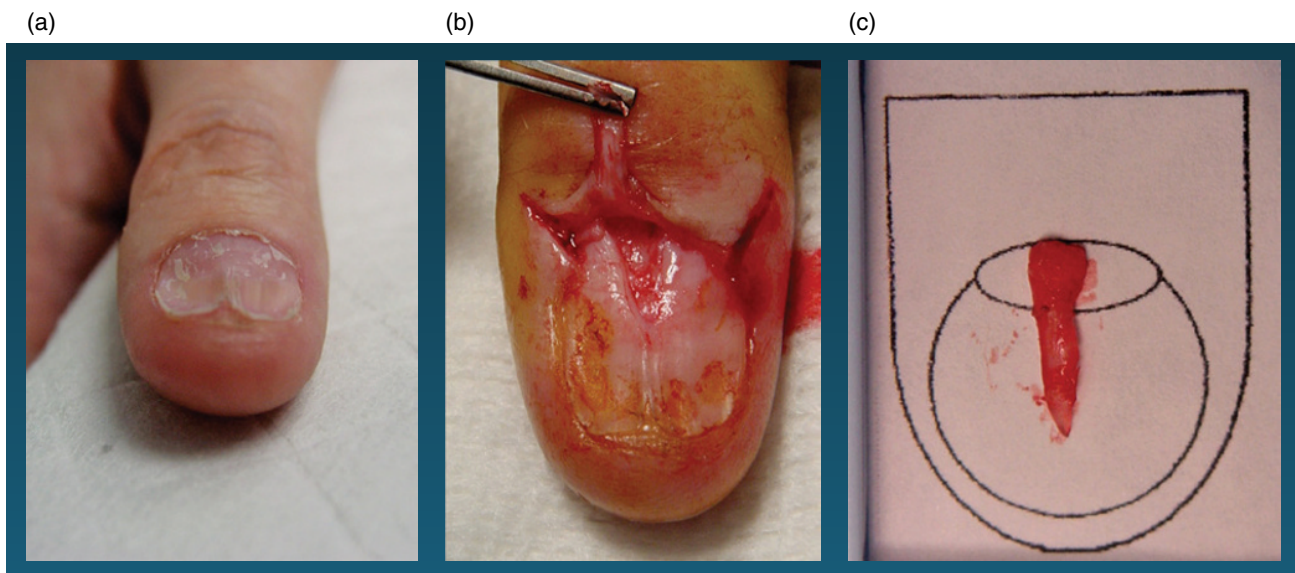
appears likely that any vascular abnormality arises due to a defect of patterned embryogenesis rather than a random event, given that a form of COIF can occur in the great toe of individuals with involved fingers [49].

An interpretation based upon a mutual mesodermal and ectodermal fault would fit with the observation of two cases of congenital anonychia and hypoplastic nails combined with hypoplastic phalanges [50] or brachydactyly [51, 52]. These cases were used as a foil for the suggestion of a mechanism of “bone-dependent nail formation.” It might also be argued in reverse that the bone was dependent upon the nail.

### Histological preparation

When submitting a nail unit specimen for histology, it is important to have some communication with the pathologist to whom you are submitting it, and for he/she in turn to guide the laboratory staff with respect to processing it. Such specimens can be difficult on multiple levels to optimally handle, and many pathologists lack familiarity with this category of specimen. It is helpful to orient it, depending on the type of specimen submitted [51]. For example, in a longitudinal excision, there is inherent orientation when the specimen is maintained in its natural longitudinal axis, and, in fact, the laboratory should be instructed to maintain this upon processing, without sectioning it in the usual transverse style (i.e. avoid “breadloafing”) (Fig. 1.8). In a lateral longitudinal biopsy, one might however wish to indicate to the laboratory to embed on the edge away from the nail fold, as it might contain more helpful information. For more irregular shave and punch specimens and excisions, placing the delicate specimen on a piece of paper or nail template and inking on the paper near the distal end may also allow it to be sectioned, while maintaining some orientation and allowing the technician to know which surface is “up” (Fig. 1.8b). This also provides a mechanism to prevent thinner specimens from curling. Specimens containing nail plate and another containing soft tissue, for example a shave or punch, should be submitted in separate specimen bottles to facilitate processing, embedding, and cutting.

High-quality sections of the nail unit can be difficult to obtain. The nail plate is very hard and tends to shatter and fold in the course of routine histological processing. In biopsies containing nail plate and soft subungual and periungual tissue, the nail plate can be torn from the matrix and other adjacent structures by the microtome. Laboratories unused to nail histology will often have difficulty, may contact the clinician for advice, be slow to provide a result, and produce sections of suboptimal quality. Such problems can be diminished using a range of techniques to soften the nail plate. Some of them may be less practical and too harsh if there are soft tissue attachments requiring histological examination.



**Figure 1.8** Use of nail template for nail biopsy specimen submission. (a) Before biopsy. (b) Longitudinal excision for diagnosis of nail dystrophy. (c) Specimen placed on a nail template prior to submission in formalin to maintain orientation. Courtesy of Monica Lawry.

### Nail softening techniques

#### *Nail alone*

There are a variety of different techniques to soften the nail plate. Some of them are not practical in the modern laboratory where speedy results are expected and the time available for technicians to spend on extra measures may be limited, but they will be discussed for historical perspective. Lewis [3] recommended routine fixation in 10% formalin and processing as usual. That is how most laboratories handle such specimens. Earlier methods employed fixation with potassium bichromate, sodium sulfate, or sodium bisulfite and water. The section is then decalcified with nitric acid and embedded in collodion. Alkiewicz and Pfister [53] recommended softening the nail with thioglycolate or hydrogen peroxide. Nail fragments are kept in 10% potassium thioglycolate at 37°C for 5 days or in 20–30% hydrogen peroxide for 5–6 days. The nail is then fixed by boiling in formalin for 1 min before cutting 10–15 mm sections.

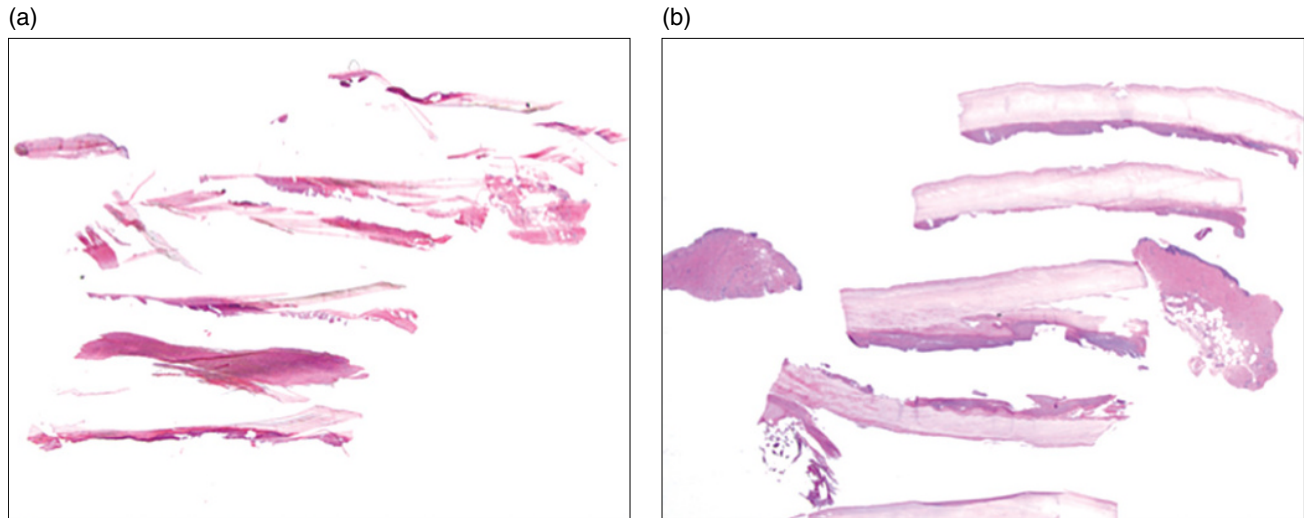
Although softening of nail clippings for histology is not mandatory, it is possible and may be helpful. Suarez et al. [54] suggest soaking the clipping for 2 days in a mix of mercuric chloride, chromic acid, nitric acid, and 95% alcohol. The specimen is then transferred to absolute alcohol, xylene, and successive paraffin mixtures, sectioned at 4 mm, and placed on gelatinized slides. An alternative method, described for preserving histological detail in the nail plate, entails fixation in a mix of 5% trichloroacetic acid and 10% formalin for the initial 24 h [55]. This is followed by a modified polyethylene glycol-pyroxilin embedding method. Ultrathin sections can be provided by embedding the nail in plastic such as 2-hydroxyethyl methacrylate [56].

In current clinical practice, one can use simpler and quicker methods with products containing combinations and dilutions of sodium hydroxide (NaOH), calcium hydroxide (CaOH), and thioglycolate [57–59]. Fabric softener, Mollifex Gurr (ethanol, methanol, acetone, glycerin, 4-hexylresorcinol; VWR International Ltd), and hand/dishwashing soap have all been utilized. A commercial nail-softening agent containing 17% potassium hydroxide (Fig. 1.9), Nail Prep (Stat Lab Medical Products, McKinney, TX, USA), can be used after nail processing, soaking for 15 min. It can also be used in between taking sections by application with a cotton swab. The author's histology team has also used this after an initial 4–6 h in 10% household ammonia prior to processing with excellent results. An over-the-counter depilatory agent, Nair (Church and Dwight, Ewing, NJ, USA) [60], containing CaOH, NaOH, and thioglycolate, can be diluted 2 : 1 with water and used to soak the nail for 2–3 h, and then it is processed as usual after rinsing. Many pathologists who work with nail specimens have their own approaches to handling such specimens depending also on local availability of reagents such as these [61]. Another simple method involves simply soaking the completed paraffin block in water, such as in a water bath in the histology laboratory, for 15 min before cutting to soften the nail plate.

#### *Nail and soft tissue*

In nail biopsies containing epithelium and/or soft tissue, more gentle methods of preparation are necessary, but the 17% potassium hydroxide and depilatory agents methods described above are also acceptable. The specimen can also be soaked in distilled water for a few hours





**Figure 1.9** Use of nail softeners in tissue processing. (a) Nail plate and punch specimens, submitted together (not recommended) and without use of softeners. (b) Same specimens after softening at the time of cutting with 17% potassium hydroxide solution.

before placing in formalin [62]. Twelve hours in 10% formalin followed by 3 days in 3% phenol prior to embedding is reported to achieve good results [63]. After routine fixation and embedding, permanent wave solution (of the type used in hairdressing), thioglycolate, or 10% potassium hydroxide solution can be applied with a cotton swab to the surface of the paraffin block every two or three sections, similar to the methods above for nail plate. Lewin et al. [57] suggested applying 1% aqueous polysorbate 40 to the cut surface of the block for 1 h at 4°C. Preparations containing acids, such as nitric acid used in decalcification solutions, should not be used on epithelium or soft tissue. They may interfere with other testing that one may want on such specimens, including some immunostains depending on intact DNA, such as proliferation markers, and molecular analysis [64, 65].

Sections will sometimes adhere to normal slides, but when there is nail alone the material tends to curl as it dries and may fall off. This means that it may be necessary to use gelatinized or 3-aminopropyltriethoxysilane (APES) slides. Albumin can also be used before placing the sections on the slide to improve adherence. Attention should be paid to avoiding folding of sections. Given the difficulty of obtaining high-quality sections, it may be necessary to cut at additional levels to maximize the chance of obtaining suitable sections.

Routine staining with hematoxylin and eosin is sufficient for most cases. Periodic acid–Schiff (PAS) and Grocott’s silver stain can be used to demonstrate fungi; a blanchophore fluorochromation selectively delineates fungal walls [66]. More recently, Gomori methenamine silver (GMS) stain has been advocated following pretreatment with chromic acid and sodium bisulfite [67]. There has been some recent discussion as to whether PAS or GMS staining is superior for identification of

fungi in the nail, but they are probably equivalent, and PAS is much less labor intensive and less expensive to perform [68, 69]. Some of the more representative material in a nail sample for histology for fungus may be in the crumbling substance on the ventral aspect. This can be examined separately but requires a container such as a paper lens container to prevent dispersal of the material and to avoid problems with preparing sections [56]. Toluidine blue at pH5 allows better visualization of the details of the nail plate [62, 63]. Fontana–Masson stain demonstrates melanin. Hemoglobin is identified using a modified diaminobenzidine reaction [70]. Prussian blue and Perl stains are not helpful in the identification of blood in the nail as they are specific to the hemosiderin product of hemoglobin breakdown caused by macrophages, which does not occur in the nail [53, 64, 65].

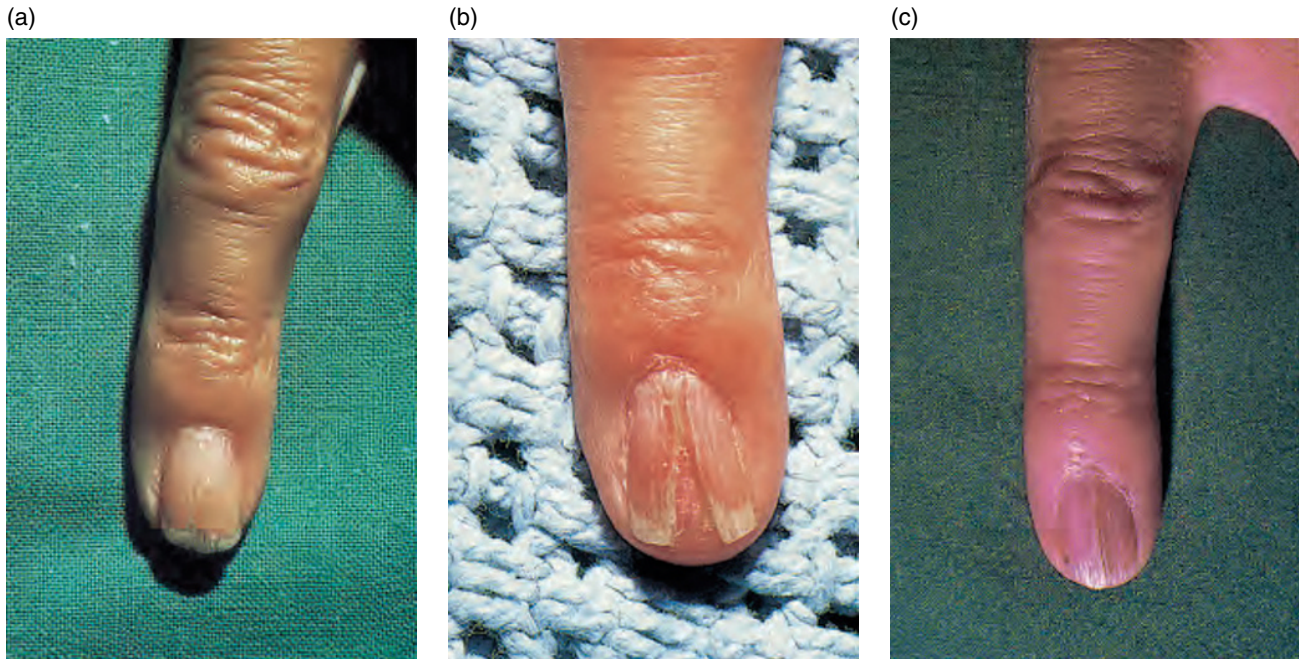
Masson–Goldner’s trichrome stain is very useful to study the keratinization process, and Giemsa stain reveals slight changes in the nail keratin. These are not used widely in routine clinical practice.

Standard techniques for microwave antigen retrieval for immunohistochemistry, routine polymerase chain reaction studies, and terminal deoxynucleotidyl transferase dUTP nick end labeling (TUNEL) assays all appear feasible in combined soft tissue and nail specimens. Molecular analysis is also possible [71].

Polarization microscopy shows the regular arrangement of keratin filaments, and birefringence is said to be absent in disorders of nail formation such as leukonychia.

#### Routine histology

A longitudinal biopsy of the nail unit will yield a specimen with sampling of all the main histological zones of the appendage (Fig. 1.10). The cells of the nail matrix are distinct from the adjacent nail bed distally and the ventral



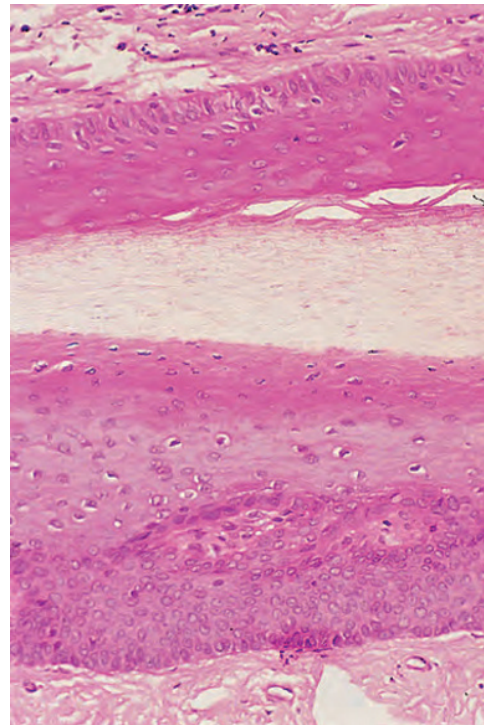
**Figure 1.10** Longitudinal nail biopsy of Zaias. (a) Before biopsy; (b) 5 weeks after; (c) 3 months later.

surface of the nail fold, lying at an angle above. The nail matrix is the thickest area of stratified squamous epithelium in the midline of the nail unit, comparable with the hyponychium. There are longitudinally oriented epithelial ridges (unlike rete ridges) characteristically descending at a slightly oblique angle, their tips pointing distally. Laterally, the matrix ridges are less marked, whereas those of the nail bed and nail folds become prominent.

Unlike the overlying nail fold, but like the nail bed, the matrix has no granular layer (Fig. 1.11). The demarcation between overlying nail fold and matrix is enhanced by the altered morphology of the epithelial ridges. At their junction at the apex of the matrix and origin of the nail, the first matrix epithelial ridge may have a bobbed appearance like a lopped sheep's tail. PAS staining is marked at both the distal and proximal margins of the intermediate matrix (Fig. 1.12). Distally, there is often a step reduction in the epithelial thickness at the transition of the matrix with the nail bed. This represents the edge of the lunula.

Nail is formed from the matrix as cells become larger and paler and eventually the nucleus disintegrates. There is progression with flattening, elongation, and further pallor. Occasionally, retained shrunken or fragmented nuclei persist to be included into the nail plate. Lewis [3] called these "pertinax bodies." They can give an impression of the longitudinal progression of growth in the nail plate (Fig. 1.13).

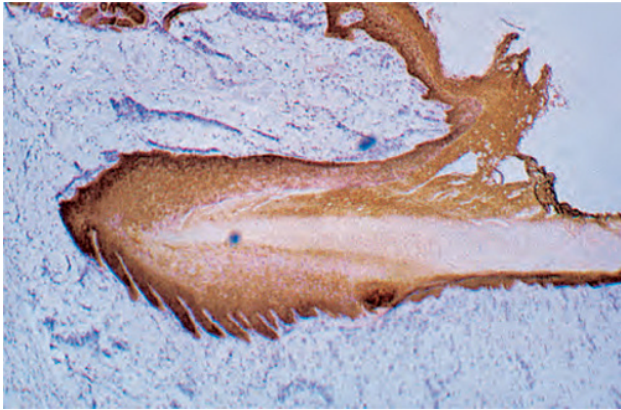
Melanocytes are present in the matrix where they reach a density of up to  $300/\text{mm}^2$  [71–75]. This can also be expressed as the number of melanocytes per linear



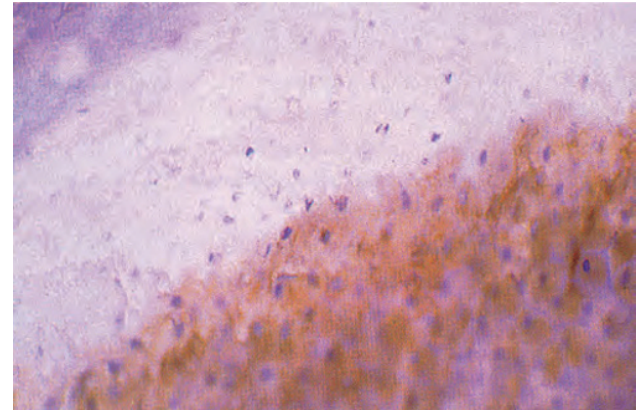
**Figure 1.11** A granular layer is absent from the germinal matrix (lower part) and is variable on the ventral aspect of the proximal nail fold (upper part).

millimeter of matrix epidermis examined (Fig. 1.14). Figures for this are a mean of 7.5, median of 7.7, and range of 4–9 [76] (Table 1.3).



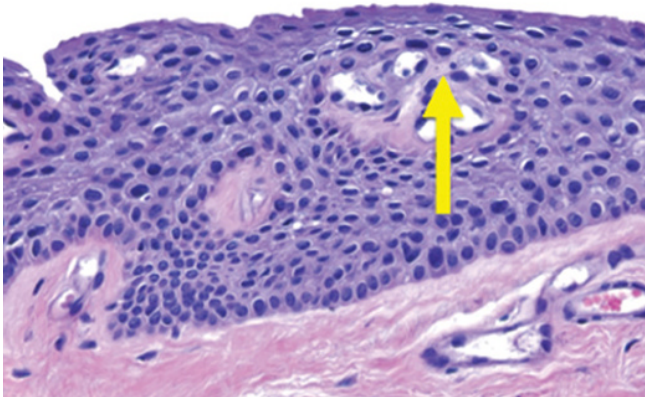


**Figure 1.12** Keratin stain of the nail apparatus delineating the epithelial structures of the matrix and proximal nail fold.

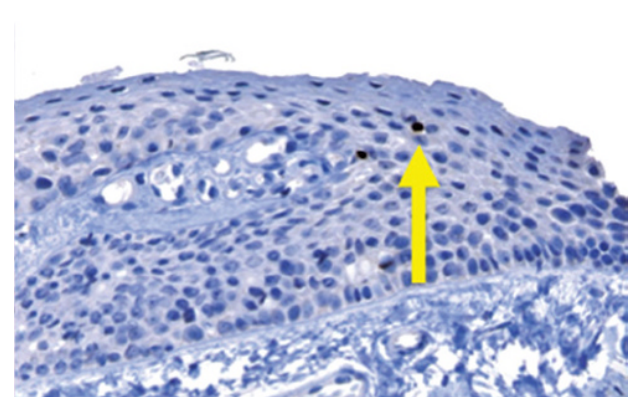


**Figure 1.13** Pertinax bodies can be seen as the nuclear remnants within the nail plate.

(a)



(b)



**Figure 1.14** Normal nail matrix melanocytic density in punch biopsy. (a) Melanocytes in the matrix are usually inconspicuous in routine sections. (b) SOX-10 immunostaining of melanocytes, demonstrating normal density (roughly 4–9 per mm across the matrical epithelium) (arrow).

**Table 1.3** Number of melanocytes found per millimeter of matrix in normal and pathological states.

Pathology	Mean	Median	Range
Invasive melanoma	102	92.5	52–212
In situ melanoma	58.9	51	39–136
Lentigo	15.3	14	5–31
Normal control	7.7	7.5	4–9

Reproduced from Amin [76] with permission from Lippincott, Williams and Wilkins.

Dendritic cells are found in the epibasal layers and are most prominent in the distal matrix [73–75]. This point can be refined in terms of the functional status of the melanocytes. Cameli et al. [19] described melanocytes of the proximal matrix as being in a single compartment of largely dormant cells. Those in the distal matrix are in

two compartments, with both a dormant and functionally differentiated population. Longitudinal melanonychia most commonly arises from pigment contributed to the nail plate by these differentiated distal melanocytes. Cameli et al. also defined a smaller population of nail bed melanocytes, with approximately 25% of the number found in the matrix, and none of these were differentiated in terms of 3,4-dihydroxy-L-phenylalanine (DOPA) staining. This differs from the observations of de Berker et al. [74], who noted that the nail bed lacked melanocyte markers.

The suprabasal location of nail matrix melanocytes can lead to difficulties in the interpretation of histological specimens obtained to exclude atypicality in instances of melanonychia, given that suprabasal scatter of melanocytes is a sign of atypia in normal epidermis. HMB-45, Melan-A, MiTF, and SOX-10 are useful markers of nail matrix melanocytes. S100, while helpful in desmoplastic melanoma at this and other sites with

respect to staining dermal melanocytes, is variable in its ability to stain matrix melanocytes. In spite of these difficulties in interpretation, melanoma is a relatively rare cause of nail unit pigmentation, although it may be necessary to exclude it histologically, particularly in white adults [73, 77, 78].

Melanin in the nail plate is composed of granules derived from matrix melanocytes [9]. Longitudinal melanonychia may be a benign phenomenon, particularly in Afro-Caribbean people: 77% of black people will have a melanonychia by the age of 20 and almost 100% by age 50 [79, 80]. The Japanese also have a high prevalence of longitudinal melanonychia, being present in 10–20% of adults [81]. In a study of 15 benign melanonychia cases in Japanese patients, they were found to arise from an increase in activity and number of DOPA-positive melanocytes in the matrix, not a melanocytic nevus [72]. A survey of fingers and toes of 2457 Chinese patients found none with melanonychia below the age of 20; 0.6% in those between 20 and 29; and 1.7% in those over 50 [82]. A French study of white patients found a 1.4% prevalence in the community and 12.6% prevalence in hospitalized patients [83]. The difference may have in part reflected different clinical sensitivity among community and hospital clinicians. In all studies, where mentioned, the thumb and great toe are the most commonly affected digit. Longitudinal melanonychia in white patients is more sinister; Oropeza [84] stated that a subungual pigmented lesion in this group has a higher chance of being malignant than benign.

There is only a thin layer of dermis dividing the matrix from the terminal phalanx. This has a rich vascular supply (see “Vascular supply”) and an elastin and collagen infrastructure giving attachment to periosteum.

### Electron microscopy

Transmission electron microscopy confirms that, in many respects, matrix epithelium is similar to normal cutaneous epithelium [85–91]. The basal cells contain desmosomes and hemidesmosomes and interdigitate freely. Differentiating cells are rich in ribosomes and polysomes and contain more RNA than equivalent cutaneous epidermal cells. As cell differentiation proceeds towards the nail plate, there is an accumulation of cytoplasmic microfibrils (7.5–10 nm). These fibrils are haphazardly arranged within the cells up to the transitional zone. Beyond this, they become aligned with the axis of nail plate growth.

Membrane-coating granules (Odland bodies) are formed within the differentiating cells. They are discharged onto the cell surface in the transitional zone and have been thought to contribute to the thickness of the plasma membrane. They may also have a role in the firm adherence of the squamous cells within the nail plate, which is a notable characteristic [91]. The glycoprotein characteristics of cell

membrane complexes isolated from nail plate may reflect the constituents of these granules [92].

Mitochondria are degraded during the transitional phase, while RNA-containing ribosomes are evident up to the stage of plasma membrane thickening. Vacuoles containing lipid and other products of cytolysis are seen at the transitional stage. Dorsal matrix cells start to show nuclear shrinkage at this point, whereas the nuclei in the matrix remain intact to a higher level.

Electron microscopy has been used to examine the nail plate in detail in fungal disease [93], alopecia areata [94], connective tissue diseases [95], and psoriasis [96].

## Regional anatomy

### Nail matrix and lunula

For simplicity, the nail matrix (syn. intermediate matrix) will be defined as the most proximal region of the nail bed extending to the lunula. This is commonly considered to be the source of the bulk of the nail plate, although further contributions may come from other parts of the nail unit (such as the nail bed). Contrast with these other regions helps to characterize the matrix.

The matrix is vulnerable to surgical and accidental trauma; a longitudinal biopsy of greater than 3 mm width is likely to leave a permanent dystrophy [97] (Fig. 1.10). Once matrix damage has occurred, it is difficult to effectively repair it [98–100]. This accounts for the relatively small amount of histological information on normal nail matrix.

It is possible to make distinctions between distal and proximal matrix on functional grounds, given that 81% of cell numbers in the nail plate are provided by the proximal 50% of the nail matrix [101] and surgery to distal matrix is less likely to cause scarring than more proximal surgery. Clinically, the matrix is synonymous with the lunula, or half moon, which can be seen through the nail emerging from beneath the proximal nail fold as a pale convex structure. This is most prominent on the thumb, becoming less prominent in a gradient towards the little finger. It is rarely seen on the toes. The absence of a clinically identifiable lunula may mean that the vascular tone of the nail bed and matrix has obscured it or that the proximal nail fold extends so far along the nail plate that it lies over the entire matrix.

High-resolution magnetic resonance imaging identifies the matrix and dermal zones beneath [102, 103]. Drapé et al. [103] described a zone beneath the distal matrix where there is loose connective tissue and a dense microvascular network. It may be the presence of this network that accounts for the variable sign of red lunulae in some systemic conditions [104, 105]. However, the histological observations of Lewin [106] suggested that there is diminished vascularity and increased dermal



### Box 1.1 Possible causes for the pale appearance of the lunula

- The surface of the nail is smoother and more shiny proximally.
- The thicker epidermis of the lunula obscures the underlying vasculature.
- The nail attachment at the lunula is less firm, allowing greater refraction and reflection at the nail–soft tissue interface.
- The underlying dermis has fewer capillaries in it.
- The underlying dermis is of looser texture.
- The matrix epithelium in the lunula has more nuclei than the nail bed, making it appear parakeratotic with an altered color.

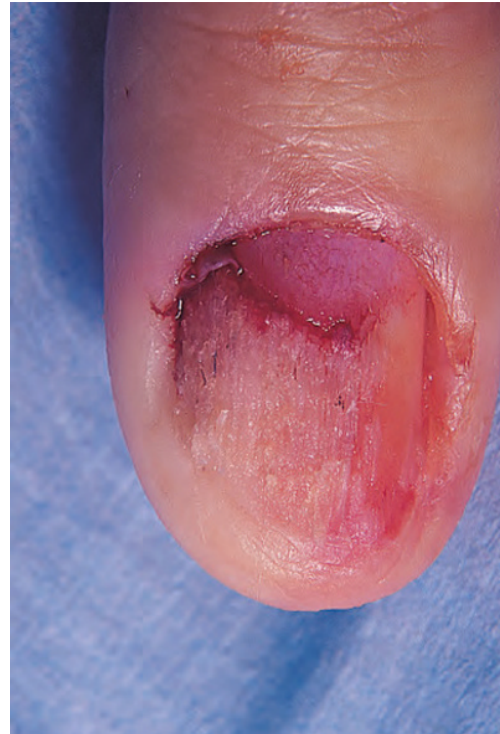collagen beneath the matrix contributing to the pallor, which helps identify the area. This has been confirmed in a more recent study utilizing injection of gelatinized Indian ink into amputation specimens [107]. The close association between the nail matrix and joint apparatus results in magnetic resonance imaging changes in the tendon sheath and matrix coincidentally [108] and may demonstrate changes in the matrix prior to the onset of any clinical nail disease [109].

The thinner epidermis of the nail bed may account for the contrast between the white and pink appearance of the lunula and bed, respectively [110]. Many suggestions have been made to account for the appearance of the lunula [75, 85, 106, 111] (Box 1.1).

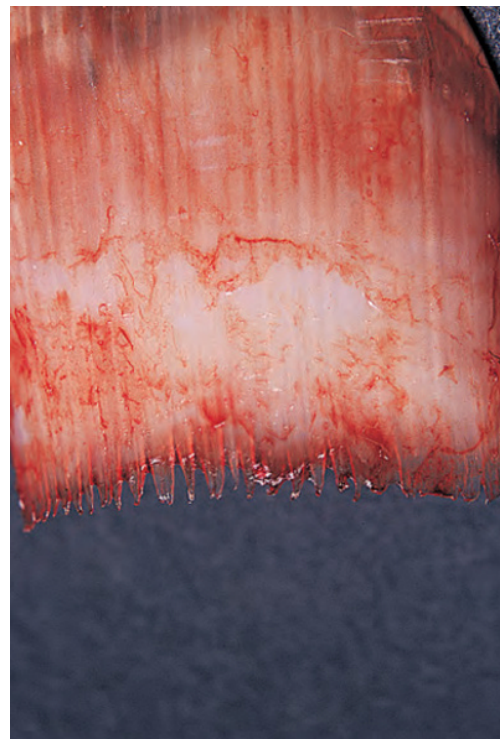
Macroscopically, the distal margin of the matrix is convex and is easily distinguished from the contiguous nail bed once the nail is removed, even if the difference is not clear prior to avulsion. The nail bed is a more deep red and has surface corrugations absent from the matrix. At the proximal margin of the matrix, the contour of the lunula is repeated. At the lateral apices, a subtle ligamentous attachment has been described, arising as a dorsal expansion of the lateral ligament of the distal interphalangeal joint [112]. Lack of balance between the symmetrical tension on these attachments may explain some forms of acquired and congenital malalignment [113].

### Nail bed and hyponychium

The nail bed extends from the distal margin of the lunula to the hyponychium. It is also called the ventral matrix, depending on whether or not you believe that it contributes to the substance of the nail plate (see “Nail growth”). Avulsion of the nail plate reveals a pattern of longitudinal epidermal ridges stretching to the lunula (Fig. 1.15). On the underside of the nail plate is a complementary set of ridges, which has led to the description of the nail being led up the nail bed as if on rails (Fig. 1.16). The small vessels



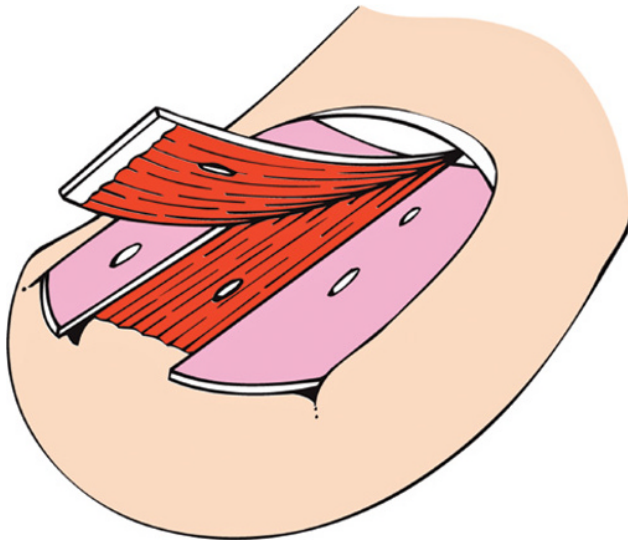
**Figure 1.15** The epidermis of the nail bed has longitudinal ridges visible after nail avulsion.



**Figure 1.16** The undersurface of the nail plate shows longitudinal ridging that matches that seen on the nail bed. This pattern is lost at the margin of the lunula, where the nail is in continuity with the matrix from which it arises.

of the nail bed are orientated in the same axis. This can be demonstrated by using corrosion casting from cadaver digits [114] and is clinically manifested by splinter hemorrhages (Figs 1.17, 1.18), where heme is deposited on the undersurface of the nail plate and grows out with it. The free edge of a nail loses the ridges, suggesting that they are softer than the main nail plate structure. The nail bed also loses these ridges shortly after loss of the overlying nail. It is likely that the ridges are generated at the margin of the lunula on the ventral surface of the nail to be imprinted upon the nail bed.

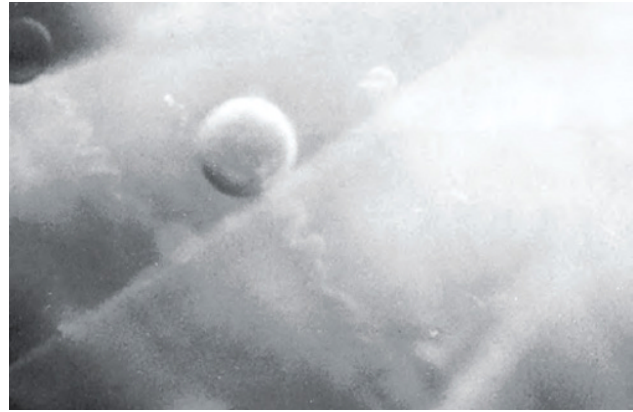The epidermis of the nail bed is thin over the bulk of its territory. It becomes thicker at the nail folds, where it develops rete ridges. It has no granular layer except in disease states. The dermis is sparse, with little fat, has firm collagenous adherence to the underlying periosteum, and



**Figure 1.17** The appearance of splinter hemorrhages. Heme from longitudinal nail bed vessels is deposited on the underside of the nail plate. This grows out in the shape of a splinter.



**Figure 1.18** The undersurface of the nail has dark-stained blood in the longitudinal grooves corresponding to splinter hemorrhages.



**Figure 1.19** Sweat pores in the distal nail bed. Reproduced from Maricq et al. [111] with permission from Elsevier.

has no sebaceous or follicular appendages. Sweat ducts can be seen at the distal margin of the nail bed using *in vivo* magnification (Fig. 1.19) [111].

The hyponychium lies between the distal ridge and the nail plate and represents a space as much as a surface. Perrin [115] has described an analog of the hair follicle isthmus at the junction of the hyponychium and nail bed, referred to as the nail isthmus, leading on to the nail infundibulum, which he proposed would replace the term hyponychium. The distal ridge (see “Factors in embryogenesis”) is seen from the 10th week of gestation onwards. The hyponychium and onychocorneal band may be the focus or origin of subungual hyperkeratosis in some diseases such as pityriasis rubra pilaris (see Table 1.8) or pachyonychia congenita.

The hyponychium can be extended into a pathological structure vulnerable to bleeding and pain with minimal trauma or nail clipping known as pterygium inversum unguis [116]. There is tough, fibrotic tissue tethering the free edge of the nail plate to the underlying soft structures. It is found in both congenital [117] and acquired forms [118]. The proposed etiology and patterns are various. Patterson [118] proposed that it was a combination of a genetic predisposition and microvascular ischemia.

The hyponychium and overhanging free nail provide a crevice which is a reservoir for microbes, relevant in surgery and the dissemination of infection. After 10 min of scrubbing the fingers with povidone-iodine, nail clippings were cultured for bacteria, yeasts, and molds [119]. In 19 out of 20 patients, *Staphylococcus epidermidis* was isolated, seven patients had an additional bacterium, eight had molds, and three had yeasts. These findings could have significance for both surgeons and patients. However, in a randomized trial of chlorhexidine scrub used with or without a nail brush, the nail brush did statistically diminish the number of colony-forming units obtained from the scrubbed hand [120].