

Reinhard Bittner · Ferdinand Köckerling  
Robert J. Fitzgibbons, Jr. · Karl A. LeBlanc  
Sumeet K. Mittal · Pradeep Chowbey *Editors*

# Laparo-endoscopic Hernia Surgery

Evidence Based  
Clinical Practice

# Laparo-endoscopic Hernia Surgery

Reinhard Bittner  
Ferdinand Köckerling  
Robert J. Fitzgibbons, Jr.  
Karl A. LeBlanc  
Sumeet K. Mittal  
Pradeep Chowbey  
*Editors*

# Laparo-endoscopic Hernia Surgery

Evidence Based Clinical Practice

*Editors*

**Reinhard Bittner**

Em. Director of Surgical Department  
Marienhospital Stuttgart  
Stuttgart, Germany

**Robert J. Fitzgibbons, Jr.**

Department of General Surgery  
Creighton University School of  
Medicine  
Omaha, Nebraska, USA

**Sumeet K. Mittal**

Norton Thoracic Institute, Dignity  
Health  
Creighton University School of  
Medicine (Phoenix campus)  
Phoenix, Arizona, USA

**Ferdinand Köckerling**

Academic Teaching Hospital of Charité  
Medical School, Vivantes Hospital  
Department of Surgery and Center for  
Minimally Invasive Surgery  
Berlin, Germany

**Karl A. LeBlanc**

Louisiana State University School of  
Medicine, Department of Surgery  
Our Lady of the Lake Physician Group,  
Department of Surgery  
Baton Rouge, Louisiana, USA

**Pradeep Chowbey**

Minimal Access, Metabolic  
and Bariatric Surgery  
Max Super Specialty Hospital Saket  
New Delhi, India

ISBN 978-3-662-55491-3      ISBN 978-3-662-55493-7 (eBook)  
<https://doi.org/10.1007/978-3-662-55493-7>

Library of Congress Control Number: 2018938554

© Springer-Verlag GmbH Germany, part of Springer Nature 2018

This work is subject to copyright. All rights are reserved by the Publisher, whether the whole or part of the material is concerned, specifically the rights of translation, reprinting, reuse of illustrations, recitation, broadcasting, reproduction on microfilms or in any other physical way, and transmission or information storage and retrieval, electronic adaptation, computer software, or by similar or dissimilar methodology now known or hereafter developed. The use of general descriptive names, registered names, trademarks, service marks, etc. in this publication does not imply, even in the absence of a specific statement, that such names are exempt from the relevant protective laws and regulations and therefore free for general use.

The publisher, the authors and the editors are safe to assume that the advice and information in this book are believed to be true and accurate at the date of publication. Neither the publisher nor the authors or the editors give a warranty, express or implied, with respect to the material contained herein or for any errors or omissions that may have been made. The publisher remains neutral with regard to jurisdictional claims in published maps and institutional affiliations.

Printed on acid-free paper

This Springer imprint is published by the registered company Springer-Verlag GmbH, DE part of Springer Nature  
The registered company address is: Heidelberger Platz 3, 14197 Berlin, Germany

## Preface

---

When asked by Dr. Bittner to join him as a coeditor of this work, I couldn't help but think "why do we need another book devoted to hernia repairs." But then he explained the unique perspective he intended as the focus of this new work. He felt there was a need for a book about hernia repair which was strictly limited to endoscopic surgery and was to incorporate guidelines endorsed by important surgical societies derived from critical analysis of appropriate literature. Certainly, traditional aspects of a surgical textbook were to be included in each chapter such as historical perspective, anatomy, incidence, operative details, perioperative care, and so on, but they are presented from an evidence-based perspective and not just the opinion of the author. I quickly came to the realization that he was right. I respectfully accepted the invitation and was honored to be asked.

Now after several years of work, the book has come to fruition. A quick perusal of

the table of contents reveals an author list which can be considered a "who's who" in the field of endoscopic hernia surgery. Each chapter is well written and a pleasure to read. I believe the original goals of applying evidence-based science to the clinical practice of endoscopic hernia surgery have been met and even superseded.

Finally, it is important for the reader to recognize that the driving force behind this work was Dr. Reinhard Bittner. From the original conception to the actual production, it was he alone who kept the work going with endless letters, emails, phone calls and face-to-face conversations with authors encouraging them to complete their assignments. We all know that, in this day and age with so many other priorities, this can be a daunting task. Congratulations to Dr. Bittner because without him this work would have never been completed. I can't thank him enough for the small part he allowed me to contribute to the project.

**Robert J. Fitzgibbons, Jr., MD, FACS**  
Omaha, NE 68131, USA

# Preface

---

In the era of digital media, does it still make sense to write a surgical textbook? The digital media provide the spread of the newest results of experimental and clinical research within seconds to every interested surgeon around the world. However, when using the digital media alone in order to study and to learn the well-proven standards in diagnostics, operative techniques and aftercare, especially in the new field of surgery, the laparo-endoscopic hernia repair, it is almost impossible to get the necessary information in a timely manner. On the other hand, while writing a book takes about 2–3 years, however, for the surgeon to look for the essentials in his daily work, it requires only a very short time to be fully informed. Therefore, despite currently overwhelming digitization, the printed media are still indispensable.

But, why write another book on hernia surgery as there are already many? This book is mainly devoted to laparo-endoscopic hernia surgery, but covers some particularly noteworthy features: (1) This textbook provides not only a comprehensive, state-of-the-art review of the total field of laparo-endoscopic surgery of inguinal and ventral hernia but also of hiatal hernia repair. Furthermore, recently achieved insights into the surgical anatomy of the groin and the abdominal wall, in current operative techniques and mesh technology, are described in detail. (2) The uniqueness

of this book, however, is that not only the good clinical practice is described but also the scientific background of daily routine work is quoted in terms of evidence-based medicine (Oxford classification of levels of evidence). (3) This book is written by an international group (International Endohernia Society (IEHS)) of highly experienced laparo-endoscopic surgeons from three continents inclusive of former presidents and meeting presidents of the German Hernia Society (V. Schumpelick, R. Bittner, F. Köckerling, W. Reinhold, D. Weyhe, U. Dietz, A. Koch), the European Hernia Society (V. Schumpelick, R. H. Fortelny, S. Morales-Conde), the Americas Hernia Society (R. Fitzgibbons, K. A. LeBlanc, M. Arregui, B. Ramshaw), and the Asia-Pacific Hernia Society (P. Chowbey, D. Lomanto, A. Sharma).

In summary, hernia surgery affects about 20 million patients per year worldwide. Due to this huge number of patients, the quality of performances in diagnostics and treatment has an impact not only on the individual patient but also on the cost for the health care systems of the respective countries. Therefore, it is of paramount importance to find the best treatment options. This applies in particular to this new field of surgery, the laparo-endoscopic hernia repair. This book may be an indispensable aid to any surgeon in his daily decision-making process to do the best for his patient.

**Reinhard Bittner**

Stuttgart, BW, Germany

**Ferdinand Köckerling**

Berlin, Germany

## Preface

---

Every surgeon strives for excellence to deliver best clinical outcomes. Surgery is the field of science which is in the process of continuous evolution and has gained momentum in the past few decades. Today, when we sit in a time machine, grab the control gears in our hand, and accelerate on the road of the twenty-first century, the pursuit of herniology has taken a giant leap forward towards advanced surgical techniques that constitute minimal access surgery (MAS). Laparoscopic surgery has emerged as a cost-effective and patient-friendly technique for the repair of hernias.

The surgical doctrine of conventional hernia surgeries using large incisions, inconvenience of adjusting lights in the operation theaters, using magnifying loupes has revolutionized into small ports, magnified vision through laparoscopes, increased dexterity, easy access, shorter hospital stay, and faster recovery for the patients with minimal access surgeries.

Encountering the challenging situations on the operation table has increased the surgical expertise in laparoscopic hernia repairs. These academic records and literature are a medium to equip the young and upcoming surgeons to face and deal with the complex situations and to cater the needs of patients.

It gives me immense pleasure and honor to be a part of this academic venture. This book is an amalgamation of dynamic experiences and insights to laparoscopic hernia repairs. The team approach for the management of hernias with evidence-based clinical practice has been thoroughly discussed. The landmark of this published work is its comprehensive chapters which have been compiled in a precise way for each type of hernia for easy understanding and clarity. Clinical tips and surgical experience contributed by eminent herniologists across the globe are highly commendable. I would like to once again compliment the authors and the team for taking the opportunity under one platform to share their experiences and opening the new gateways for future laparoscopic surgeons.

Tracking the wheels of surgical journey from old standard approaches to modern and current approaches, the change is never ending. These changes have the potential to unfold newer understanding, newer approaches, and implementation of new prosthetic materials in the field of herniology.

I would just like to conclude that safety is never enough in the ever-evolving world. This manuscript is an attempt to increase the level of safety for the present generation of surgeons engaged in laparoscopic hernia repairs.

**Pradeep Chowbey**

Saket, New Delhi, India

# Contents

---

## I Inguinal Hernia

1	<b>Clinical Anatomy of the Groin: Posterior Laparoscopic Approach</b> .....	5
	<i>Reinhard Bittner, David Chen, and Wolfgang Reinpold</i>	
2	<b>Diagnostics of Inguinal Hernias</b> .....	21
	<i>Baukje Van Den Heuvel</i>	
3	<b>Classification of Inguinal Hernia</b> .....	27
	<i>Volker Schumpelick</i>	
4	<b>Chain of Events Leading to the Development of the Current Techniques of Laparoscopic Inguinal Hernia Repair: The Time Was Ripe</b> .....	31
	<i>Maurice Arregui</i>	
5	<b>Indication for Surgery: Open or Laparoendoscopic Techniques in Groin Hernias</b> .....	37
	<i>Jan F. Kukleta, Ferdinand Köckerling, and George Ferzli</i>	
6	<b>Patient Selection for Laparoendoscopic Inguinal Hernia Repair</b> .....	43
	<i>Mazen Iskandar and George Ferzli</i>	
7	<b>Watchful Waiting as a Treatment Strategy in Patients with Asymptomatic Inguinal Hernia</b> .....	51
	<i>Brian Biggerstaff, Shreya Shetty, and Robert J. Fitzgibbons, Jr.</i>	
8	<b>Perioperative Management of Laparoscopic Inguinal Hernia Repair</b> .....	59
	<i>Henning Niebuhr, Bernd Stechemesser, and Reinhard Bittner</i>	
9	<b>Transabdominal Preperitoneal Patch Plasty (TAPP): Standard Technique and Specific Risks</b> .....	79
	<i>Reinhard Bittner, Jan F. Kukleta, and David Chen</i>	
10	<b>TAPP: Complications, Prevention, Education, and Preferences</b> .....	101
	<i>Reinhard Bittner, Jan F. Kukleta, and David Chen</i>	
11	<b>Technique Total Extraperitoneal Patch Plasty (TEP): Standard Technique and Specific Risks</b> .....	119
	<i>Ferdinand Köckerling, Pradeep Chowbey, Davide Lomanto, and Maurice Arregui</i>	
12	<b>Technique Total Extraperitoneal Patch Plasty (TEP): Complications, Prevention, Education, and Preferences</b> .....	141
	<i>Ferdinand Köckerling, Pradeep Chowbey, Davide Lomanto, and Maurice Arregui</i>	



13	<b>Comparison TAPP vs. TEP: Which Technique Is Better?</b> .....	151
	<i>Virinder Kumar Bansal, Asuri Krishna, Nalinikant Ghosh, Reinhard Bittner, and Mahesh C. Misra</i>	
14	<b>Complex Inguinal Hernias</b> .....	171
	<i>Mazen Iskandar and George Ferzli</i>	
15	<b>Mesh Technology at Inguinal Hernia Repair</b> .....	183
	<i>Ferdinand Köckerling, Dirk Weyhe, Rene H. Fortelny, and Bruce Ramshaw</i>	
16	<b>Aftercare and Recovery in Laparoscopic Inguinal Hernia Surgery</b> .....	195
	<i>Ralf M. Wilke, Andrew de Beaux, and Juliane Bingener-Casey</i>	
17	<b>Chronic Postoperative Inguinal Pain (CPIP)</b> .....	201
	<i>Wolfgang Reinhold and David Chen</i>	
18	<b>Costs</b> .....	215
	<i>G. H. van Ramshorst and Reinhard Bittner</i>	
19	<b>Sportsmen Hernia</b> .....	225
	<i>Salvador Morales-Conde, Moshe Dudai, and Andreas Koch</i>	
20	<b>Comparison to Open Techniques</b> .....	235
	<i>Baukje Van Den Heuvel, Robert J. Fitzgibbons, Jr., and Reinhard Bittner</i>	
21	<b>Reduced Port in Laparoendoscopic Inguinal Hernia Repair</b> .....	243
	<i>Davide Lomanto, Rajesh Khullar, Thomas Carus, and Sujith Wijerathne</i>	

## II Ventral and Incisional Hernias

22	<b>Anatomy of the Abdominal Wall: What Is Important for Laparoscopic Surgery?</b> .....	253
	<i>Romed Hörmann, Helga Fritsch, and Karl A. LeBlanc</i>	
23	<b>Ventral and Incisional Hernias: Differences and Indications for Laparoscopic Surgery</b> .....	261
	<i>Ferdinand Köckerling and Anil Sharma</i>	
24	<b>Pathophysiology and Diagnostics of Ventral and Incisional Hernias</b> .....	267
	<i>Rudolf Schrittwieser</i>	
25	<b>Classification of Ventral and Incisional Hernias</b> .....	273
	<i>Ulrich A. Dietz and Juliane Bingener-Casey</i>	
26	<b>Perioperative Management of Ventral and Incisional Hernias</b> .....	283
	<i>Rudolf Schrittwieser</i>	

27	<b>Standard Technique Laparoscopic Repair of Ventral and Incisional Hernia</b> .....	287
	<i>Karl A. LeBlanc, Anil Sharma, and Jan F. Kukleta</i>	
28	<b>Aftercare and Pain Management</b> .....	305
	<i>Juliane Bingener-Casey and Ralf M. Wilke</i>	
29	<b>Complications, Pitfalls and Prevention of Complications of Laparoscopic Incisional and Ventral Hernia Repair and Comparison to Open Repair</b> .....	311
	<i>Asuri Krishna, Virinder Kumar Bansal, and Mahesh C. Misra</i>	
30	<b>Education and Learning Curve in Ventral Hernia Repair</b> .....	333
	<i>Davide Lomanto and Sujith Wijerathne</i>	
31	<b>Complex Ventral and Incisional Hernias</b> .....	339
	<i>Ferdinand Köckerling, Davide Lomanto, and Pradeep Chowbey</i>	
32	<b>Ventral and Incisional Hernias Mesh Technology</b> .....	349
	<i>Ferdinand Köckerling and Bruce Ramshaw</i>	
33	<b>Incisional and Abdominal Wall Hernia Repair with Minimally Invasive Extraperitoneal Synthetic Mesh Implantation Using MILOS Technique (Mini and Less Open Sublay Surgery)</b> .....	357
	<i>Wolfgang Reinpold</i>	
34	<b>Endoscopic Mini/Less Open Sublay (EMIOS) Technique: A Variation of the MILOS Operation in the Therapeutic Spectrum of Primary and Secondary Ventral Hernias</b> .....	365
	<i>Reinhard Bittner and Jochen Schwarz</i>	
35	<b>Lumbar and Other Unusual Hernias</b> .....	373
	<i>Karl A. LeBlanc</i>	
36	<b>Single-Port Technique and Robotics in Ventral Hernia Repair</b> .....	381
	<i>Davide Lomanto and Sujith Wijerathne</i>	
<b>III</b>	<b>Hiatal Hernias</b>	
37	<b>General Issues of Hiatal Hernias</b> .....	387
	<i>Burkhard H. A. von Rahden, Sumeet K. Mittal, and Ellen Morrow</i>	
38	<b>Techniques of Hiatal Hernia Repair</b> .....	393
	<i>Beat Müller-Stich, Philip C. Müller, Rudolph Pointner, Stavros A. Antoniou, Burkhard H. A. von Rahden, and Sumeet K. Mittal</i>	
39	<b>Mesh Technology in Hiatal Hernia</b> .....	409
	<i>Ferdinand Köckerling, Beat Müller-Stich, and Bruce Ramshaw</i>	

40	<b>Complications of Hiatal Hernia Repair</b> .....	415
	<i>Jelmer E. Oor, Ferdinand Köckerling, Rajesh Khullar, and Eric J. Hazebroek</i>	
41	<b>Complex Hiatal Hernias</b> .....	421
	<i>Dirk Weyhe and Pradeep Chowbey</i>	
42	<b>Hiatal Hernia Repair in Difficult Pathologic-Anatomic Situations at the Hiatus</b> .....	433
	<i>Pradeep Chowbey, Alice Chung, and Ellen Morrow</i>	
43	<b>Comparisons of Methods at Hiatal Hernia Repair</b> .....	439
	<i>Sumeet K. Mittal</i>	
44	<b>New Technologies in Hiatal Hernia Repair: Robotics, Single Port</b> .....	447
	<i>Davide Lomanto, Hrishikesh P. Salgaonkar, and Sujith Wijerathne</i>	
45	<b>Education and Learning in Hiatal Hernia Repair</b> .....	457
	<i>Davide Lomanto and Hrishikesh P. Salgaonkar</i>	
46	<b>Anesthesiologic Aspects of Laparoscopic Hernia Repair</b> .....	465
	<i>Claudia Hafner-Chvojka and Wilfried Junginger</i>	
	<b>Supplementary Information</b>	
	Index .....	477

## Contributors

---

### Stavros A. Antoniou

Department of General Surgery  
University Hospital of Heraklion  
Heraklion, 71 500, Greece  
[stavros.antoniou@hotmail.com](mailto:stavros.antoniou@hotmail.com)

### Maurice Arregui

Department of Surgery  
St. Vincent Hospital  
Indianapolis, IN, USA  
[mauricearregui@me.com](mailto:mauricearregui@me.com)  
[arregui@ameritech.net](mailto:arregui@ameritech.net)

### Virinder Kumar Bansal

Department of Surgical Disciplines  
All India Institute of Medical Sciences  
Delhi, New Delhi 110029, India  
[drvkbansal@gmail.com](mailto:drvkbansal@gmail.com)

### Brian Biggerstaff

Department of Surgery  
Creighton University Medical Center  
601 N 30th Street, Suite 3700  
Omaha, NE68114, USA  
[BrianBiggerstaff@creighton.edu](mailto:BrianBiggerstaff@creighton.edu)

### Juliane Bingener-Casey

Department of Surgery  
Mayo Clinic College of Medicine and Science  
Rochester, MN, USA  
[bingenercasey.juliane@mayo.edu](mailto:bingenercasey.juliane@mayo.edu)

### Reinhard Bittner

Em. Director of Surgical Department  
Marienhospital Stuttgart  
Stuttgart, Germany  
[bittnerfamilie@web.de](mailto:bittnerfamilie@web.de)

### Thomas Carus

Klinik für Allgemein-, Visceral- und Gefäßchirurgie  
Asklepios Westklinikum Hamburg  
Suurheid, Hamburg, Deutschland  
[Thomas.Carus@Klinikum-Bremen-Ost.de](mailto:Thomas.Carus@Klinikum-Bremen-Ost.de)

### David Chen

Lichtenstein Amid Hernia Clinic at UCLA  
Section of Minimally Invasive Surgery  
UCLA Division of General Surgery  
Santa Monica, CA, USA  
[DCChen@mednet.ucla.edu](mailto:DCChen@mednet.ucla.edu)

### Pradeep Chowbey

Minimal Access, Metabolic and Bariatric Surgery  
Max Super Specialty Hospital Saket  
Delhi, New Delhi, India  
[pradeepchowbey@gmail.com](mailto:pradeepchowbey@gmail.com)

### Alice Chung

Department of Surgery  
University of Utah  
Salt Lake City, UT, USA  
[alice.yuo@gmail.com](mailto:alice.yuo@gmail.com)

### Andrew de Beaux

Royal Infirmary of Edinburgh  
Edinburgh, UK  
[adebeaux@doctors.org.uk](mailto:adebeaux@doctors.org.uk)

### Ulrich A. Dietz

Department of Surgery  
Kantonsspital Olten  
Baselstrasse 150, Olten, Solothurn  
CH-4600, Switzerland  
[ulrich.dietz@spital.so.ch](mailto:ulrich.dietz@spital.so.ch)  
[dietz\\_u@chirurgie.uni-wuerzburg.de](mailto:dietz_u@chirurgie.uni-wuerzburg.de)

### Moshe Dudai

Surgery, Hernia-Excellence  
Ramat Aviv Medical Center  
Tel Aviv 69101, Israel  
[moshe.dudai@gmail.com](mailto:moshe.dudai@gmail.com)

### George Ferzli

Surgery, NYU Lutheran Medical Center  
Brooklyn, NY, USA  
[doctorferzli@gmail.com](mailto:doctorferzli@gmail.com)

### Robert J. Fitzgibbons, Jr.

Department of Surgery  
Creighton University Medical Center  
Omaha, NE, USA  
[fitzjr@creighton.edu](mailto:fitzjr@creighton.edu)

### Rene H. Fortelny

General, Visceral and Oncological Surgery  
Wilhelminenspital  
Vienna, Austria  
[rene.fortelny@wienkav.at](mailto:rene.fortelny@wienkav.at)

### **Helga Fritsch**

Anatomy, Histology and Embryology  
Division of Clinical and Functional Anatomy/  
Medical University of Innsbruck  
Innsbruck, Austria  
[helga.fritsch@i-med.ac.at](mailto:helga.fritsch@i-med.ac.at)

### **Nalinikant Ghosh**

Department of Surgical Disciplines  
All India Institute of Medical Sciences  
New Delhi, Delhi, India  
[ghoshnalinikanta@gmail.com](mailto:ghoshnalinikanta@gmail.com)

### **Claudia Hafner-Chvojka**

Klinik für Anästhesiologie und operative  
Intensivmedizin, Schmerztherapie  
Marienhospital Stuttgart  
Stuttgart 70199, Germany  
[claudia.hafner@vinzenz.de](mailto:claudia.hafner@vinzenz.de)

### **Eric J. Hazebroek**

Department of Surgery  
St. Antonius Hospital  
Nieuwegein, The Netherlands  
[ehazebroek@rijnstate.nl](mailto:ehazebroek@rijnstate.nl)

### **Romed Hörmann**

Anatomy, Histology and Embryology  
Division of Clinical and Functional Anatomy/  
Medical University of Innsbruck  
Innsbruck, Austria  
[romed.hoermann@i-med.ac.at](mailto:romed.hoermann@i-med.ac.at)

### **Mazen Iskandar**

Surgery, Mount Sinai Beth Israel  
New York, NY 10003, USA  
[MazenElia.iskandar@mountsinai.org](mailto:MazenElia.iskandar@mountsinai.org)

### **Wilfried Junginger**

Zollernstrasse 5  
Tübingen 72074, Germany  
[wilfried.junginger@web.de](mailto:wilfried.junginger@web.de)

### **Rajesh Khullar**

Max Institute of Minimal Access,  
Metabolic & Bariatric Surgery  
Max Super Speciality Hospital  
Saket, New Delhi, India  
[rajesh.khullar@maxhealthcare.com](mailto:rajesh.khullar@maxhealthcare.com)

### **Andreas Koch**

Day Surgery and Hernia Center  
Gerhart-Hauptmann-Str.15  
Cottbus 03042, Germany  
[akchirurg@aol.com](mailto:akchirurg@aol.com)

### **Ferdinand Köckerling**

Department of General Surgery and  
Center for Minimally Invasive Surgery  
Vivantes Hospital Spandau  
Berlin, Germany  
[ferdinand.koeckerling@vivantes.de](mailto:ferdinand.koeckerling@vivantes.de)

### **Asuri Krishna**

Department of Surgical Disciplines  
All India Institute of Medical Sciences  
Delhi, New Delhi 110029, India  
[dr.asurikrishna@gmail.com](mailto:dr.asurikrishna@gmail.com)

### **Jan F. Kukleta**

Klinik Im Park Zurich (Hirslanden Group)  
Visceral Surgery, NetworkHernia  
Zurich Switzerland  
[jfkukleta@bluewin.ch](mailto:jfkukleta@bluewin.ch)

### **Karl A. LeBlanc**

Surgery, Our Lady of the Lake Physician Group  
and Louisiana State University School of  
Medicine, Baton Rouge, LA, USA  
[Karl.LeBlanc@ololrhc.com](mailto:Karl.LeBlanc@ololrhc.com)

### **Davide Lomanto**

Minimally Invasive Surgical Centre  
Department of Surgery  
National University Hospital  
Singapore 119074, Singapore  
[surdl@nus.edu.sg](mailto:surdl@nus.edu.sg)

### **Mahesh C. Misra**

General and Minimally Invasive Surgery,  
Surgical Disciplines  
Mahatma Gandhi University of Medical  
Sciences & Technology  
Jaipur, Rajasthan, India  
[mcmisra@gmail.com](mailto:mcmisra@gmail.com)

### **Sumeet K. Mittal**

Norton Thoracic Institute, Dignity Health,  
Creighton University School of Medicine  
(Phoenix Campus)  
Phoenix, AZ, USA  
[SumeetMittal@creighton.edu](mailto:SumeetMittal@creighton.edu)

**Salvador Morales-Conde**

Unit of Innovation in Minimally Invasive Surgery, Department of General and Digestive Surgery  
University Hospital "Virgen del Rocío"  
Sevilla 41010, Spain  
[smoralesc@gmail.com](mailto:smoralesc@gmail.com)

**Ellen Morrow**

Department of Surgery  
University of Utah  
Salt Lake City, UT, USA  
[ellenmorrow@gmail.com](mailto:ellenmorrow@gmail.com)

**Philip C. Müller**

Department of General, Visceral and Transplantation Surgery  
University Hospital Heidelberg  
Heidelberg, Germany  
[philip.mueller@hotmail.com](mailto:philip.mueller@hotmail.com)

**Beat Müller-Stich**

Department of General Surgery  
Heidelberg University Hospital  
Heidelberg 69120, Germany  
[beat.mueller@med.uni-heidelberg.de](mailto:beat.mueller@med.uni-heidelberg.de)

**Henning Niebuhr**

Hernia Surgery  
Hanse-Hernienzentrum Hamburg  
Hamburg 21031, Germany  
[dr.niebuhr@t-online.de](mailto:dr.niebuhr@t-online.de)

**Jelmer E. Oor**

Department of Surgery  
St. Antonius Hospital  
Nieuwegein, The Netherlands  
[j.oor@antoniuziekenhuis.nl](mailto:j.oor@antoniuziekenhuis.nl)

**Rudolph Pointner**

Tauernklinikum GmbH  
Stefan-Zweig-Straße  
Zell am See, Austria  
[rudolph.pointner@tauernklinikum.at](mailto:rudolph.pointner@tauernklinikum.at)

**Bruce Ramshaw**

Department of Surgery  
University Surgeons Associates  
Knoxville, TN, USA  
[bruceramshawmd@gmail.com](mailto:bruceramshawmd@gmail.com)

**Wolfgang Reinpold**

Department of Surgery and Hernia Center  
Gross Sand Hospital, Teaching Hospital of the  
University of Hamburg  
Gross Sand 3D 21107, Hamburg, Germany  
[w.reinpold@gross-sand.de](mailto:w.reinpold@gross-sand.de)

**Hrishikesh P. Salgaonkar**

Minimally Invasive Surgical Centre, YLL School  
of Medicine, National University of Singapore  
Singapore 119074, Singapore  
[hrishikesh.salgaonkar@gmail.com](mailto:hrishikesh.salgaonkar@gmail.com)

**Rudolf Schrittwieser**

Department of Surgery  
LKH Hochsteiermark/Standort Bruck an der Mur  
Bruck an der Mur, Austria  
[rudolf.schrittwieser@kages.at](mailto:rudolf.schrittwieser@kages.at)

**Volker Schumpelick**

Department of Surgery  
University Hospital Aachen  
Aachen 52074, Germany  
[volker@schumpelick.de](mailto:volker@schumpelick.de)

**Jochen Schwarz**

Hernia Center Rottenburg  
Winghofer Medicum  
Rottenburg, Germany  
[j-g.schwarz@t-online.de](mailto:j-g.schwarz@t-online.de)

**Anil Sharma**

Max Institute of Minimal Access, Metabolic  
and Bariatric Surgery Max Healthcare  
Delhi, New Delhi 110017, India  
[asharma736@yahoo.in](mailto:asharma736@yahoo.in)

**Shreya Shetty**

Department of Surgery  
Creighton University Medical Center  
601 N 30th Street, Suite 3700  
Omaha, NE 68131, USA  
[ShreyaShetty@creighton.edu](mailto:ShreyaShetty@creighton.edu)

**Bernd Stechemesser**

Hernia Surgery  
Hernienzentrum Köln  
Köln, Germany  
[bernd.stechemesser@hernienzentrumkoeln.de](mailto:bernd.stechemesser@hernienzentrumkoeln.de)

**Baukje Van Den Heuvel**

Surgery, VUMC  
Amsterdam 1081 HV  
The Netherlands  
[baukjevdh@vumc.nl](mailto:baukjevdh@vumc.nl)

**G.H. van Ramshorst**

VU University Medical Center  
Amsterdam, The Netherlands  
[gvanramshorst@rkz.nl](mailto:gvanramshorst@rkz.nl)

**Burkhard H. A. von Rahden**

Klinik für Allgemein-, Viszeral-, Gefäß  
und Kinderchirurgie, Zentrum für operative  
Medizin (ZOM)  
Oberdürrbacherstraße 6  
97080, Würzburg, Germany  
[Rahden\\_B@chirurgie.uni-wuerzburg.de](mailto:Rahden_B@chirurgie.uni-wuerzburg.de)

**Dirk Weyhe**

Department of Visceral Surgery  
University of Oldenburg, School of Medicine  
and Health Sciences, Pius-Hospital, Medical  
Campus, Oldenburg, Germany  
[dirk.veyhe@pius-hospital.de](mailto:dirk.veyhe@pius-hospital.de)  
[d.veyhe@elis-stiftung.de](mailto:d.veyhe@elis-stiftung.de)

**Sujith Wijerathne**

Minimally Invasive Surgical Centre  
YLL School of Medicine, National University  
of Singapore, Singapore 119074, Singapore  
[sujithwijerathne@gmail.com](mailto:sujithwijerathne@gmail.com)

**Ralf M. Wilke**

District Hospital Calw-Nagold, Department of  
general, visceral and vascular surgery  
Nagold, Germany  
[R.Wilke@klinikverbund-suedwest.de](mailto:R.Wilke@klinikverbund-suedwest.de)

# Inguinal Hernia

## Contents

- Chapter 1**    **Clinical Anatomy of the Groin: Posterior Laparoscopic Approach – 5**  
*Reinhard Bittner, David Chen,  
and Wolfgang Reinpold*
- Chapter 2**    **Diagnostics of Inguinal Hernias – 21**  
*Baukje Van Den Heuvel*
- Chapter 3**    **Classification of Inguinal Hernia – 27**  
*Volker Schumpelick*
- Chapter 4**    **Chain of Events Leading to the Development of the Current Techniques of Laparoscopic Inguinal Hernia Repair: The Time Was Ripe – 31**  
*Maurice Arregui*
- Chapter 5**    **Indication for Surgery: Open or Laparoendoscopic Techniques in Groin Hernias – 37**  
*Jan F. Kukleta, Ferdinand Köckerling,  
and George Ferzli*
- Chapter 6**    **Patient Selection for Laparoendoscopic Inguinal Hernia Repair – 43**  
*Mazen Iskandar and George Ferzli*
- Chapter 7**    **Watchful Waiting as a Treatment Strategy in Patients with Asymptomatic Inguinal Hernia – 51**  
*Brian Biggerstaff, Shreya Shetty,  
and Robert J. Fitzgibbons, Jr.*



- Chapter 8**    **Perioperative Management of Laparoscopic Inguinal Hernia Repair – 59**  
*Henning Niebuhr, Bernd Stechemesser,  
and Reinhard Bittner*
- Chapter 9**    **Transabdominal Preperitoneal Patch Plasty (TAPP): Standard Technique and Specific Risks – 79**  
*Reinhard Bittner, Jan F. Kukleta, and David Chen*
- Chapter 10**   **TAPP: Complications, Prevention, Education, and Preferences – 101**  
*Reinhard Bittner, Jan F. Kukleta, and David Chen*
- Chapter 11**   **Technique Total Extraperitoneal Patch Plasty (TEP): Standard Technique and Specific Risks – 119**  
*Ferdinand Köckerling, Pradeep Chowbey,  
Davide Lomanto, and Maurice Arregui*
- Chapter 12**   **Technique Total Extraperitoneal Patch Plasty (TEP): Complications, Prevention, Education, and Preferences – 141**  
*Ferdinand Köckerling, Pradeep Chowbey,  
Davide Lomanto, and Maurice Arregui*
- Chapter 13**   **Comparison TAPP vs. TEP: Which Technique Is Better? – 151**  
*Virinder Kumar Bansal, Asuri Krishna,  
Nalinikant Ghosh, Reinhard Bittner,  
and Mahesh C. Misra*
- Chapter 14**   **Complex Inguinal Hernias – 171**  
*Mazen Iskandar and George Ferzli*
- Chapter 15**   **Mesh Technology at Inguinal Hernia Repair – 183**  
*Ferdinand Köckerling, Dirk Weyhe,  
Rene H. Fortelny, and Bruce Ramshaw*

- Chapter 16 Aftercare and Recovery in Laparoscopic Inguinal Hernia Surgery – 195**  
*Ralf M. Wilke, Andrew de Beaux,  
and Juliane Bingener-Casey*
- Chapter 17 Chronic Postoperative Inguinal Pain (CPIP) – 201**  
*Wolfgang Reinpold and David Chen*
- Chapter 18 Costs – 215**  
*G. H. van Ramshorst and Reinhard Bittner*
- Chapter 19 Sportsmen Hernia – 225**  
*Salvador Morales-Conde, Moshe Dudai,  
and Andreas Koch*
- Chapter 20 Comparison to Open Techniques – 235**  
*Baukje Van Den Heuvel, Robert J. Fitzgibbons, Jr.,  
and Reinhard Bittner*
- Chapter 21 Reduced Port in Laparoendoscopic Inguinal Hernia Repair – 243**  
*Davide Lomanto, Rajesh Khullar, Thomas Carus,  
and Sujith Wijerathne*



# Clinical Anatomy of the Groin: Posterior Laparoscopic Approach

*Reinhard Bittner, David Chen and Wolfgang Reinpold*

- 1.1 The First View to the Groin After Introducing the Laparoscope: Peritoneal Landmarks – 6**
- 1.2 Anatomic Structures of the Preperitoneal Space: View After Creation of the Peritoneal Flap in TAPP or Total Extraperitoneal (TEP) Dissection Plane – 8**
  - 1.2.1 Transversalis Fascia and Preperitoneal Space – 8
  - 1.2.2 Preperitoneal Space and the Vessels – 12
  - 1.2.3 Preperitoneal Space and Topographic Anatomy of the Nerves – 14
- 1.3 The Ileo-pubic Tract and the Muscular/Vascular Lacuna – 17**
- 1.4 Conclusion – 17**
- References – 18**

In-depth knowledge of groin anatomy is essential for a successful inguinal hernia operation. Sir Astley Paston Cooper postulated in 1804, “No disease of the human body, belonging to the province of the surgeon, requires in its treatment, a better combination of accurate, anatomical knowledge with surgical skill than hernia in all its varieties” [1]. While Bassini helped to elucidate the anatomy of the anterior inguinal canal in 1884 [2] ushering in the modern era of safe and effective hernia repair, understanding of the posterior canal remained limited. W.J. Lytle reported in 1945, “The operating surgeon knows little of the posterior wall of the inguinal canal, so well is it hidden from his view” [3]. In the early 1990s, laparoscopic approaches to the inguinal canal emerged. However, the posterior anatomy of the groin remained poorly understood and the laparoendoscopic view of this region was virtually unknown to most surgeons [4]. The adoption of this novel and exciting technique without a firm anatomic understanding resulted in several intra- and postoperative complications including vascular, visceral, and nerve injuries as well as high recurrence rates. Detailed study of the posterior anatomy, continuous technical refinements into well-standardized modern laparoscopic techniques, and unparalleled in vivo visualization of this region have transformed laparoscopic inguinal hernia repair into a safe, reproducible, and successful operation providing an ideal repair for all variants of groin hernias.

The basic anatomical principles of laparoscopic herniorrhaphy were first described by Spaw in 1991 based on human cadaveric dissections [4]. He coined the term “triangle of doom” delineating the region between the vas deferens and the spermatic vessels. In this triangle, the external iliac artery and vein are hidden under the peritoneum and transversalis fascia, and major vascular injury is possible with improper dissection. In his description, Spaw did not specifically consider the neuroanatomy of the preperitoneal space [4]. He described that “suturing or stapling of synthetic materials should be performed lateral to the spermatic vessels along the abdominal wall” leading to serious neuropathic consequences for many patients. Rossner was the first to describe the inguinal neuroanatomy as it pertains to posterior inguinal hernia repair in 1994 roughly delineating the anatomical course of the inguinal nerves [5]. Seid and Amos provided a more pre-

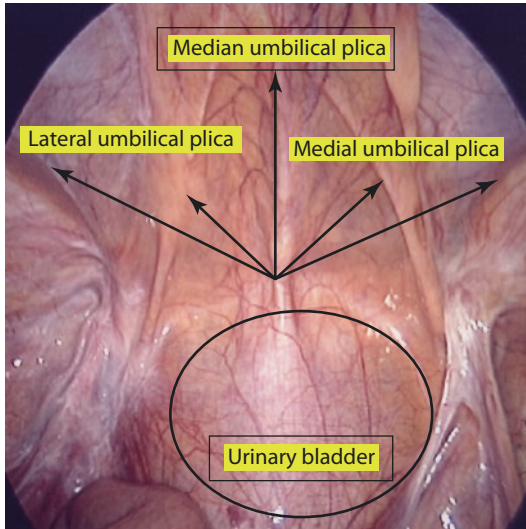
cise description of the nerves [6] postulating that the “triangle of doom” should be extended further laterally to the anterior superior iliac spine. The authors introduced the term “trapezoid of disaster” describing that in addition to potential injury to the major vessels within the triangle of doom, nerves (n. femoralis, n. genitofemoralis, n. cutaneous femoris lateralis, n. ilioinguinalis, and n. iliohypogastricus) located lateral to the testicular vessels within the “triangle of pain” were also at risk [7, 8]. The most comprehensive analysis of the posterior inguinal anatomy was given by Annibali [7, 8] including the fascial structures, vessels, and nerves. Recently very detailed descriptions of the course of the nerves and their variations have been published by Rosenberger [9], Loeweneck [10], and Reinpold [11] adding to our understanding of this anatomy.

The aim of the following chapter on groin anatomy is to translate this detailed knowledge of cadaveric anatomy and extensive clinical experience into relevant surgical anatomy that will optimize operative technique and outcomes of inguinal hernia repair:

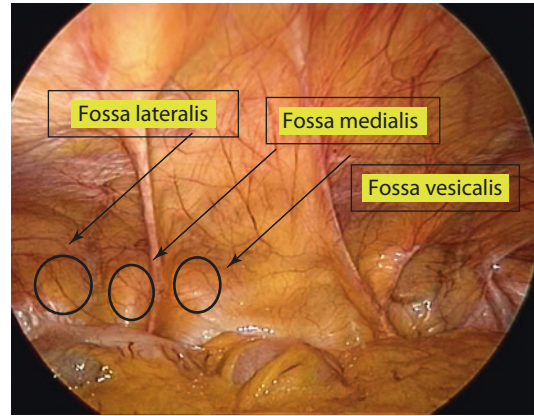
## 1.1 The First View to the Groin After Introducing the Laparoscope: Peritoneal Landmarks

The initial laparoscopic view of the groin will identify five peritoneal folds (plicae) (■ Fig. 1.1) which serve as guiding landmarks when opening the peritoneum. The plica umbilicalis mediana (median umbilical ligament) found in the midline contains the obliterated urachus. It is less distinct but fortunately less clinically relevant to inguinal hernia repair. The medial umbilical plica (medial umbilical ligament) is the most prominent landmark seen on initial transabdominal inspection. This plica is easily recognized and contains the remnant umbilical vessels. The medial umbilical plica should not be routinely cut because the umbilical vessels may still be patent causing bleeding. If extension of the peritoneal incision is necessary, the cut should be continued cranially and parallel to the plica avoiding this problem.

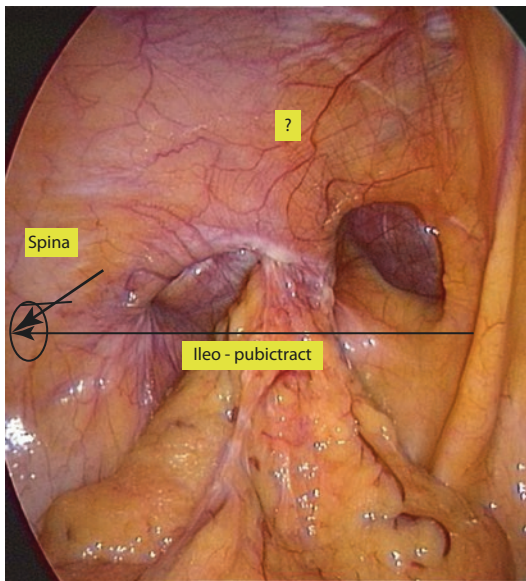
The lateral umbilical ligament may be difficult to identify from this view, but its recognition is the most important of the plicae. This ligament contains the inferior epigastric vessels which divide



■ Fig. 1.1 Five peritoneal folds (plica)



■ Fig. 1.3 Three flat fossae

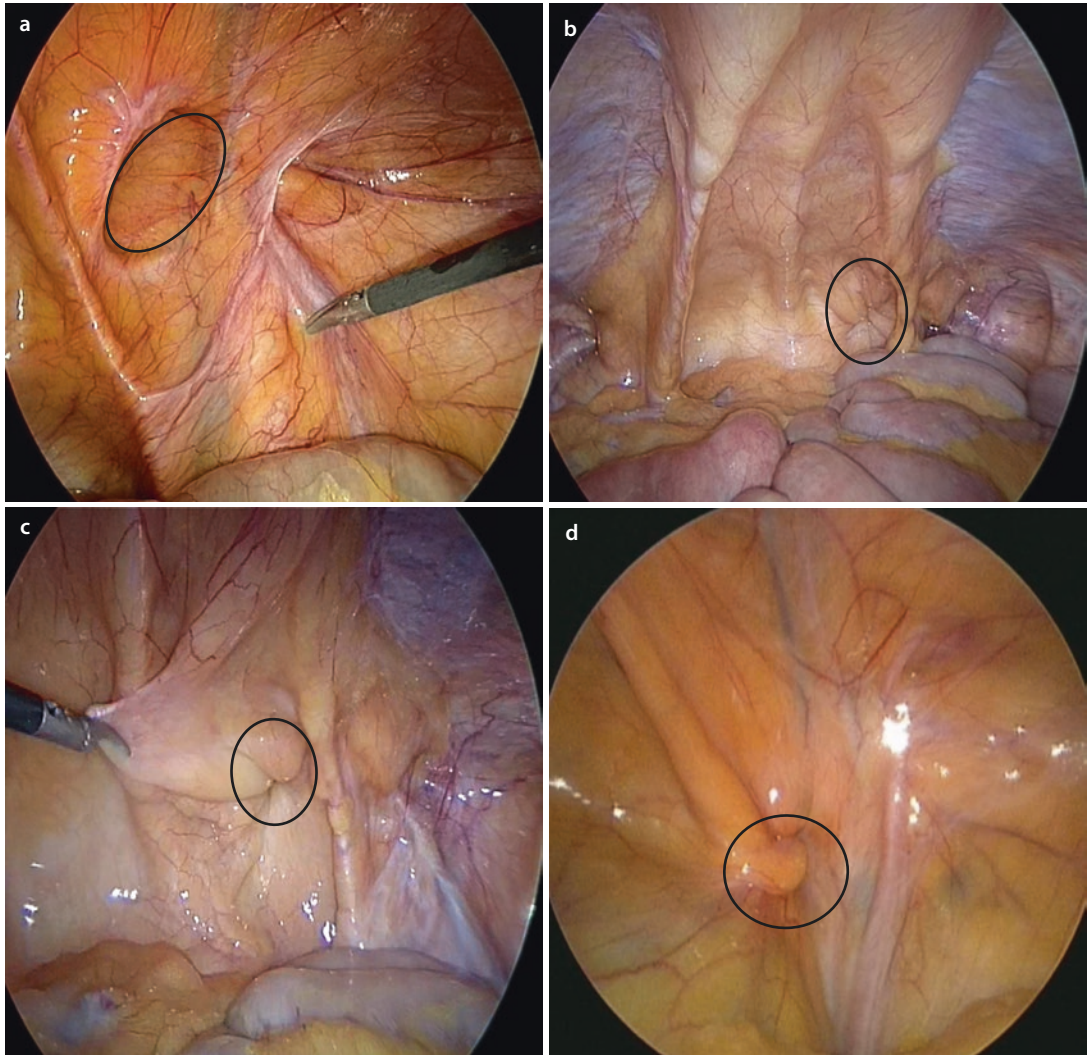


■ Fig. 1.2 Recurrent hernia. Lateral plica is difficult to identify (?)

the groin in a medial (space of Retzius) and a lateral (space of Bogros) compartment. Depending on the patient's body habitus and fat distribution, the lateral ligament may not be readily visualized laparoscopically (■ Fig. 1.2). However, the epigastric vessels should always be preserved, and careful assessment of the anatomy prior to dissection of the peritoneal flap is an essential operative step. External palpation of the surface anatomy allows for precise localization of the anterior superior

iliac spine and pubic tubercle, thereby delineating the ileo-pubic tract that divides the groin into an upper and a most critical lower part (■ Fig. 1.2). The ileo-pubic tract which corresponds to the inguinal ligament seen in open surgery is therefore one of the most important landmarks and should always be identified. The inferior epigastric vessels are found approximately at the midpoint of the tract, and careful dissection in this region will prevent injury.

In addition to the five plicae, three flat fossae are recognizable on each side, corresponding with possible hernia defects (■ Fig. 1.3). The lateral fossa, located in the triangle between the lateral umbilical ligament and the ileo-pubic tract, corresponds to the location of the internal ring from which a lateral (indirect) inguinal hernia originates. The medial fossa is located between the lateral and the medial umbilical ligament and is inferiorly limited by the ileo-pubic tract (■ Fig. 1.4a). A direct hernia will be found in this region passing through Hesselbach's triangle. The third fossa (vesicalis) is located medial to the medial umbilical ligament and cranial to the ileo-pubic tract, pubic bone, and urinary bladder. Rare defects in this point of weakness may be the origin of a so-called supravesical hernia (■ Fig. 1.4b, c). A fourth location where a hernia may develop is within the region of the femoral canal, the triangle below the ileo-pubic tract, medial to the femoral vein and superior to the pubic bone and Cooper's ligament. A hernia present in this region can be more easily diagnosed by laparoscopy (■ Fig. 1.4d) compared to the totally extraperitoneal technique or open surgery.



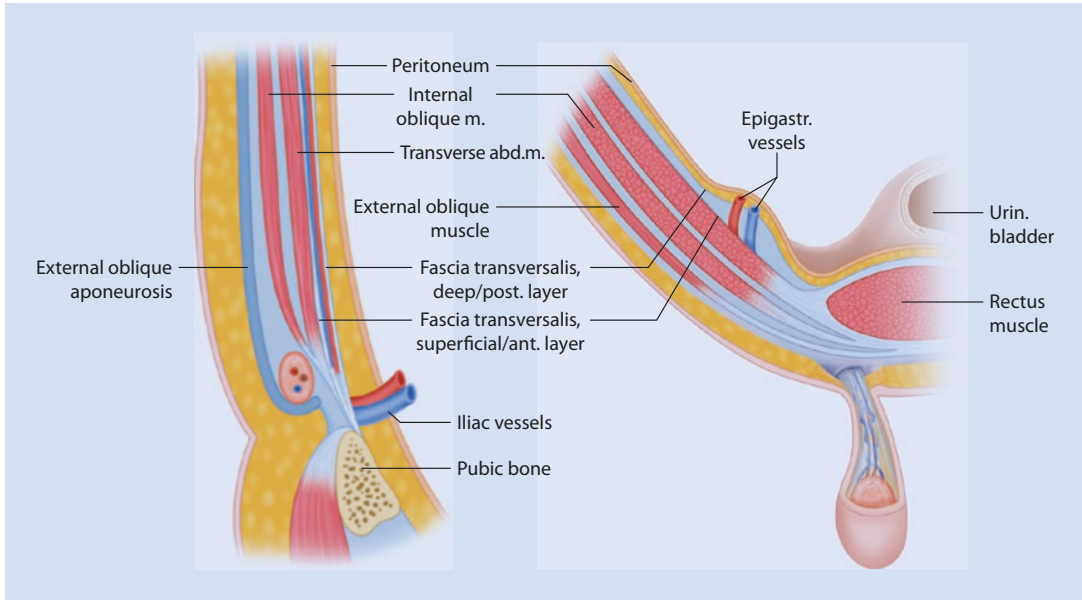
**Fig. 1.4** Hernia localizations. **a** Medial and lateral hernia. **b** Supravescical hernia. **c** Supravescical hernia, partially reduced. **d** Femoral hernia

## 1.2 Anatomic Structures of the Preperitoneal Space: View After Creation of the Peritoneal Flap in TAPP or Total Extraperitoneal (TEP) Dissection Plane

### 1.2.1 Transversalis Fascia and Preperitoneal Space

Initial laparoscopic inguinal repairs utilized intraperitoneal only mesh (IPOM) techniques to cover inguinal hernia defects. This led to high recurrence rates and complications because of the

inability to safely and securely fixate the mesh in this location rendering it “a boat in a rough sea.” To address this limitation, mesh was placed within the preperitoneal space in direct apposition to the muscular, tendinous, and bony structures of the posterior abdominal wall and pelvis. The preperitoneal space lies between the peritoneum internally and the transversalis fascia externally. Within the preperitoneal space is a variable quantity of adipose tissue, loose areolar connective tissue, and membranous tissue [12]. The transversalis fascia is perhaps the most important fascial structure in the groin as it is involved in both the development of a hernia as well as its treatment.

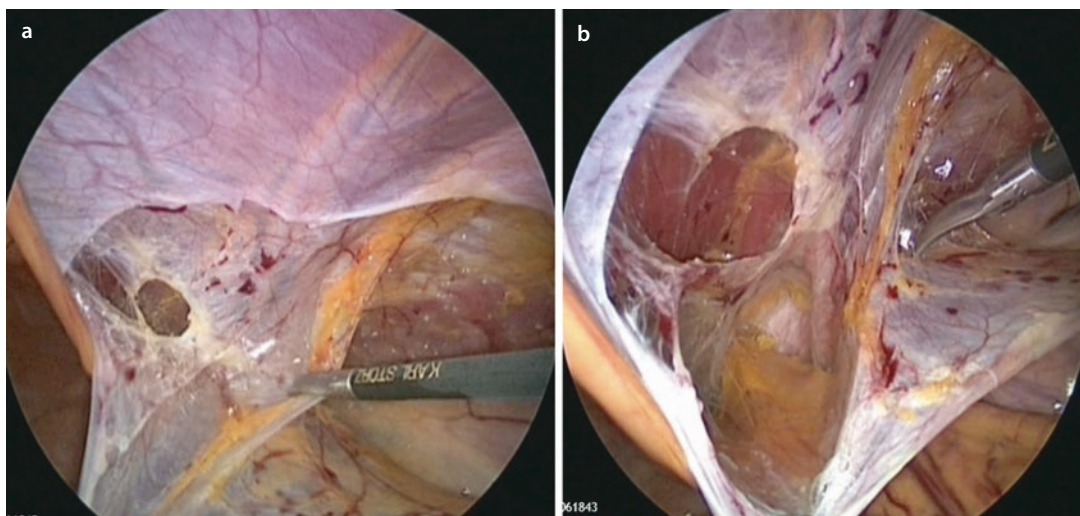


■ **Fig. 1.5** a, b Schematic representation of the planes of the abdominal wall in the inguinal region (Modified according Colborn and Skandalakis [15])

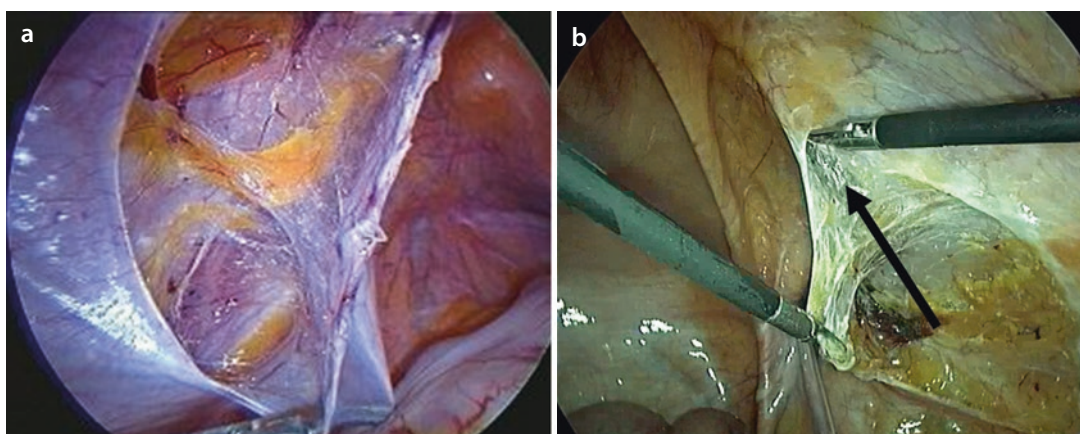
Cooper originally described the transversalis fascia as a bilaminar structure with a strong anterior layer and a membranous deep layer [1] with the epigastric vessels lying between. However, the question whether the transversalis fascia is bilaminar or whether the “deep/posterior lamina” is simply a significant regional condensation of extraperitoneal connective tissue (“extraperitoneal fascia”) [13, 14] is still unresolved [15]. Both structures appear strong and difficult to break through especially in the young patient with an indirect hernia. The deep membranous layer (extraperitoneal fascia) divides the preperitoneal space into a visceral and a parietal compartment. Mirilas and Skandalakis [16] describe this membranous septum as creating a second internal ring and separating the planes (■ Fig. 1.5a, b).

The parietal compartment contains the epigastric vessels and numerous small tributaries and may be associated with troublesome bleeding during dissection. The genitofemoral and lateral femoral cutaneous nerves also travel within this compartment, and over-dissection resulting in “naked” nerves should be avoided to prevent perineural scarring and direct contact with mesh. The visceral compartment is avascular and dissection should proceed in this plane. Understanding this anatomic distinction will greatly facilitate proper dissection, ease of developing the correct preperi-

toneal plane, and help to prevent vascular, nerve, and mesh complications [17]. Despite numerous cadaveric studies, the nature of the transversalis fascia is still a source of controversy for surgeons and anatomists [17, 18]. According to our clinical experience with more than 16,000 laparoscopic hernia repairs, two reasons may be responsible for the continuing uncertainties: (1) There is great individual variability in its topographic occurrence and strength, and (2) whereas medial to the epigastric vessels the bilaminar structure is recognizable in most patients (■ Fig. 1.6a, b), medially, its identification may be difficult. In some patients, especially with obesity, adipose tissue and small vessels may occupy the preperitoneal space making it difficult to clearly delineate the compartments medially. Lateral to the epigastric vessels, the deep layer is less discrete and closely related to the anterior lamina. In contrast to the medial compartment, the dissection plane is immediately in front of the deep lamina. Therefore, because it is easier to find and separate the correct plane in this region, it is recommended to start with the dissection of the groin at the lateral aspect at the level of the anterior superior iliac spine (■ Fig. 1.7a, b). After making a generous peritoneal incision, most of the preperitoneal dissection can be safely and efficiently performed by bluntly sweeping away the peritoneum and fatty tissue from the



**Fig. 1.6** a Superficial and deep layer of transversalis fascia medially. b Superficial layer of transversalis fascia after breaking through the deep layer



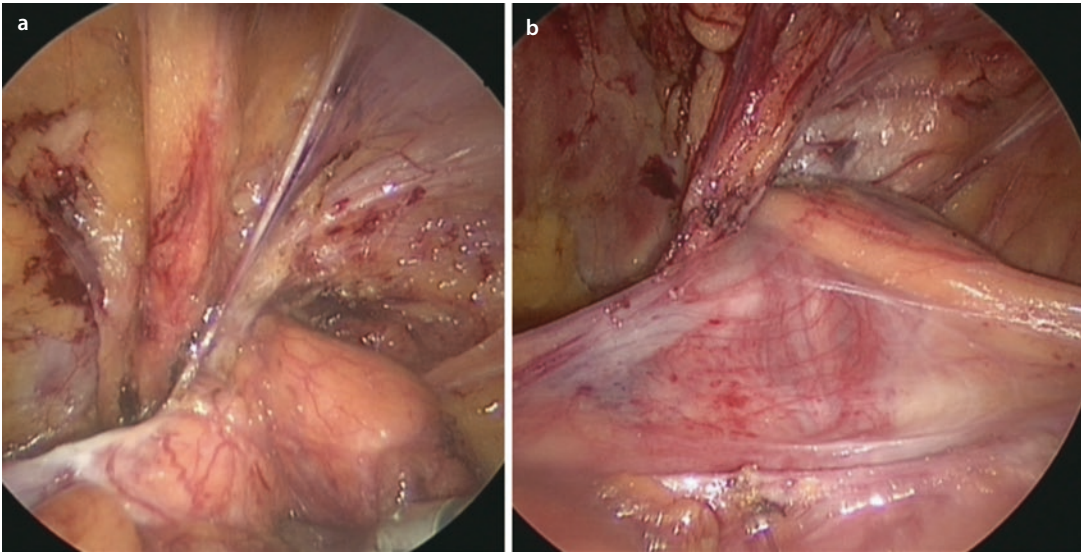
**Fig. 1.7** a Deep layer of the transversalis fascia. b Access to the visceral laterally compartment from lateral-caudal. The deep layer of the transversalis fascia is protected

abdominal wall covered by the transversalis fascia. However, when crossing the epigastric vessels in order to dissect the medial compartment, it is necessary to break through the deep layer to approach the rectus muscle and the symphysis.

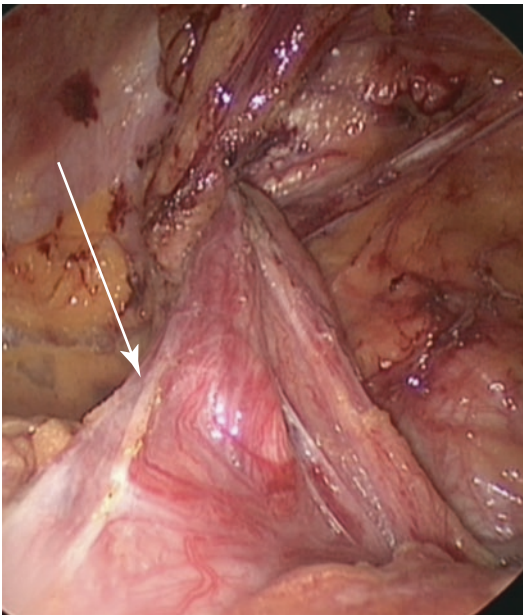
Medially, both laminae of the transversalis fascia insert inferiorly on the ligament of Cooper. Laterally, its course is less clear. Around the internal inguinal ring, the deep fibers may envelop the cord structures and contribute at least partially to the spermatic sheath as extensively described by Stoppa [19]. The morphology of the spermatic sheath is triangular with an anterior apex at the deep aspect of the inner inguinal orifice and a

posterior medial base. The vas deferens makes up its medial border while the spermatic vessels delineate the lateral border. The base of the sheath disappears beneath the retracted peritoneal sac when parietalization is performed [19]. Additionally, the spermatic sheath covers the external iliac vessels which reside just deep to the triangle. Although the origin of this sheath is not clearly defined – prolongation of the urogenital fascia as Stoppa [19] suggested or a continuation of the deep layer of the transversalis fascia – for the surgeon it is of essential importance to recognize this sheath and not to violate it when dissecting the pelvic floor, except at the level of the internal





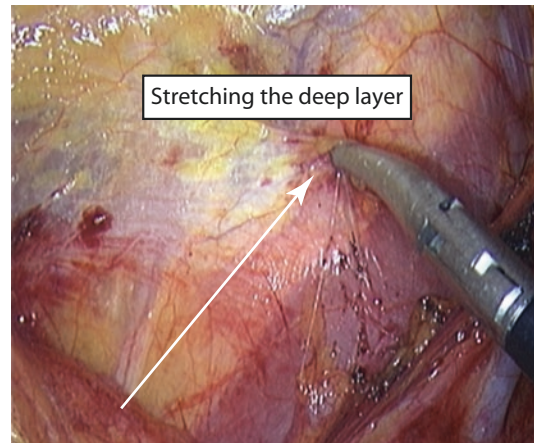
**Fig. 1.8** **a** Transition of the deep layer of the transversalis fascia into the spermatic sheath (Stoppa). **b** The spermatic sheath is wrapping the cord structures



**Fig. 1.9** The spermatic sheath is cut anteriorly to parietalize the hernia/peritoneal sac

inguinal ring anteriorly (Fig. 1.8a, b). With an indirect hernia, the sheath is opened at the ring to identify and reduce the hernia sac as well as when parietalizing the cord structures (Fig. 1.9).

According to Stoppa et al. [19], the sheath (deep layer of the transversalis fascia) joins the lateral wall of the iliac fossa and may be a part of the iliac fascia which covers the inguinal nerves.



**Fig. 1.10** The deep layer (extraperitoneal fascia) continues laterally into the iliac fascia which protects the nerve lying behind

In summary, the spermatic sheath (deep layer of the transversalis fascia) should be preserved during separation from the hernia/peritoneal sac (parietalization) because it protects the external iliac vessels and the nerves that are lying beneath (Fig. 1.10). The surgeon must preserve this important fascial layer for two reasons: (1) to avoid an injury to the vessels or the nerves during dissection and (2) to avoid direct contact between the nerves and mesh which may produce pain in the later postoperative period due to perineural scarring. For the same reason, implantation of a slitted mesh cannot be recommended as the integ-

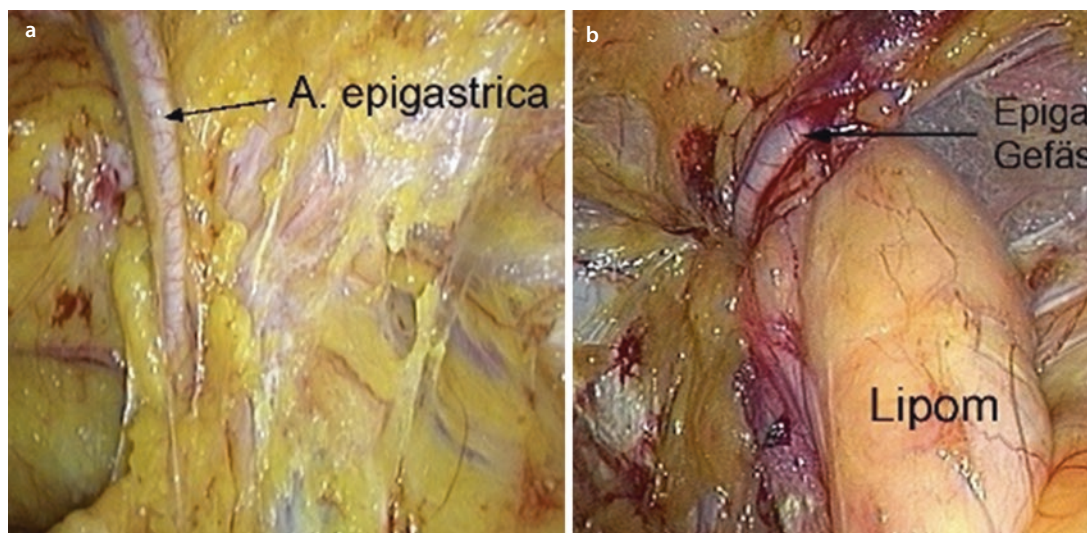
rity of the fascia will be destroyed and the nerves, spermatic vessels, and vas are all placed at risk.

## 1.2.2 Preperitoneal Space and the Vessels

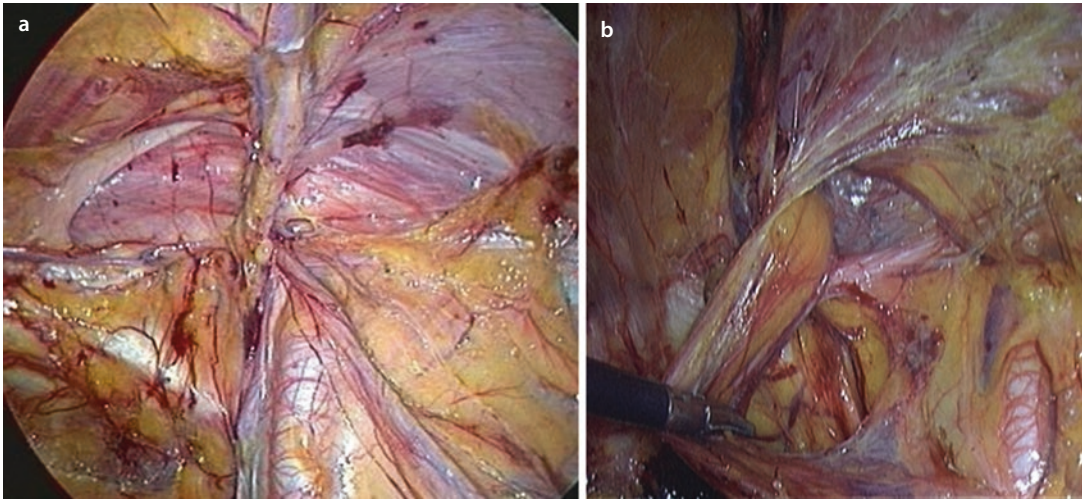
The location and the course of the vessels remain fairly constant with a few common variations, and identification is typically straightforward. The inferior epigastric vessels are perhaps the most important landmark in the myopectineal orifice and are easily recognized even in obese patients (see above). It is important to recognize that in case a large hernia sac or a lipoma is present, the vessels may be dislocated medially (■ Fig. 1.11a, b). The epigastric vessels divide the myopectineal orifice into a medial and a lateral compartment. The proper dissection plane should be just in front of these vessels (from the posterior laparoscopic approach). When performing a TEP repair, creation of the preperitoneal space relies on this same dissection plane. With a dissecting balloon, the epigastric vessels should be above the plane of dissection before inflation and preserved against the abdominal muscles. With camera and manual dissection of this space, the areolar plane posterior to the epigastric vessels is developed separating the epigastric vessels from the peritoneum. The epigastric vessels originate from the external iliac vessels and may be surrounded by fatty tissue as well

as lymph nodes. This tissue must be respected and not removed when dissecting the groin. The same consideration applies to the iliac vessels which are protected by the spermatic sheath. The iliac artery, located at the bottom of the pelvis and in the middle of the preperitoneal space, may be identified by following the epigastrics downward toward their origin (■ Fig. 1.12a, b). The iliac vessels may be accompanied by fatty tissue and lymph nodes and over-dissection may lead to bleeding, potential nerve injury, or lymphatic leakage. Preservation of the spermatic sheath will avoid these issues. The iliac vein is located posterior and slightly medial to the artery. It may be visualized during dissection of the groove in the triangle between the lower branch of the pubic bone, the iliac vessels, and the wall of the urinary bladder (■ Fig. 1.13).

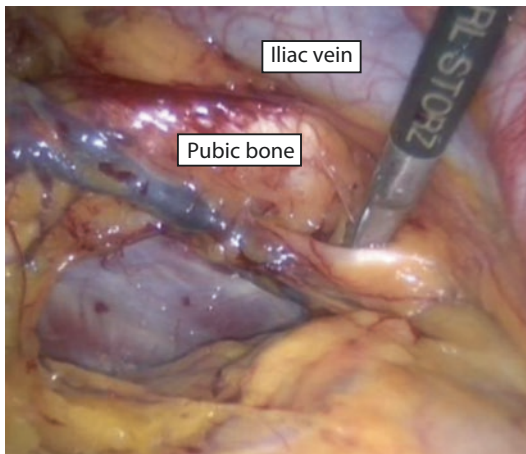
Dissection of this region should be performed with special caution looking for the presence of a corona mortis, a vascular connection between the epigastric and obturator vessels. This variant, found in 20–30% of patients, is important because intraoperative bleeding from disruption can be difficult to control due to the dual vascular supply from the obturator and iliac vessels (corona mortis, ■ Fig. 1.14). In case of bleeding from the corona mortis, control must be achieved from both sources of inflow. In this region, there may be several variants of anastomosing vascular branches between the pubic artery/vein and the epigastric and obturator vessels. These small vas-



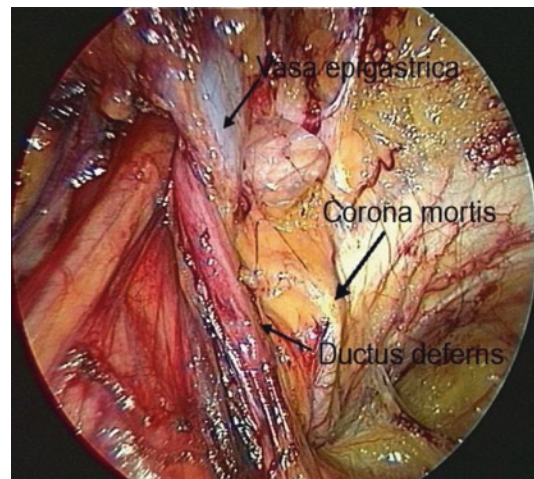
■ Fig. 1.11 a The epigastric vessels just after reduction of the peritoneum with the deep layer of transversalis fascia. b Epigastric vessels dislocated medially by a large lipoma



■ Fig. 1.12 a Pelvic floor after complete dissection. A. iliaca is visible directly in the middle. b A. iliaca dislocated laterally



■ Fig. 1.13 Dissection of the “groove,” exposing the obturator nerve and the iliac vein



■ Fig. 1.14 Corona mortis

cular tributaries may form a network investing the pubic bone, Cooper’s ligament, and the direct and femoral spaces (■ Fig. 1.15). From our clinical experience, these vessels and the underlying pubic bone are covered by a very thin membrane (deep layer of the transversalis fascia) which should not be disrupted.

The correct plane of dissection will preserve this membranous layer, and blunt dissection may be used to push away the urinary bladder developing the retropubic space for mesh placement. In special cases, e.g., recurrence after previous preperitoneal mesh repair, it may be necessary to continue the dissection downward to the urogenital space toward the origin of the remnant umbilical artery from the internal iliac artery (■ Fig. 1.16a, b). The vas

traverses directly over the artery (■ Fig. 1.16a), and care should be taken when dissecting this region. The surgeon should be aware that the umbilical artery may be patent and, in the case of injury, bleeding may be profuse and difficult to control.

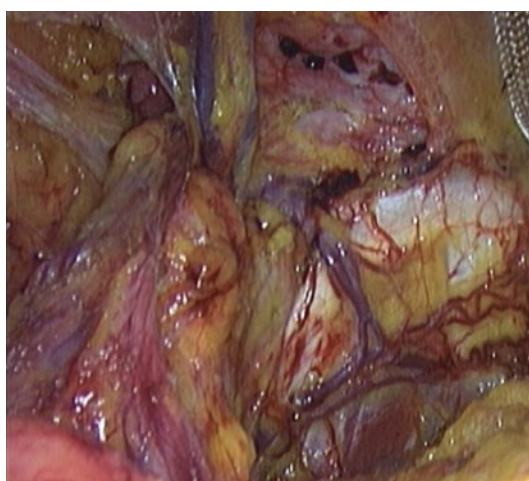The testicular vessels are easily identifiable but can be most clearly defined at their caudal aspect between the external iliac vessels and the psoas muscle and course from caudal-lateral to cranial-medial. There are no significant vascular structures lateral to the testicular vessels. The testicular vessels meet the vas deferens at the apex of the triangle immediately at the entrance to internal ring. The vas deferens travels downward crossing the iliac vessels medially, following the “preperitoneal loop” (deep layer of the transversalis fascia [20]), but then

changes its direction like a knee and dives down to the urogenital space to join the prostate gland. In order to complete the parietalization, it is important to cut this “preperitoneal loop” (■ Fig. 1.17)

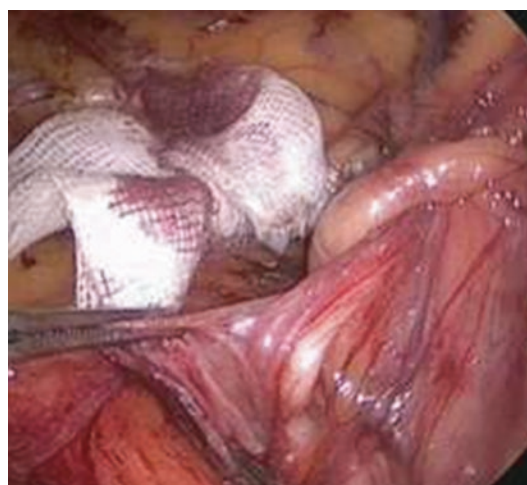
### 1.2.3 Preperitoneal Space and Topographic Anatomy of the Nerves

The anatomy of the nerves located in the groin is extensively described by Rossner [5], Seid and Amos [6], Annibali et al. [7, 8], Rosenberger et al. [9], Loeweneck et al. [10], and recently by Reinpold et al. [11]. In total, six nerves are of

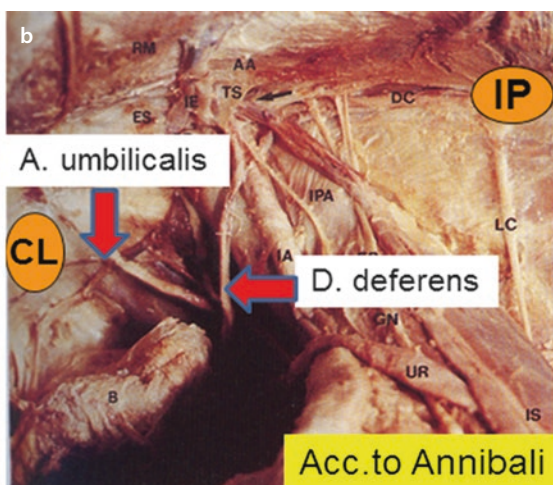
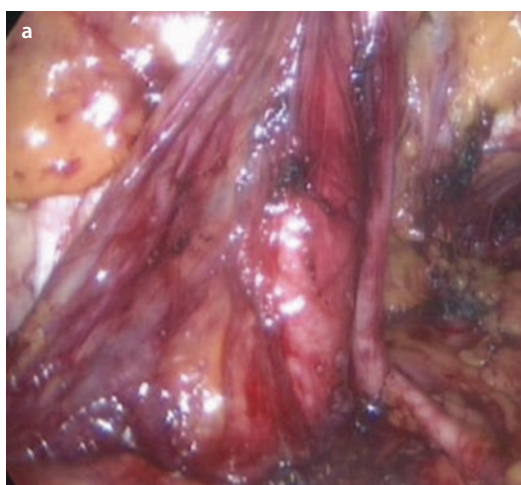interest in laparoscopic inguinal hernia repair and this neuroanatomy should be well understood by all surgeons. Anatomically, the n. hypogastricus and the n. ilioinguinalis are not involved in the dissection and repair planes utilized by laparoscopic hernia repair. These nerves have typically exited the retroperitoneum and entered into the anterior abdominal wall and inguinal canal lateral and superior to the anterior superior iliac spine. However, as a rule to the lumbar plexus neuroanatomy, there is tremendous anatomic variability especially progressing distally along the branches away from the spinal origin. In about 32% of cases, the course of the ilioinguinal nerve may be within the operating field and may be at risk dur-



■ Fig. 1.15 Network of pubic veins, protected by the deep layer of the transversalis fascia



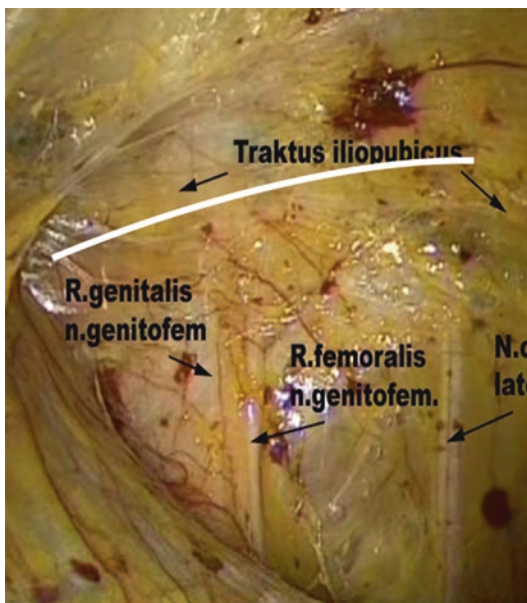
■ Fig. 1.17 The vas is riding on the preperitoneal loop which must be cut for complete parietalization [20]



■ Fig. 1.16 a Remnant A. umbilicalis in situ, coming out of the internal iliac artery. b A. umbilicalis in cadaveric dissection

ing the placement of staples in the neighborhood of the anterior superior iliac spine (Rosenberger).

The femoral nerve, which arises from the dorsal branches of the ventral rami of the second, third, and fourth lumbar nerves, is located just lateral to the iliac vessels and lateral and beneath the testicular vessels. This is usually well protected by the psoas tendon, surrounding fatty and lymphatic tissue, and spermatic sheath or iliac fascia. Therefore, injury to this nerve is extremely rare during laparoscopic hernia repair. According to Loeweneck, damage of this nerve was seen in only 1.2% of all nerve injuries reported. Reported injury to the obturator nerve is rare and anecdotal as it shares the same origin as the femoral nerve and is well hidden deep in the triangle between the pubic bone and the iliac vessels (■ Fig. 1.13) behind the vessels. The more common nerve injuries seen with laparoscopic inguinal repairs are lesions of the genitofemoral nerve and lateral femoral cutaneous nerve (■ Fig. 1.18). However, in total in large series, the frequency of damage to these nerves is not higher than 0.3% [21, 22]. Nevertheless, each of these complications should be taken seriously, as it can have disastrous consequences for the patient. Intractable pain may arise when nerves are injured, clipped, tacked, or scarred to mesh. Therefore, precise knowledge of the topography of these nerves is essential to perform a high quality

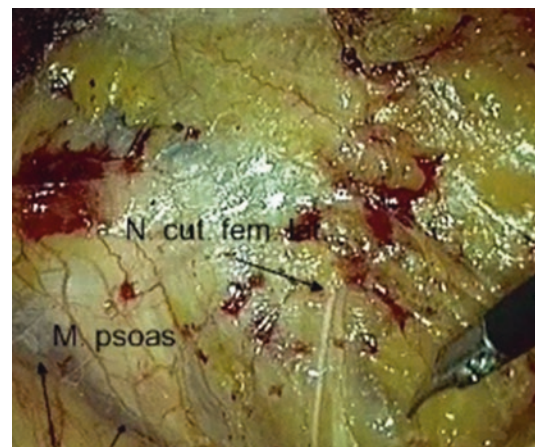


■ Fig. 1.18 Triangle of pain. The nerves are protected by the deep layer of transversalis fascia

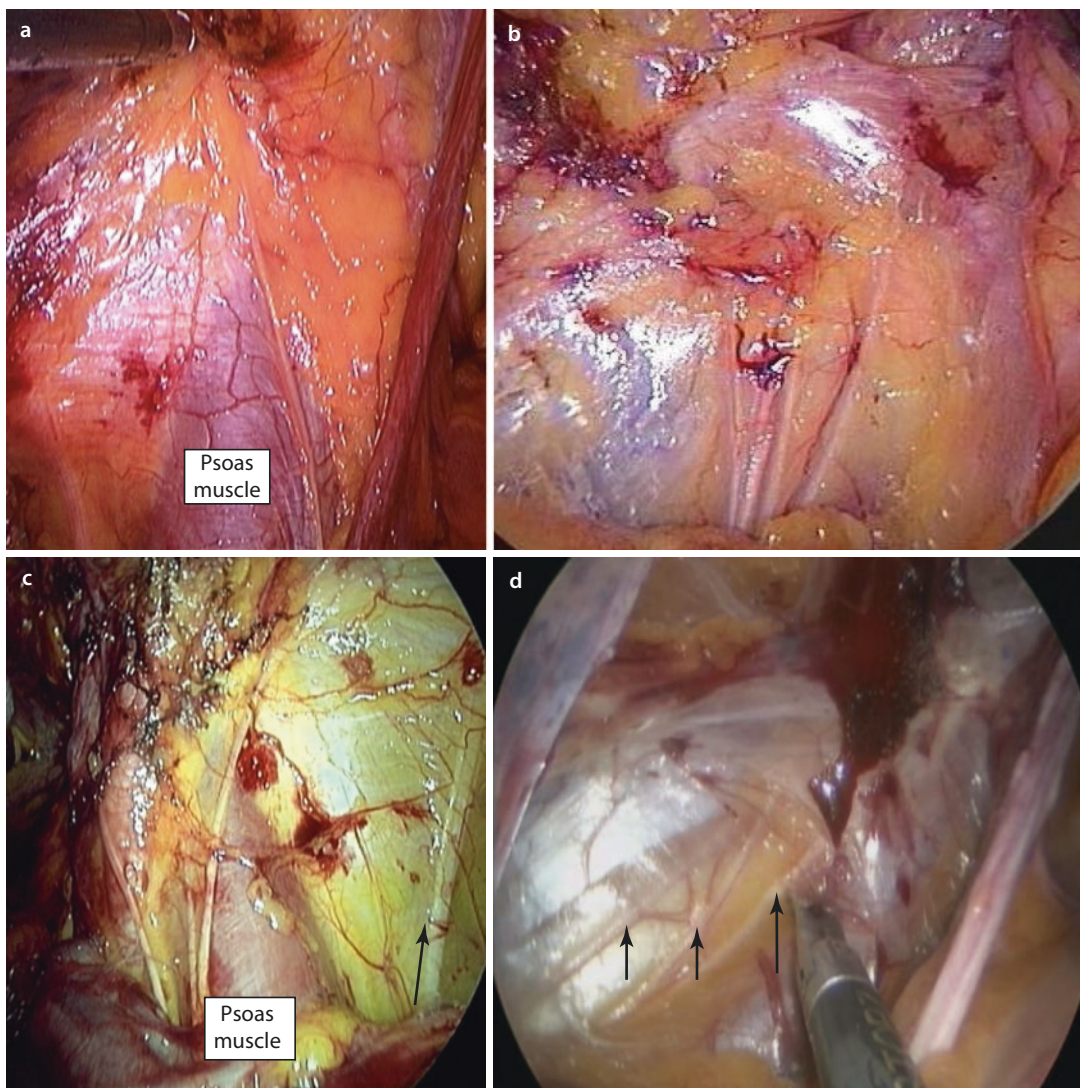
repair with optimal patient outcomes. While the course of the obturator and femoral motor nerves is largely predictable and constant, the course of the sensory nerves (genitofemoral and lateral femoral cutaneous) demonstrates great variability.

Most at risk during laparoscopic hernia repair are the lateral femoral cutaneous nerve (58.2% of all nerve lesions) and the femoral branch of the genitofemoral nerve (31.2% of all nerve lesions). Injury to the genital branch of the genitofemoral nerve comprises 4.7% of all published nerve lesions. The lateral femoral cutaneous nerve arises from the dorsal divisions of the second and third lumbar nerves. It emerges from the lateral border of the mid-psoas muscle and crosses the iliacus muscle obliquely traveling toward the anterior superior iliac spine. It then passes under the inguinal ligament, through the lacuna musculorum and then over the sartorius muscle into the thigh, where it divides into an anterior and a posterior branch. The anterior branch becomes superficial about 10 cm below the inguinal ligament and divides into branches which are distributed to the skin of the anterior and lateral parts of the thigh reaching as far as the knee.

The posterior branch supplies the skin from the level of the greater trochanter to the middle of the thigh. Intraoperatively, the surgeon should be aware that the lateral femoral cutaneous nerve will typically cross the middle of the operating field, but the majority (57%) demonstrates variability from the normal course. Single (44%), double (23%), or multiple nerve trunks may be identified (■ Fig. 1.19). The point of exit where the nerve penetrates the abdominal wall is typically lateral to the



■ Fig. 1.19 Two branches of the cutaneous lateral femoral nerve



**Fig. 1.20** **a** Only one branch of the genitofemoral nerve is visible. **b** Four branches of the genitofemoral nerve are visible protected by the deep layer of transversalis fascia. **c** Three branches of the genitofemoral nerve are visible. Laterally the n. cut. fem. lat. is visible (arrow). **d** Three branches of the genitofemoral nerve are visible

salis fascia. **c** Three branches of the genitofemoral nerve are visible. Laterally the n. cut. fem. lat. is visible (arrow). **d** Three branches of the genitofemoral nerve are visible

field 2–4 cm medial to the anterior superior iliac spine at the level of the ileo-pubic tract. However, this exit point also demonstrates significant variability and may be found up to 6 cm medially (only 3 cm lateral to the inner inguinal ring) and in 7% of the cases may even exit lateral and cranial to the anterior superior iliac spine [9]. The genitofemoral nerve arises from the upper L1–2 segments of the lumbar plexus. It passes downward and emerges from the anterior surface of the psoas major muscle. The nerve continues on the surface of the psoas muscle progressing caudally toward the inguinal

canal and divides into two branches, the genital branch and the femoral branch (Fig. 1.18).

In men, the genital branch continues down and supplies the scrotal skin. In women it accompanies the round ligament and supplies the mons pubis and the labia majora. Wide variation in the course of this nerve are seen. In contrast to classically described anatomy, the genital branch runs through the inguinal canal in only 14% of cases. In 44% of cases, it consists of two to five branches (Fig. 1.20a–d); in 49% of the cases, the nerve perforates the abdominal wall 1–3 cm lateral to